The Good, The Bad, and the Ugly- Identifying Benign and Malignant Neoplasms

Margaret McKernan MPAS, PA-C

Apex Skin and Surgery Center

Cleveland, OH



Learning Objectives

- Identify suspicious lesions that require further evaluation
  - Recognize common benign neoplasms
  - Recognize melanoma, moles, and its mimickers
- Distinguish conditions that warrant referral from those that require reassurance only
- Describe treatment modalities for skin cancers

Common Benign Neoplasms

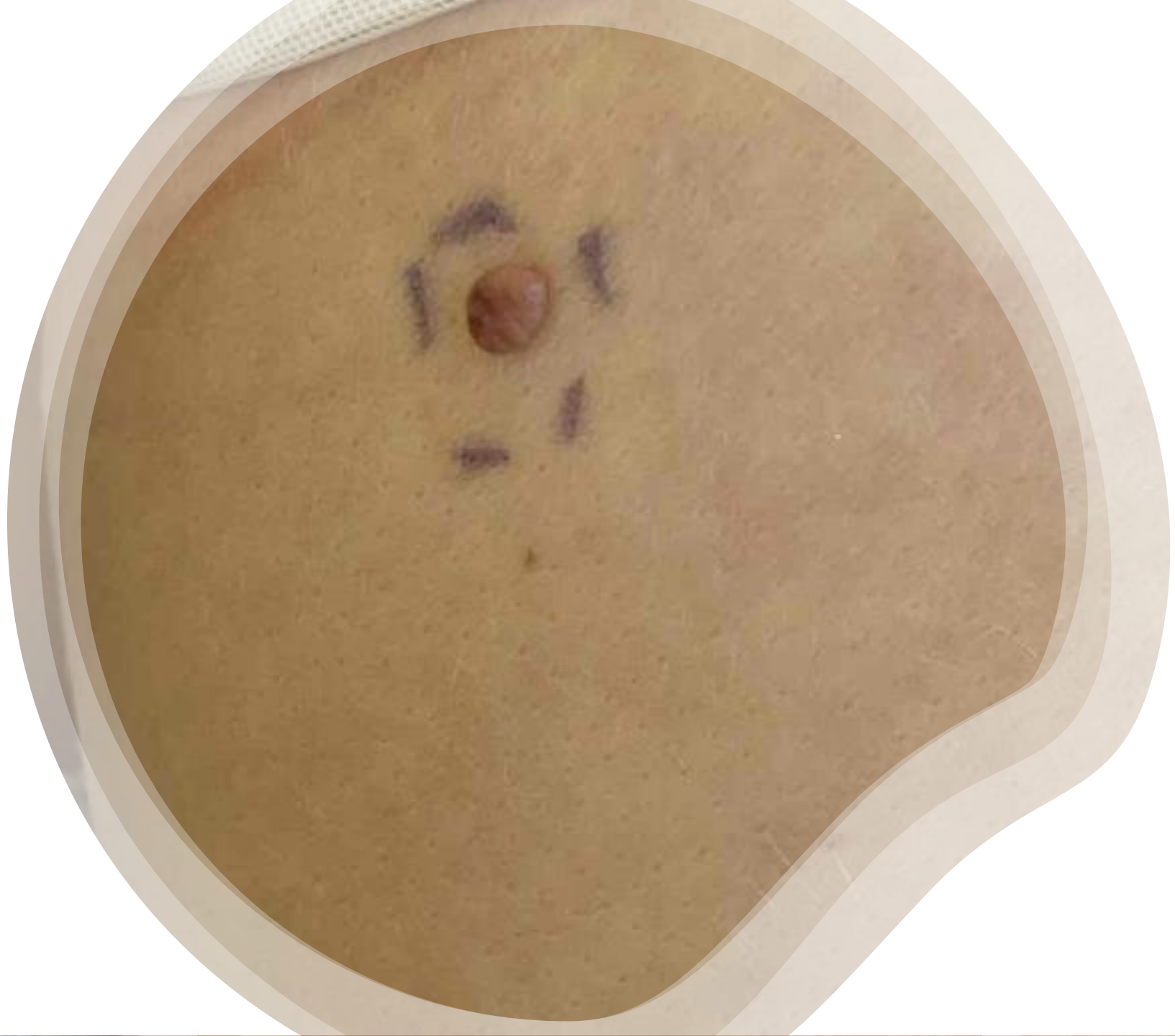

Acquired Melanocytic Nevi

- Clinical Findings: Small (<1 cm), circumscribed, acquired pigmented macules, papules, or nodules composed of groups of melanocytic nevus cells located in the epidermis, dermis, and rarely, subcutis
- Result from the proliferation of melanocytes
- Most nevi form later in life, mainly between the first and second decades of life
- Thought to peak during third decade of life due to reduced formation of new nevi and clinical regression of some nevi
- Diagnosis: clinical
- Treatment: If benign appearing-reassurance and clinical monitoring

Categories of Melanocytic Nevi

	Junctional	Compound	Intradermal
Typical color	Dark brown to black	Brown	Skin-colored, pink, or light brown
Topography	Macule	Slightly elevated often dome-shaped papule	Elevated, soft, often dome-shaped papule
Melanocyte location	Epidermis only	Epidermal and dermal component	Dermis only





Various Nevi Types

Other Nevi Types

	Blue Nevus	Halo Nevus	Spitz Nevus
Description	Solitary, blue to blue-black dome-shaped papules <1 cm	Melanocytic nevus surrounded by round or oval, usually symmetric, halo of depigmentation	Symmetric, well-circumscribed <1 cm in diameter, uniformly pink, tan, red, or red-brown smooth and dome shaped
Most Common Location	Head, neck, dorsal hands, feet, or sacral region	back	Face and lower extremities
Time to Eruption	Can be congenital or acquired most often during adolescence	Most often acquired during childhood/adolescence	Childhood or young adulthood



Seborrheic Keratoses

- One of the most common benign epithelial tumors
- Clinical findings: Begin as small 1-3 mm barely elevated papule or plaque with or without pigment
  - Later becomes plaque with warty or “stuck-on” appearance of the surface
- Round, oval, scattered, discrete, brown/black/gray
- Hereditary, increase with age
- Sign of *Leser-Trélat:* sudden appearance of numerous SKs, sign of internal malignancy
- Diagnosis: clinical, shave biopsy if concerning features
- Treatment: unnecessary-reassure
  - Cryosurgery, Electrocautery, rubbed off, and base cauterized, or curettage after cryosurgery, shave removal





Cherry Angiomas

- Most common vascular anomaly
- Clinical findings: Round, slightly elevated ruby-red papules often 0.5mm-6mm
- Numbers increase with age, most common on trunk, rare on face, hands and feet
- Diagnosis: clinical
- Treatment: unnecessary- reassure
  - (Cosmetic) light electrodessication, laser ablation with IPL or long-pulse Nd:YAG, shave excision



Dermatofibroma

- Clinical findings: firm, nontender subcutaneous nodules in the dermis with or without overlying skin changes
  - Changes might include tan-pink to reddish-brown discoloration
- Occur predominantly on the extremities, mostly asymptomatic and <1 cm in size
- Patients may relate a history of possibly inciting local trauma at the site, such as insect bite or superficial puncture wound from thorns or wood splinters.
- Diagnosis: clinical, consider biopsy if concerning features
- Ddx: DF vs. Dermatofibrosarcoma Protuberans (DFSP)
- Treatment: if diagnosed clinically, no treatment required
  - May shave biopsy or have removed with surgical excision

Common Soft Tissue Masses



Epidermal Inclusion Cyst

- AKA “sebaceous” cyst, epidermoid cyst, infundibular cyst, keratin cyst
- Clinical findings: Freely- movable subcutaneous nodule with overlying central punctum
- Can occur anywhere on the body and in various sizes (from a few mm to several cm) and may progressively enlarge
- Diagnosis is clinical
- Treatment: not necessary, recommended if h/o inflammation/drainage
  - Surgical Excision is definitive treatment, ILK injection or I&D for acutely inflamed/tender cysts

Lipomas

- Common, benign subcutaneous tumors of fat cells
- Clinical findings: Soft, solitary, painless nodules most commonly on the trunk
- Slow growing, typically end up between 2-3 cm in size
- Diagnosis is clinical.
- Treatment: unnecessary unless clinically indicated
  - lesion size, anatomic location, symptoms such as pain, and patient comorbidities
  - Surgical excision is the definitive treatment

Pilar Cyst

- AKA trichilemmal cyst
- Clinical findings: flesh-colored, smooth, mobile, firm, and well-circumscribed nodules
- Occur on the scalp
- Contain keratin
- May be an autosomal dominant trait
- Diagnosis is clinical
- Treatment: surgical excision if desired

Premalignant Neoplasms

Atypical Nevi

- AKA dysplastic nevi
- describe lesions with concerning histologic or clinical features
- It is unclear if individual dysplastic nevi progress to melanoma at higher rates than banal nevi.
- histologically dysplastic nevi are often graded based on the degree abnormality into categories of mild, moderate and severe dysplasia; with severe dysplasia bordering on melanoma, but not quite meeting diagnostic criteria.
- Diagnosis: Shave biopsy
- Treatment: Re-excision if found to be moderately-severely atypical, may clinically monitor if mildly atypical

Risk of Nevus Progression to Melanoma

- Risk of progression of any individual nevus to melanoma over a person's lifetime is about 1 in 3,000 for men and 1 in 11,000 for women.
- Because of the above reason, prophylactic removal of nevi is not part of clinical practice
  - screening for progression of nevi and de novo melanoma development with regular skin exams may result in identification and treatment of melanomas at earlier stages
- Nevi are an independent marker of overall melanoma risk

ABCDE's of Moles and Melanoma

- **A- Asymmetry:** moles should be symmetrically shaped
- **B- Border:** moles should have an even, well defined border. Jagged borders or "blurry" borders could be a concerning feature.
- **C- Color:** moles should have an even color throughout. Some will be light brown, medium brown, or dark brown, but the key is to see even coloring throughout the mole.
- **D- Diameter:** Typically your moles should be smaller than the head of a pencil eraser. (< 6mm)
- **E- Evolving:** Any changing moles should be evaluated. This could be change in size (rapid growth), color, shape, etc. Also, itching, burning, or bleeding moles should be evaluated.

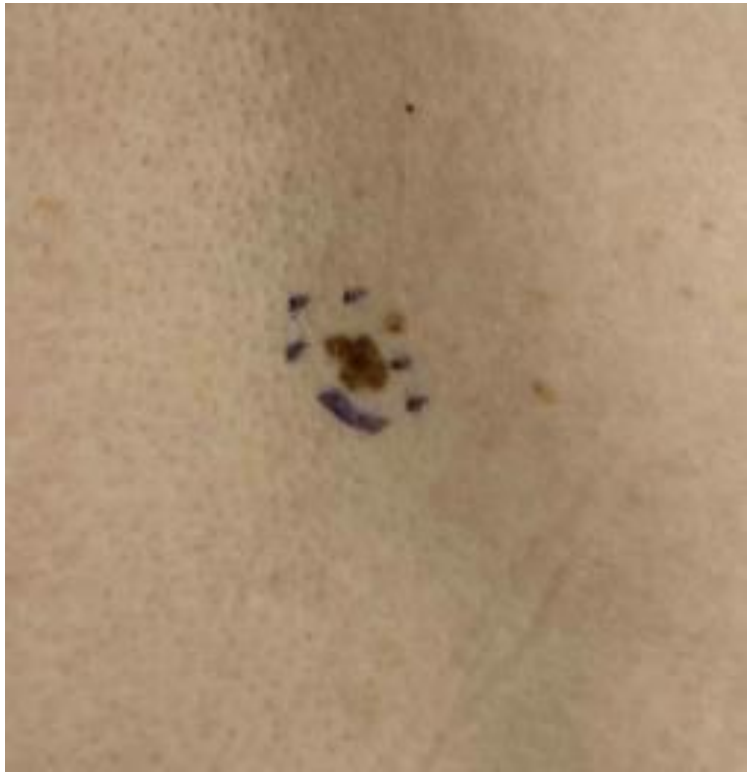



Dysplastic Nevi



Actinic Keratoses

- Most frequently encountered lesions in clinical practice
- Clinical Findings: keratotic pink papules, or gritty papule with erythematous base with associated white to yellow scale and rough
- “Precancerous” lesions that have potential to progress to SCC
- Uncommon under age 40 and may continue to arise with increasing age
- Clinical variants: hypertrophic, pigmented, lichenoid, and atrophic
- Diagnosis: Clinical with inspection and palpation
- Biopsy needed when tender, thick, inflamed, and failure to respond to therapy

Treatment of AKs

- Common: cryotherapy, curettage and electrodessication, or shave excision
- Topical treatments: 5-flurouracil cream, imiquimod 5% cream, diclofenac gel, ingenol mebutate gel
- Procedural field treatments: photodynamic therapy (5-ALA +blue light), chemical peels (TCA), ablative laser

Malignant Neoplasms



Basal Cell Carcinoma

- Most common NMSC, arises de novo, with no known precursor lesions
- Common Clinical Findings
  - Pearly papule with telangiectasias and/or umbilication
  - Erythematous thin plaque on trunk>extremities and pigmented
- Risk factors: middle-aged to older adults who are fair-skinned, UV exposure especially intense episodes of burning
- Subtypes: Nodular, superficial, morpheaform, micronodular, cystic, basosquamous, fibroepithelioma of pinkus
- Slow growing and may ulcerate and cause local destruction, metastases exceedingly rare
- Diagnosis: Shave Biopsy

Basal Cell Carcinoma- Treatment

- Low risk- EDC, curettage and cryosurgery, standard excision with 4-mm margins, topical imiquimod (superficial BCC trunk/extremities), XRT for nonsurgical candidates
- High-risk- standard excision with 10- mm margins, Mohs Micrographic Surgery (MMS), XRT for non-surgical candidates
- Inoperable or metastatic- hedgehog pathway inhibitors (e.g. vismodegib)
- Indications for MMS- recurrent tumor, high-risk anatomic location, tissue preservation, aggressive histologic subtype, perineural invasion, large size (>20 mm), poorly defined clinical borders, prior exposure to XRT, tumor arising within chronic scar, site of positive margins on prior excision, immunosuppressed host, underlying genetic syndrome





Basal Cell Carcinoma



Squamous Cell Carcinoma In-Situ

- AKA Bowen's disease or erythroplasia of Queyrat
- Clinical Findings: solitary or multiple pink or red well-defined macules, papules, plaques, which may be scaling or hyperkeratotic
- Most often caused by UV radiation or HPV infection
- Diagnosis: shave biopsy

Squamous Cell In-Situ Treatment

- Untreated, may progress to invasive SCC
- Effective treatments in some cases:
  - Topical chemotherapy- 5-fluorouracil cream, imiquimod cream
  - Cryosurgery- curettage and cryosurgery
- Surgical Excision
  - Highest cure rate, but greatest chance of disfiguring scars



Invasive Squamous Cell Carcinoma

- Clinical Findings: erythematous to flesh-colored, indurated papule, plaque, or nodule with adherent thick keratotic scale, +/- erosion, ulceration
  - May also find lymphadenopathy due to metastases in advanced cases
- Malignant tumor of squamous cells, arising in the epidermis and stratified squamous mucosa
- Most common etiologies UV exposure and HPV infection
- Often a precursor or “precancerous” lesion was present prior to invasive SCC
- Diagnosis: Shave Biopsy

Invasive Squamous Cell Carcinoma-Treatment

- Surgery- excision or MMS depending on localization and extent of lesion
- Remission rate is 90% after treatment





Squamous Cell Carcinoma

Melanoma In-Situ and Lentigo Maligna

- Clinical findings: irregular macule that has changed (size, shape, color)
- malignant tumor is restricted to the epidermis, stage 0
- Considered “Low-risk” melanoma
- Diagnosis: Use ABCDEs of moles to help identify, saucerization biopsy if concerned for melanoma
- Treatment: Wide Local Excision with 0.5-1 cm margins or slow-MMS
- 99.9% 5-year survival; 98.9% 10-year survival





Melanoma In-Situ

Cutaneous Melanoma

- Accounts for 4% of overall skin cancers, but 80% of skin-cancer related deaths
- 4 major subtypes- superficial spreading, nodular, lentigo maligna, and acral lentiginous melanoma
- progression of melanoma emphasizes the stepwise transformation of melanocytes to melanoma
  - proliferation of melanocytes in the process of forming nevi and the subsequent development of dysplasia, hyperplasia, invasion, and metastasis
- Melanoma can also arise in the uveal tract, retinal pigment epithelium, gastrointestinal mucosa, or leptomeninges

Cutaneous Melanoma





Cutaneous Melanoma

- Approximately 33% of melanomas are derived from benign, melanocytic nevi
- Risk Factors:
  - family history of melanoma, multiple benign or atypical nevi, personal history of previous melanoma, immunosuppression, sun sensitivity, and exposure to ultraviolet radiation
- If melanoma arises in nevi, most likely to be non-chronically sun-damaged skin
- If melanoma arises in chronically sun-damaged skin, likely it did not arise from a nevus

Diagnosing Melanoma

- ABCDEs of moles and melanoma
  - EFGs added-elevated, firm, and growing
- “ugly duckling sign” and “little red riding hood sign”
- Biopsy should attempt to remove entire lesion, including depth adequate to determine Breslow depth
  - Excisional biopsy vs. saucerization vs. punch

Treatment of Melanoma

- Current therapeutic approaches include surgical resection, chemotherapy, photodynamic therapy, immunotherapy, biochemotherapy, and targeted therapy.
- Wide Local Excision for stage I–IIIB melanoma
  - Margins of 1 cm for tumors with a thickness of up to 2 mm
  - Margins of 2 cm for tumors thicker than 2 mm.
- Sentinel Lymph node biopsy provides accurate staging(consider if T >1 mm)
- For solitary melanoma metastasis, metastasectomy
- For metastatic melanoma, chemotherapy treatment may be considered.
- Radiotherapy can be useful for the treatment of skin, bone, and brain metastases

Survival Rates

- Stage I/II: 89-95% 5 year survival
- Stage II: 45-79% 5 year survival
- Stage III: 24-70% 5 year survival
- Stage IV: 7-19% 5 year survival
- Close follow up- every 3 months for 2 years, every 6 months until 5 years
- Advise patient to also get yearly ophthalmology exam as well

References

1. Fitzpatrick TB, et al. *Color Atlas and Synopsis of Clinical Dermatology*. New York: McGraw-Hill; 2001:26, 255-265.
2. Damsky WE, Bosenberg M. Melanocytic nevi and melanoma: unraveling a complex relationship. *Oncogene*. 2017;36(42):5771-5792. doi:10.1038/onc.2017.189
3. Bolognia, JL., et al. *Dermatology Essentials.* New York: Elsevier;2014: 88, 858-873, 894-928.
4. Heymann WR. Life is Just a Bowl of Cherry Angiomas. *Dermatology World Insights and Inquires.* 2019: 1 (13)
5. Myers DJ, Fillman EP. Dermatofibroma. [Updated 2024 Feb 29]. In: StatPearls [Internet]. Treasure Island (FL): StatPearls Publishing; 2020 Jan-. Available from: https://www.ncbi.nlm.nih.gov/books/NBK470538
6. Weir CB, St.Hilaire NJ. Epidermal Inclusion Cyst. [Updated 2023 August 8]. In: StatPearls [Internet]. Treasure Island (FL): StatPearls Publishing; 2020 Jan-. Available from: https://www.ncbi.nlm.nih.gov/books/NBK532310/

References cont.

7. Kolb L, Barazi H, Ameer MA, et al. Lipoma. [Updated 2023 August 8]. In: StatPearls [Internet]. Treasure Island (FL): StatPearls Publishing; 2020 Jan-. Available from: https://www.ncbi.nlm.nih.gov/books/NBK507906
8. Al Aboud DM, Patel BC. Pilar Cyst. [Updated 2023 August 14]. In: StatPearls [Internet]. Treasure Island (FL): StatPearls Publishing; 2020 Jan-. Available from: https://www.ncbi.nlm.nih.gov/books/NBK534209/?report=classic
9. Beaulieu D, Fathi R, Srivastava D, Nijhawan RI. Current perspectives on Mohs micrographic surgery for melanoma. *Clin Cosmet Investig Dermatol*. 2018;11:309-320. doi:10.2147/CCID.S137513
10. Bauman CA, Emary P, Damen T, Dixon H. Melanoma in situ: a case report from the patient's perspective. *J Can Chiropr Assoc*. 2018;62(1):56-61
11. Miller AJ and Mihm MC. Melanoma. *N Engl J Med.* 2006; 355: 51-65. DOI: 10.1056/NEJMra052166
12. Domingues B, Lopes JM, Soares P, Pópulo H. Melanoma treatment in review. *Immunotargets Ther*. 2018;7:35-49. doi:10.2147/ITT.S134842