Son of an Itch! What's so Itchy?

Margaret McKernan DMSc, PA-C

Apex Dermatology

Cleveland, OH

Disclosures

- I have relevant relationships with ineligible companies to disclose within the past 24 months
  - Leo pharma advisory board
  - Johnson&Johnson advisory board

Objectives

- Apply a systematic approach to evaluating patients with itch
- Describe the underlying mechanisms driving itch sensation
- Differentiate various etiologies of pruritus
- Select evidence-based treatment options tailored to address the various causes of itch

Definition of Pruritus

- *Pruritus*- an unpleasant sensation of the skin that elicits a desire to scratch
- *Dysesthesia*- an unpleasant, abnormal sensation that can either be spontaneous or evoked
  - Abnormal, unpleasant sensations may include pain, pruritus ('neuropathic itch'), tingling, burning, ('pins and needles')
- The most common skin-related symptom in dermatology
- Results from activation of the sensory nervous system, involving four sequential levels: the peripheral nervous system, the dorsal root ganglia, the spinal cord, and the brain

Bolognia JL, Schaffer JV, Duncan KO, Ko CJ. *Dermatology Essentials*. Saunders; 2014.

Etiology of Pruritus



Often multiple etiologies which can make diagnosis a challenge



Primary or idiopathic pruritus- no readily apparent skin disease, underlying etiology, or associated condition



Secondary pruritus- secondary to a dermatologic disease

Bolognia JL, Schaffer JV, Duncan KO, Ko CJ. *Dermatology Essentials*. Saunders; 2014.

Four Primary Categories



Pruritoceptive itch- initiated by skin disorders



Neurogenic itch- generated by the CNS and caused by systemic disorders



Neuropathic itch- caused by anatomic lesions of the central or peripheral nervous system



Psychogenic itch- the type observed in parasitophobia

James WD, Elston DM, Treat J, Rosenbach MA, Neuhaus I, George Clinton Andrews. *Andrews' Diseases of the Skin : Clinical Dermatology*. 13th ed. Elsevier; 2019.

Internal Causes of Itch

- Identifying the underlying etiology is important in determining appropriate management
- Most common
  - Liver disease and hepatitis C
  - Renal failure
  - Diabetes mellitus
  - Hypothyroidism
  - Hyperthyroidism
  - Hematopoietic diseases (iron deficiency anemia, polycythemia vera)
  - Neoplastic diseases (lymphoma)
  - Leukemia
  - Internal solid-tissue malignancies
  - Intestinal parasites
  - Multiple sclerosis
  - Acquired immunodeficiency syndrome (AIDS)
  - Connective tissue diseases (esp dermatomyositis and neuropsychiatric diseases esp anorexia nervosa)

James WD, Elston DM, Treat J, Rosenbach MA, Neuhaus I, George Clinton Andrews. *Andrews' Diseases of the Skin : Clinical Dermatology*. 13th ed. Elsevier; 2019.

Approach to Chronic Pruritus with No Obvious Specific Skin Disease

- History- patients may require multiple examinations because idiopathic pruritus can arise prior to manifestations of the underlying disorder (e.g. lymphoma) or with time, more specific lesions may appear (e.g. bullous pemphigoid)
- Skin exam-
  - "Butterfly sign"- lesions sparing the mid upper back, an area of patient-hand inaccessibility
    - Suggestive of pruritus NOT associated with a dermatologic disorder

Bolognia JL, Schaffer JV, Duncan KO, Ko CJ. *Dermatology Essentials*. Saunders; 2014.
James WD, Elston DM, Treat J, Rosenbach MA, Neuhaus I, George Clinton Andrews. *Andrews' Diseases of the Skin : Clinical Dermatology*. 13th ed. Elsevier; 2019.

Butterfly Sign



Approach to Itch

- History and review of systems, including household contacts
- Complete skin exam and lymph node examination
- Exclude infestations (e.g. scabies) and confounding factors (e.g. dermographism, xerosis, irritations) and treat accordingly
- Review medications (rx, OTC, and illicit) as well as supplements for drug-induced pruritus (e.g. CCB, PPI, narcotics, amphetamines)

Bolognia JL, Schaffer JV, Duncan KO, Ko CJ. *Dermatology Essentials*. Saunders; 2014.
James WD, Elston DM, Treat J, Rosenbach MA, Neuhaus I, George Clinton Andrews. *Andrews' Diseases of the Skin : Clinical Dermatology*. 13th ed. Elsevier; 2019.

Approach to Itch

- If not obvious etiology, obtain screening laboratory tests
  - CBC, ESR, TSH, BUN/Cr, LDH, Liver function tests, further…if indicated hepatitis screen, O&P
- Consider patch testing if history or distribution suggestive
- Consider less common causes
  - Autoimmune blistering disorders, lymphoma, endocrinopathies, metabolic disorders, celiac disease
- Refer to PCP for age-appropriate cancer screenings
- History dependent- travel O&P, HIV testing if risk, consult psychiatry if psychiatric illness

Bolognia JL, Schaffer JV, Duncan KO, Ko CJ. *Dermatology Essentials*. Saunders; 2014.
James WD, Elston DM, Treat J, Rosenbach MA, Neuhaus I, George Clinton Andrews. *Andrews' Diseases of the Skin : Clinical Dermatology*. 13th ed. Elsevier; 2019.

Itchy Conditions

Atopic Dermatitis

- Chronic, relapsing skin disorder characterized predominantly by xerosis and pruritus
  - Most common inflammatory skin disease
- Very common in infancy, affects 15-20% of all people in childhood
- Often seen as part of the atopic triad- allergic rhinitis, asthma, atopic dermatitis



Kim J, Kim BE, Leung DYM. Pathophysiology of atopic dermatitis: Clinical implications. *Allergy Asthma Proc*. 2019;40(2):84-92. doi:10.2500/aap.2019.40.4202

Atopic Dermatitis Pathophysiology

- Not completely understood
- Characterized by skin barrier dysfunction
  - Impaired filaggrin production (major structural protein in the stratum corneum)
  - Reduced ceramide levels
  - Increased transepidermal water loss
  - Dehydration of the skin
- Dysregulation of the Immune System
  - Type 2 cytokines (IL-4 and IL-13) as well as interleukin 17 and interleukin 22 contribute to skin barrier dysfunction
- Genetic predilection

Saavedra AP, Roh EK, Anar Mikailov. *Fitzpatrick's Color Atlas and Synopsis of Clinical Dermatology, 9/E*. McGraw Hill Professional; 2023.



Atopic Dermatitis

Topical Corticosteroids

- Mainstay for atopic dermatitis for many years
- MOA: consisting of anti-inflammatory, anti-mitotic, and immunosuppressive effects
  - Vasoconstriction of the blood vessels within the upper dermis decreases the number of inflammatory mediators being delivered to the region applied
  - Modify the functions of epidermal and dermal cells and of leukocytes participating in proliferative and inflammatory skin diseases

Gabros S, Nessel TA, Zito PM. Topical Corticosteroids. [Updated 2023 Jul 10]. In: StatPearls [Internet]. Treasure Island (FL): StatPearls Publishing; 2023 Jan-. Available from: https://www.ncbi.nlm.nih.gov/books/NBK532940/
Kragballe K. Topical corticosteroids: mechanisms of action. *Acta Derm Venereol Suppl (Stockh)*. 1989;151:7-52

Topical Corticosteroids

- Local side effects: atrophy, striae, rosacea, perioral dermatitis, acne, and purpura
  - Less common: hypertrichosis, pigment alteration, and delayed wound healing
- Systemic side effects: glaucoma, hypothalamic-pituitary axis suppression, Cushing syndrome, hypertension, and hyperglycemia
- Patient education: Local effects are much more common than systemic effects
  - Occur predominantly with long term use, high potency, and thin epidermal skin

Gabros S, Nessel TA, Zito PM. Topical Corticosteroids. [Updated 2023 Jul 10]. In: StatPearls [Internet]. Treasure Island (FL): StatPearls Publishing; 2023 Jan-. Available from: https://www.ncbi.nlm.nih.gov/books/NBK532940/

Topical Corticosteroids

- Potency: Low, medium, high, and ultra high
- Vehicle: Lotion, shampoo, foam, gel, cream, ointment, solution
- Generally dosed BID x2 weeks

Potency Strength	Generic Name
Super potent/ultra high	augmented betamethasone dipropionate, clobetasol propionate, halobetasol propionate,
High	amcinonide, desoximetasone, fluocinonide
Medium	betamethasone valerate, fluocinolone acetonide, mometasone furoate, triamcinolone acetonide
Low	desonide, hydrocortisone

Bolognia JL, Schaffer JV, Duncan KO, Ko CJ. *Dermatology Essentials*. Saunders; 2014.

Atopic Dermatitis Advanced Treatments

- Topicals
  - ruxolitinib BID
  - roflumilast BID
- Injectables
  - dupilumab 300 mg SQ q2 weeks
  - tralokinumab 300 mg SQ q2 or 4 weeks
  - lebrikizumab 250 mg SQ q2 or 4 weeks
- Orals
  - upadacitinib 15 or 30 mg QD
  - abrocitinib 100 or 200 mg QD

Alenazi SD. Atopic dermatitis: a brief review of recent advances in its management. *Dermatol Reports*. 2023;15(3):9678. Published 2023 May 23. doi:10.4081/dr.2023.9678

Bullous Pemphigoid

- Immunobullous disease due to circulating autoantibodies
- More common in the elderly and can be drug-induced (e.g. furosemide)
- Characterized by both pruritic fixed urticarial plaques and tense bullae
  - Oral lesions are less common
- Pruritus and nonspecific eczematous or papular lesions can precede the more characteristic cutaneous lesions

James WD, Elston DM, Treat J, Rosenbach MA, Neuhaus I, George Clinton Andrews. *Andrews' Diseases of the Skin : Clinical Dermatology*. 13th ed. Elsevier; 2019.



Bullous Pemphigoid

Bullous Pemphigoid Treatment

- Superpotent topical corticosteroids
- Nicotinamide plus minocycline, doxycycline, or tetracycline
- Erythromycin, penicillins
- Dapsone, sulfonamides
- Topical immunomodulators (e.g. tacrolimus)
- Severe cases
  - Oral corticosteroids, azathioprine, mycophenolate mofetil, methotrexate, chlorambucil, cyclophosphamide, IVIg, plasma exchange, rituximab
- dupilumab (?)

James WD, Elston DM, Treat J, Rosenbach MA, Neuhaus I, George Clinton Andrews. *Andrews' Diseases of the Skin : Clinical Dermatology*. 13th ed. Elsevier; 2019.

Spontaneous Urticaria

- Urticaria- characterized by wheals, pale to pink-red edematous papules or plaques
- Angioedema- deeper dermal and subcutaneous or submucosal swelling, affected areas are ill-defined have minimal or no overlying erythema, and may be painful as well as pruritic
- Individual wheals last <24 hours
- Acute <6 weeks
- Chronic >6 weeks
- Female: male 2:1

James WD, Elston DM, Treat J, Rosenbach MA, Neuhaus I, George Clinton Andrews. *Andrews' Diseases of the Skin : Clinical Dermatology*. 13th ed. Elsevier; 2019.



Wheal

Causes of Acute and Chronic Spontaneous Urticaria

Acute Urticaria	Chronic Urticaria
Infection (e.g. URI) (~40%)	Autoimmune (~40-50%)
Drug (~10%)	Chronic Infection (e.g. parasitic) (<5%)
Food (<1%)	Idiopathic (~50%)
Idiopathic (~50%)	

Bolognia JL, Schaffer JV, Duncan KO, Ko CJ. *Dermatology Essentials*. Saunders; 2014.

Inducible Urticaria

- Dermographism
- Delayed Pressure Urticaria
- Cold Urticaria
- Cholinergic Urticaria
- Solar Urticaria
- Aquagenic Urticaria

Bolognia JL, Schaffer JV, Duncan KO, Ko CJ. *Dermatology Essentials*. Saunders; 2014.

Treatment

- Eliminate any modifiable cause
- Avoid physical triggers and drug that stimulate mast cell degranulation (e.g. aspirin, NSAIDS, codeine, morphine)
- Begin with H-1 long acting low sedating antihistamines
  - (levo)cetirizine 2-4x the standard dose
  - Add multiple (e.g. (des)loratadine)
- Add H-1 sedating antihistamines
  - doxepin (10-50mg) QHS
- Add H-2 antihistamines
  - ranitidine
- Consider immunologic therapy if refractory (i.e. methotrexate, cyclosporine, omalizumab)
- dupilumab (?)

Bolognia JL, Schaffer JV, Duncan KO, Ko CJ. *Dermatology Essentials*. Saunders; 2014.
James WD, Elston DM, Treat J, Rosenbach MA, Neuhaus I, George Clinton Andrews. *Andrews' Diseases of the Skin : Clinical Dermatology*. 13th ed. Elsevier; 2019.

Id Reaction

- More widespread distribution of dermatitis that follows by days to weeks the development of localized areas of dermatitis (e.g. allergic contact dermatitis, stasis dermatitis, inflammatory tinea infections)
- Can also be a rebound phenomenon when there has been too rapid of a taper of systemic corticosteroids (e.g. methylprednisolone dose pack for rhus dermatitis)
- Typical sites of involvement- extensor aspects of extremities, palms and soles, usually in a symmetric pattern
- Treatment- topical corticosteroids and oral antihistamines, +/- systemic corticosteroids

Bolognia JL, Schaffer JV, Duncan KO, Ko CJ. *Dermatology Essentials*. Saunders; 2014.
James WD, Elston DM, Treat J, Rosenbach MA, Neuhaus I, George Clinton Andrews. *Andrews' Diseases of the Skin : Clinical Dermatology*. 13th ed. Elsevier; 2019.

Erythema Ab Igne

- Skin reaction to thermal injury
- Common cause chronic heating pad use
- Netlike pattern of blue-gray discoloration, sometimes with erythema/scale
- May burn, sting, or itch
- d/c heating pad use
- May resolve slowly over several months, but may also permanently scar/hyperpigment

High, W. A., & Prok, L. D. (2021). *Dermatology Secrets* (6th ed.). Elsevier.

Erythema Ab Igne

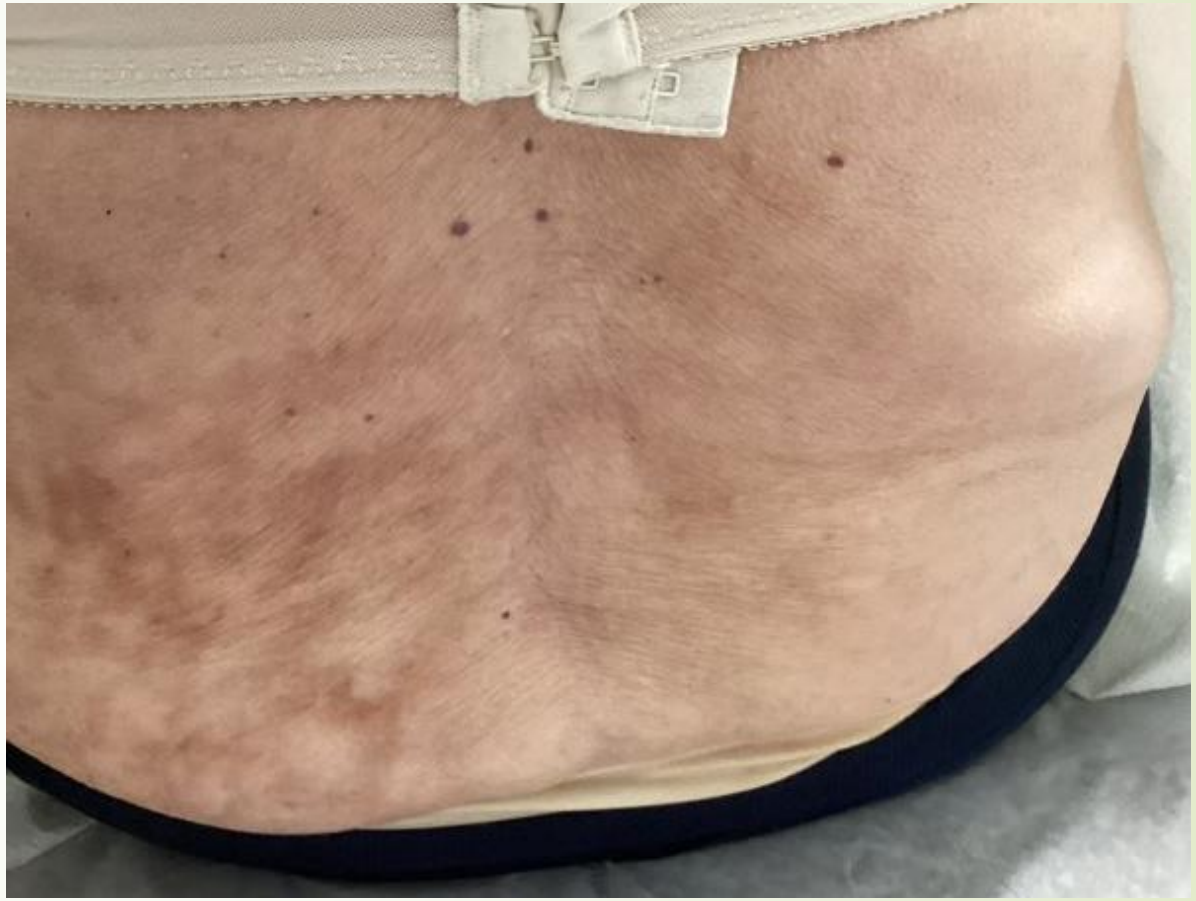

Stasis Dermatitis

Characterized by pruritic dermatitis with scale-crust and sometimes oozing that favors the shins and calves

Patients often have history of chronic lower extremity edema and h/o DVT and/or recurrent cellulitis

Bolognia JL, Schaffer JV, Duncan KO, Ko CJ. *Dermatology Essentials*. Saunders; 2014.
James WD, Elston DM, Treat J, Rosenbach MA, Neuhaus I, George Clinton Andrews. *Andrews' Diseases of the Skin : Clinical Dermatology*. 13th ed. Elsevier; 2019.

Stasis Dermatitis

- Treatment:
  - Mild topical corticosteroids and emollients
  - Rule out infectious component
  - Leg elevation, compression stockings
  - Referral to vascular- ablation of large varicosities



Bolognia JL, Schaffer JV, Duncan KO, Ko CJ. *Dermatology Essentials*. Saunders; 2014.

Prurigo Nodularis

- Multiple, discrete, firm papulonodules with central scale-crust due to chronic and repetitive scratching and picking
- Degree of pruritus can vary from moderate to intense
- Commonly extremities, upper back, and buttocks
- Itch-scratch cycle needs broken with symptomatic relief and discussion of psychosocial issues

Bolognia JL, Schaffer JV, Duncan KO, Ko CJ. *Dermatology Essentials*. Saunders; 2014.
James WD, Elston DM, Treat J, Rosenbach MA, Neuhaus I, George Clinton Andrews. *Andrews' Diseases of the Skin : Clinical Dermatology*. 13th ed. Elsevier; 2019.

Prurigo Nodularis Treatment

- Superpotent topical corticosteroid
- Intralesional corticosteroid
- Phototherapy
- Thalidomide
- New FDA approved for PN
  - dupilumab 2023 (IL-4/13 inhibitor)
  - nemolizumab 2024 (IL-31 inhibitor)
- If no underlying reversible disorder is detected, PN can be difficult to treat

Bolognia JL, Schaffer JV, Duncan KO, Ko CJ. *Dermatology Essentials*. Saunders; 2014.
James WD, Elston DM, Treat J, Rosenbach MA, Neuhaus I, George Clinton Andrews. *Andrews' Diseases of the Skin : Clinical Dermatology*. 13th ed. Elsevier; 2019.









PN

Lichen Planus

- Flat-topped (lichenoid) papules that are often polygonal in shape and purple in color may coalesce into plaques
  - Wickham's striae- network of fine white lines on eh surface of papules and plaques
  - Scalp, wrists, forearms, genitalia, distal lower extremities esp. shins, and presacral areas
- Several subtypes
  - Actinic, acute exanthematous, annular, atrophic, bullous, hypertrophic, inverse, LP pemphigoides, LP pigmentosus, Lichenplanopilaris, linear, nail, oral, ulcerative, vulvovaginal, etc

Bolognia JL, Schaffer JV, Duncan KO, Ko CJ. *Dermatology Essentials*. Saunders; 2014.
James WD, Elston DM, Treat J, Rosenbach MA, Neuhaus I, George Clinton Andrews. *Andrews' Diseases of the Skin : Clinical Dermatology*. 13th ed. Elsevier; 2019.

Lichen Planus Treatment

- Topical or intralesional corticosteroids
- Topical calcineurin inhibitors
- Phototherapy
- Consider systemic tx if severe- oral corticosteroids, hydroxychloroquine, acitretin

Bolognia JL, Schaffer JV, Duncan KO, Ko CJ. *Dermatology Essentials*. Saunders; 2014.
James WD, Elston DM, Treat J, Rosenbach MA, Neuhaus I, George Clinton Andrews. *Andrews' Diseases of the Skin : Clinical Dermatology*. 13th ed. Elsevier; 2019.



Dermatitis Herpetiformis

- Autoimmune bullous disease
  - Manifestation of celiac disease
- Pruritic vesicles on an erythematous base and edematous erythematous papules often grouped
  - May only have excoriated papules and hemorrhagic crusts
  - Most commonly on elbows, forearms, knees, posterior neck, and presacral/buttock region

Bolognia JL, Schaffer JV, Duncan KO, Ko CJ. *Dermatology Essentials*. Saunders; 2014.
James WD, Elston DM, Treat J, Rosenbach MA, Neuhaus I, George Clinton Andrews. *Andrews' Diseases of the Skin : Clinical Dermatology*. 13th ed. Elsevier; 2019.

Dermatitis Herpetiformis Treatment



Gluten-free diet



Dapsone

Typically 100 mg daily

Baseline G6PD prior to initiation

Improvement with dapsone support diagnosis of DH

Bolognia JL, Schaffer JV, Duncan KO, Ko CJ. *Dermatology Essentials*. Saunders; 2014.
James WD, Elston DM, Treat J, Rosenbach MA, Neuhaus I, George Clinton Andrews. *Andrews' Diseases of the Skin : Clinical Dermatology*. 13th ed. Elsevier; 2019.

Notalgia Paresthetica

- Focal, intense pruritus of the upper back, most commonly along the medial scapular borders
  - Sometimes associated with pain, burning
  - Often there is a hyperpigmented patch due to chronic rubbing/scratching
- Thought to be related to SNR impingement at the level of the spinal cord due to osteoarthritis or more distally due to impingement or irritation from inflamed muscles or other connective tissue
- Treatment:
  - Topical capsaicin, topical anesthetics, gabapentin

Bolognia JL, Schaffer JV, Duncan KO, Ko CJ. *Dermatology Essentials*. Saunders; 2014.
James WD, Elston DM, Treat J, Rosenbach MA, Neuhaus I, George Clinton Andrews. *Andrews' Diseases of the Skin : Clinical Dermatology*. 13th ed. Elsevier; 2019.

Pigmentation changes from chronic excoriation



Psoriasis

- Well-demarcated erythematous plaques with silvery scale
  - Also possible- sterile pustules, glistening plaques in intertriginous areas
- Has a genetic predilection, especially in those who present at a younger age
- Triggers:
  - Infection- streptococcal pharyngitis, HIV infection
  - Medications- Prednisone, Lithium, Anti-malarials, NSAIDS, Beta blockers
  - Koebner phenomenon- elicitation of psoriatic lesions by traumatizing the skin
- Evaluate for psoriatic arthritis

Bolognia JL, Schaffer JV, Duncan KO, Ko CJ. *Dermatology Essentials*. Saunders; 2014.
James WD, Elston DM, Treat J, Rosenbach MA, Neuhaus I, George Clinton Andrews. *Andrews' Diseases of the Skin : Clinical Dermatology*. 13th ed. Elsevier; 2019.

Psoriasis Treatment

- Topical and Intralesional corticosteroids
- Topical vitamin D analogs (calcipotriene)
- Topical retinoids adjunctively (tazarotene)
- Topical tapinarof and roflumilast
- Methotrexate, cyclosporine, acitretin
- Oral apremilast and deucravacitinib
- Injectable TNF-a inhibitors, IL-17 inhibitors, IL-12/23 inhibitors, IL-23 inhibitors

Bolognia JL, Schaffer JV, Duncan KO, Ko CJ. *Dermatology Essentials*. Saunders; 2014.
James WD, Elston DM, Treat J, Rosenbach MA, Neuhaus I, George Clinton Andrews. *Andrews' Diseases of the Skin : Clinical Dermatology*. 13th ed. Elsevier; 2019.







Psoriasis

Burning Mouth Syndrome (Orodynia)

- Burning mucosal pain without clinically detectable oral lesions
  - Typically b/l, anterior 2/3 of tongue, palate and lower lip
- Most common middle-aged to elderly women
- Diagnosis of exclusion- r/o malignancy, vitamin deficiencies (e.g. folate, B12, candidiasis, xerostomia)
- Increased incidence of h/o depression and anxiety
- Treatment
  - Oral tri-cyclic antidepressants, gabapentin
  - Topical anesthetics

Bolognia JL, Schaffer JV, Duncan KO, Ko CJ. *Dermatology Essentials*. Saunders; 2014.
James WD, Elston DM, Treat J, Rosenbach MA, Neuhaus I, George Clinton Andrews. *Andrews' Diseases of the Skin : Clinical Dermatology*. 13th ed. Elsevier; 2019.

Delusions of Parasitosis

- Monosymptomatic, hypochondriacal psychosis characterized by a fixed and false (delusional) belief that an individual is infested with parasites, despite any objective evidence
  - Formication- cutaneous sensation of crawling, biting and/or stinging
- Typical onset age 50-60
- Patients often bring in bits of skin, lint, and other specimens to prove the existence of the supposed parasites
- Treatment: establish rapport, pimozide or atypical antipsychotics

Bolognia JL, Schaffer JV, Duncan KO, Ko CJ. *Dermatology Essentials*. Saunders; 2014.
James WD, Elston DM, Treat J, Rosenbach MA, Neuhaus I, George Clinton Andrews. *Andrews' Diseases of the Skin : Clinical Dermatology*. 13th ed. Elsevier; 2019.

Cutaneous T-cell Lymphoma (CTCL)

- AKA Mycosis Fungoides, most common subtype of CTCL (60%)
- CTCL is a primarily indolent, heterogenous group of NHLs localized to the skin
  - Lymphoma- malignancy of the immune system that is characterized by an abnormal proliferating of lymphocytes, can arise in B or T cells or natural killer lymphocytes
- Persistent scaly patches that respond poorly to topical therapy with emollients and medium potency topical steroids
- Affects M>F, and increased incidence with age
- Average time to diagnosis- 7 years

Bolognia JL, Schaffer JV, Duncan KO, Ko CJ. *Dermatology Essentials*. Saunders; 2014.
James WD, Elston DM, Treat J, Rosenbach MA, Neuhaus I, George Clinton Andrews. *Andrews' Diseases of the Skin : Clinical Dermatology*. 13th ed. Elsevier; 2019.





MF

- Referral to oncology for management

CTCL- Sezary Syndrome

- Second most common type of CTCL (5%)
- Leukemic variant of CTCL
- Triad
  - Erythroderma
  - Lymphadenopathy
  - Atypical circulating mononuclear cells (Sezary cells)
- More resistant to treatment than MF

Bolognia JL, Schaffer JV, Duncan KO, Ko CJ. *Dermatology Essentials*. Saunders; 2014.
James WD, Elston DM, Treat J, Rosenbach MA, Neuhaus I, George Clinton Andrews. *Andrews' Diseases of the Skin : Clinical Dermatology*. 13th ed. Elsevier; 2019.

CTCL Workup

Recommended Evaluation of patients with CTCL	
Physical Exam	Exam of entire skin, palpation of lymph nodes, palpation of organomegaly/masses
Lab studies	CBC with Sezary screen, Sezary flow cytometric study, TCR gene rearrangement of peripheral blood lymphocytes if Sezary syndrome suspected, CMP, LDH
Imaging	Contrast-enhanced CT scan of neck/chest/abdomen and pelvis or integrates whole-body PET/CT scan
Biopsy	Biopsy of suspicious skin sites, dermatopathology review of biopsy

High, W. A., & Prok, L. D. (2021). *Dermatology Secrets* (6th ed.). Elsevier.

Paget's Disease

- Appears as well-defined small eczematous patch
  - Can be crusted, moist, and/or scaly
- Most common on the female breast (Paget's Disease)
- Indicative of underlying ductal carcinoma
  - Despite possibility of no breast mass and normal mammogram
- Can also occur axilla, groin, or anogenital skin (Extramammary Paget's disease)
- Skin has "strawberries and cream" appearance
- Often associated with underlying adnexal carcinoma

High, W. A., & Prok, L. D. (2021). *Dermatology Secrets* (6th ed.). Elsevier.

Acute Cutaneous Lupus Erythematosus (ACLE)

- Acute malar rash or generalized rash in photodistributed region
  - "butterfly" rash
- Nearly all patients with ACLE will have SLE
  - Check CBC, UA, CMP, ANA
- Should improve as SLE improves and resolve without scarring
- Spares nasolabial folds

High, W. A., & Prok, L. D. (2021). *Dermatology Secrets* (6th ed.). Elsevier.



Lupus Rash Vs Rosacea.; 2025. Available from: https://onlydifferences.com/lupus-rash-vs-rosacea/

Subacute Cutaneous Lupus Erythematosus (SCLE)

- Scaly, superficial, inflammatory macules, patches, papules, and plaques that are photodistributed
  - Upper chest and back, lateral neck, dorsal arms, and forearms
  - Subtypes: annular, serpiginous, psoriasiform, and pityriasiform
- Should be monitored for systemic disease, but often less serious SLE

High, W. A., & Prok, L. D. (2021). *Dermatology Secrets* (6th ed.). Elsevier.

Transient Acantholytic Dermatosis

- AKA Grover's Disease
- Crusted pruritic skin-colored to pink papules and papulovesicles on the trunk, primarily in sun-exposed areas
- Can be transient, but is often persistent
- Most common in middle-aged males
- Treatment: low to mid potency topical corticosteroids
  - Avoidance of aggravating factors: heat, friction, sun exposure

High, W. A., & Prok, L. D. (2021). *Dermatology Secrets* (6th ed.). Elsevier.



Darier Disease

- Autosomal dominant, peak presentation during adolescence
- Crusted pink-red to brown papules that may coalesce into plaques in "seborrheic" distribution
- Flat-topped skin-colored to brown papules on dorsal hands and feet
- Exacerbated by sunlight, heat, occlusion, sweat, bacterial colonization
- Treatment
  - Topical retinoids and topical corticosteroids
  - Oral retinoids
  - Occasionally- topical and/or oral antibiotics and antifungals

High, W. A., & Prok, L. D. (2021). *Dermatology Secrets* (6th ed.). Elsevier.

Benign Familial Pemphigus (Hailey-Hailey Disease)

- Rare, autosomal dominant, intradermal bullous disease
- Presents in adolescence or early adulthood
- Erosions, blisters, and waxy papules present on sun-exposed areas (neck/back) and areas of friction (axillae and groin)
  - Non-intertriginous: Begin as vesicles that rupture and leave advancing edge of scale and hypopigmented center
  - Intertriginous: more likely to have moist, red, fissured areas or vegetating warty papules and plaques
- 70% of HHD patients have longitudinal white bands in their fingernails (longitudinal leukonychia)

High, W. A., & Prok, L. D. (2021). *Dermatology Secrets* (6th ed.). Elsevier.

Hailey-Hailey Treatment

- Oral antibiotics
  - Doxycycline 100 mg daily
- Medium to high potency topical steroids
- For intertriginous also consider
  - Antiyeast creams (ketoconazole)
- Severe, recalcitrant cases
  - Oral cyclosporine, MTX, dapsone, 5-fluoruracil
  - CO_2 laser, excision, skin grafting



Konstantinou, M. P. (2023, August 14). *Benign familial pemphigus (Hailey-Hailey disease)*. StatPearls [Internet]. https://www.ncbi.nlm.nih.gov/books/NBK585136/

Gianotti-Crosti Syndrome

- AKA Papular Acrodermatitis of Childhood
- Monomorphous, flat-topped, pink-brown papules or papulovesicles
- Involving face, buttocks, forearms, and extensor legs (3/4)
- Symmetry
- Duration at least 10 days
- Negative clinical features: extensive truncal lesions or scaly lesions
- Viral exanthem
  - In today's age it is most commonly caused by EBV, but numerous infectious agents have been implicated
- Affects children age 6 months to 14 years old
- Self-limited

James WD, Elston DM, Treat J, Rosenbach MA, Neuhaus I, George Clinton Andrews. *Andrews' Diseases of the Skin : Clinical Dermatology*. 13th ed. Elsevier; 2019.

Localized Granuloma Annulare

- Relatively common, idiopathic disorder of the dermis and subcutaneous tissue
- Most cases spontaneously resolve, >50% within 2 years
- Most common is localized GA, although many morphologies exist
- Tend to affect children and young to middle-aged adults
- Dorsal surfaces of hands/feet and occasionally ankles/elbows
- Erythematous to violaceous, thinly-bordered plaques or papules that slowly spread peripherally while undergoing central involution

James WD, Elston DM, Treat J, Rosenbach MA, Neuhaus I, George Clinton Andrews. *Andrews' Diseases of the Skin : Clinical Dermatology*. 13th ed. Elsevier; 2019.



GA

Granuloma Annulare treatment

- Mild cases- no treatment
- Intralesional steroids- general first line treatment
- Superpotent topical corticosteroids, topical calcineurin inhibitors, and topical imiquimod may be effective
- Excimer laser, fractional photothermolysis, or photodynamic therapy
- Systemic corticosteroids may be very effective in high doses, but usual immediate relapses make this less desirable

James WD, Elston DM, Treat J, Rosenbach MA, Neuhaus I, George Clinton Andrews. *Andrews' Diseases of the Skin : Clinical Dermatology*. 13th ed. Elsevier; 2019.

Alopecia

Alopecia Areata

- Circumscribed area of hair loss with distinct borders
  - May be preceded by pruritus and burning
  - The skin is smooth without scarring, scale, erythema, or pigment change
  - Exclamation point hairs
- Most common on scalp, but can also affect eyebrows, eyelashes, and beard
- Associated with nail findings- nail pitting, trachyonychia, brittle nails, onycholysis, koilonychia, onychomadesis

Bobonich M, Nolen M, Honaker J, DiRuggiero D. *Dermatology for Advanced Practice Clinicians*. Lippincott Williams & Wilkins; 2021.
Bolognia JL, Schaffer JV, Duncan KO, Ko CJ. *Dermatology Essentials*. Saunders; 2014.

Alopecia Areata Treatment

- Intralesional Corticosteroids
- Superpotent topical corticosteroids
- Topical irritants (anthralin or tazarotene)
- Topical immunotherapy (squaric acid dibutyl ester)
- Pulsed oral corticosteroids
- FDA approved JAK inhibitors for severe cases
  - baricitinib
  - ritlecitinib

Bobonich M, Nolen M, Honaker J, DiRuggiero D. *Dermatology for Advanced Practice Clinicians*. Lippincott Williams & Wilkins; 2021.
Bolognia JL, Schaffer JV, Duncan KO, Ko CJ. *Dermatology Essentials*. Saunders; 2014.

Alopecia Areata Before and After

ILK 5 mg/cc q4 weeks x8 months





Androgenetic Alopecia

- Related to hormonal effects of dihydotestosterone (DHT) converted from testosterone by 5-alpha reductase
- Sensitivity of scalp hair to androgen hormones causes gradual miniaturization of hairs on th frontal/midline, vertex regions of men and midline/crown of women
  - Christmas tree pattern of widening in women
- May first become apparent with superimposed telogen effluvium (esp. women)
  - Should exclude hyperandrogenism in younger women

Bolognia JL, Schaffer JV, Duncan KO, Ko CJ. *Dermatology Essentials*. Saunders; 2014.

Androgenetic Alopecia

- Treatment
  - Topical minoxidil
  - Finasteride, Dutasteride (men, post-menopausal women)
  - Spironolactone (pre-menopausal women)
  - Oral minoxidil
  - PRP
  - Hair transplant

Bolognia JL, Schaffer JV, Duncan KO, Ko CJ. *Dermatology Essentials*. Saunders; 2014.





Androgenetic Alopecia

Telogen Effluvium

- Definable precipitating "stressful" event about 3 months prior precedes diffuse shedding leading to reduced density of hair on entire scalp
- Generally complete regrowth occurs in months to years
- Some women experience TE chronically without identifiable cause
- Treatment
  - Generally self-limiting
  - d/c offending drug, exclude thyroid abnormality
  - Possible causes: severe infection, severe illness, severe stress, post-surgical, hypothyroidism, crash liquid diets, drugs (retinoids, d/c of ocps, antidepressants, amphetamines, etc)

Bolognia JL, Schaffer JV, Duncan KO, Ko CJ. *Dermatology Essentials*. Saunders; 2014.

Lichen Planopilaris

- Scarring alopecia
- W>M
- Several foci of alopecia with loss of follicles and scarring centrally, peripheral follicles having central, keratotic plug and rim of inflammation
- Crown/vertex or midline or frontal hairline and eyebrows
- Treatment
  - Topical or intralesional corticosteroids
  - Oral doxycycline
  - Oral antimalarials
  - Oral retinoids
  - Severe- oral mycophenolate mofetil

Bolognia JL, Schaffer JV, Duncan KO, Ko CJ. *Dermatology Essentials*. Saunders; 2014.


LPP

Discoid Lupus Erythematosus (DLE)

- Scarring alopecia
- Type of CCLE
- Evaluate for SLE, although only small percentage will be diagnosed with SLE
- Circular lesions of erythema, atrophy, dilated/plugged follicles and scale as well as alopecia
  - Overtime central hypopigmentation and peripheral hyperpigmentation may appear
  - Can appear on face/ears

Bolognia JL, Schaffer JV, Duncan KO, Ko CJ. *Dermatology Essentials*. Saunders; 2014.

DLE Treatment

- Potent topical steroids and calcineurin inhibitors (usually not particularly effective)
- Intralesional steroids (3-10 mg/cc at periphery of active plaque)
- Antimalarials- hydroxychloroquine 200 mg BID
  - Can add quinacrine 100 mg daily if not controlled with hydroxychloroquine alone
- Retinoids- acitretin 25-50 mg daily, isotretinoin 40-80 mg daily
- Immunosuppressants- Methotrexate up to 25 mg weekly, mycophenolate mofetil 500 mg twice daily, dapsone 100-150 mg daily
- Thalidomide- 50-100 mg daily –for severe, recalcitrant cases only

Saavedra AP, Roh EK, Anar Mikailov. *Fitzpatrick's Color Atlas and Synopsis of Clinical Dermatology, 9/E*. McGraw Hill Professional; 2023.





DLE

Central Cicatricial Centrifugal Alopecia (CCCA)

- Scarring alopecia
- Most commonly observed in black women
- May be related to use of chemical hair relaxers or thermal relaxers
- Slowly progressive, centered on the crown/vertex and midline
- Symptoms may be mild or absent
- Treatment
  - Oral tetracycline plus potent topical corticosteroid
  - Severe- oral rifampin plus oral clindamycin and intralesional corticosteroids (if inflammatory component)

Bolognia JL, Schaffer JV, Duncan KO, Ko CJ. *Dermatology Essentials*. Saunders; 2014.

References

1. Alenazi SD. Atopic dermatitis: a brief review of recent advances in its management. *Dermatol Reports*. 2023;15(3):9678. Published 2023 May 23. doi:10.4081/dr.2023.9678
2. Bobonich M, Nolen M, Honaker J, DiRuggiero D. *Dermatology for Advanced Practice Clinicians*. Lippincott Williams & Wilkins; 2021.
3. Bolognia JL, Schaffer JV, Duncan KO, Ko CJ. *Dermatology Essentials*. Saunders; 2014.
4. Dinulos J. *Habif's Clinical Dermatology : A Color Guide to Diagnosis And Therapy*. 7th ed. Elsevier; 2021.
5. Gabros S, Nessel TA, Zito PM. Topical Corticosteroids. [Updated 2023 Jul 10]. In: StatPearls [Internet]. Treasure Island (FL): StatPearls Publishing; 2023 Jan-. Available from: https://www.ncbi.nlm.nih.gov/books/NBK532940/
6. High, W. A., & Prok, L. D. (2021). *Dermatology Secrets* (6th ed.). Elsevier.
7. James WD, Elston DM, Treat J, Rosenbach MA, Neuhaus I, George Clinton Andrews. *Andrews' Diseases of the Skin : Clinical Dermatology*. 13th ed. Elsevier; 2019.

References

8. Kim J, Kim BE, Leung DYM. Pathophysiology of atopic dermatitis: Clinical implications. *Allergy Asthma Proc*. 2019;40(2):84-92. doi:10.2500/aap.2019.40.4202
9. Konstantinou, M. P. (2023, August 14). *Benign familial pemphigus (Hailey-Hailey disease)*. StatPearls [Internet]. https://www.ncbi.nlm.nih.gov/books/NBK585136/
10. Kragballe K. Topical corticosteroids: mechanisms of action. *Acta Derm Venereol Suppl (Stockh)*. 1989;151:7-52
11. Saavedra AP, Roh EK, Anar Mikailov. *Fitzpatrick's Color Atlas and Synopsis of Clinical Dermatology, 9/E*. McGraw Hill Professional; 2023.