

Make Your Skin Crawl- Common Skin and Soft Tissue Infections and Infestations

Margaret McKernan DMSc, PA-C

Apex Dermatology

Cleveland, OH

Disclosures

- I have relevant relationships with ineligible companies to disclose within the past 24 months
  - Leo pharma advisory board
  - Johnson&Johnson advisory board

Objectives

- Identify various cutaneous skin infections of bacterial, viral, or parasitic origin
- Describe the underlying causes of skin infections
- Manage urgent infectious dermatological concerns
- Select appropriate treatment for cutaneous skin infections

Bacterial Infections

Abscesses, Furuncles, and Carbuncles

- Abscess- acute or chronic localized inflammation, associated with a collection of pus
  - Response to infection or foreign material
- Folliculitis- infection of hair follicle +/- pus in the ostium of the follicle
- Furuncles- acute, deep-seated, red, hot, tender nodule
  - Carbuncle- deeper infection involving of multiple, connecting abscesses arising in hair follicles
- Most common cause is *s. aureus*, most frequent presentation for MRSA
- Locations- face, neck, axillae, buttocks, perineum, and thighs
- Treatment
  - fluctuant lesions I&D
  - More severe- systemic antibiotics

Bolognia JL, Schaffer JV, Duncan KO, Ko CJ. *Dermatology Essentials*. Saunders; 2014.
Saavedra AP, Roh EK, Anar Mikailov. *Fitzpatrick's Color Atlas and Synopsis of Clinical Dermatology, 9/E*. McGraw Hill Professional; 2023.

Impetigo

- Very common, highly contagious bacterial infection
  - Most common face/extremities of children
  - Skin is eroded with overlying “honey-colored” crusts
  - Bullous variant
- Major organisms are *s. aureus* and *s. pyogenes* (group-A strep)
- Risk factors for infection- nasal carriage of *s. aureus* and breaks in epidermal barrier (e.g. atopic derm, arthropod bites, trauma, scabies)
- Treatment
  - Local wound care
  - Topical antibiotics (mupirocin)
  - Severe cases- oral antibiotics

Bobonich M, Nolen M, Honaker J, DiRuggiero D. *Dermatology for Advanced Practice Clinicians*. Lippincott Williams & Wilkins; 2021.
Bolognia JL, Schaffer JV, Duncan KO, Ko CJ. *Dermatology Essentials*. Saunders; 2014.



1. Pediatric Associates of Franklin. What Is Impetigo?; 2025. Available from: https://www.pediatricsoffranklin.com/resources-and-education/pediatric-care/what-is-impetigo

Ecthyma

- Ulceration with hemorrhagic crust that extends into the superficial dermis, i.e. is deeper than impetigo can heal with scarring
  - Often on lower extremities
- Risk factors: edematous limb, arthropod bites, and pre-existing ulceration
- Ecthyma gangrenosum- cutaneous infection that most commonly occurs in immunocompromised individuals with fulminant bacteremia
  - Most common cause *p. aeruginosa*
- Treatment- topical and oral antibiotics, I&D if indicated, broad-spectrum antibiotics for ecthyma gangrenosum

Bobonich M, Nolen M, Honaker J, DiRuggiero D. *Dermatology for Advanced Practice Clinicians*. Lippincott Williams & Wilkins; 2021.
Shah M, Crane JS. Ecthyma Gangrenosum. [Updated 2023 Jun 28]. In: StatPearls [Internet]. Treasure Island (FL): StatPearls Publishing; 2024 Jan-. Available from: https://www.ncbi.nlm.nih.gov/books/NBK534777/

Erysipelas

- Well-defined area of hot, indurated, bright erythema that is painful and tender
  - Occasionally superimposed pustules, vesicles, bullae, or areas of hemorrhagic necrosis
- Infection of the superficial dermis along the significant lymphatic involvement
  - Face, neck, leg
- Treatment
  - Oral antibiotics- penicillin VK, amoxicillin, cephalexin, cefadroxil

Bobonich M, Nolen M, Honaker J, DiRuggiero D. *Dermatology for Advanced Practice Clinicians*. Lippincott Williams & Wilkins; 2021.

Cellulitis

- Most common due to *s. pyogenes* or *s. aureus*
- Infection of the deep dermis and sometimes the subcutaneous fat
- Skin rubor (redness), calor (warmth), dolor (pain)
  - More ill-defined than erysipelas
  - May have skip areas, bullae, or become necrotic
- Often associated with systemic systems (fever, chills, malaise)
- Risk factors cellulitis of lower legs
  - Previous DVT, lymphedema, tinea pedis, previous cellulitis with lymphangitis

Bolognia JL, Schaffer JV, Duncan KO, Ko CJ. *Dermatology Essentials*. Saunders; 2014.

Cellulitis

- Treatment usually 7-10 days
- Choose antibiotics based on suspected bacteria
  - Strep- dicloxacillin or nafcillin
  - MSSA- cephalexin
  - MRSA- doxycycline
- Furuncle/Abscess
  - Incision/drainage without packing
- Address carrier state if infections are recurrent
  - Mupirocin nasal oint BID x14 days
  - Mupirocin cream BID to body folds
  - Chlorhexadine wash 1-2x weekly
  - Address fomites including sports equipment

Bolognia JL, Schaffer JV, Duncan KO, Ko CJ. *Dermatology Essentials*. Saunders; 2014.

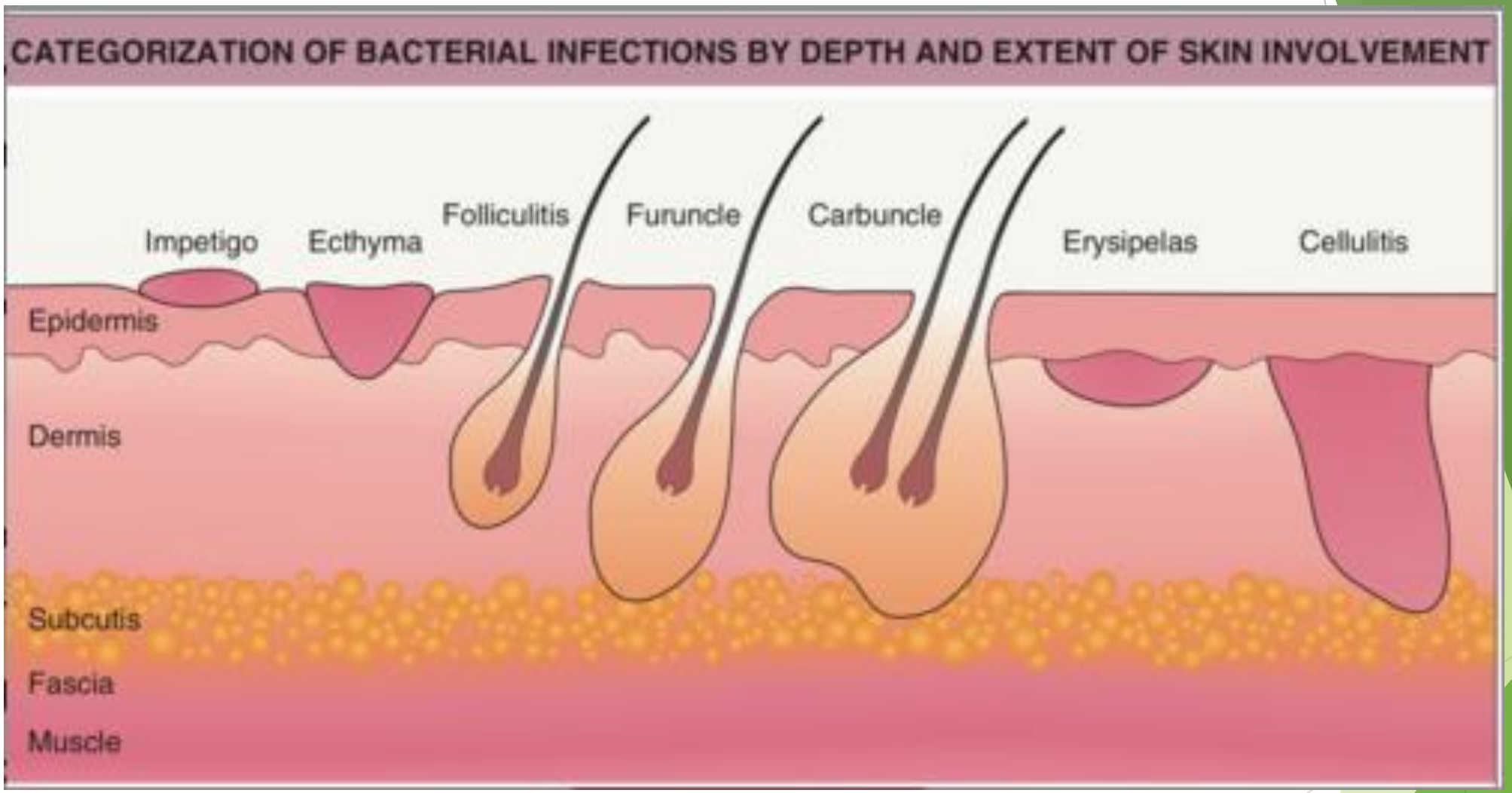

Bolognia JL, Schaffer JV, Duncan KO, Ko CJ. *Dermatology Essentials*. Saunders; 2014.

Green Nail Syndrome

- Blue-green to green-black discoloration of nail
  - Secondary to *p. aeruginosa*
  - Associated with onycholysis (moist environment)
- Treatment
  - Trim nails
  - Topical gentamicin
  - Oral fluroquinolone (ciprofloxacin)
    - 500-750 mg PO BID x4 weeks
  - Bleach soaks
    - 4:1 dilution water:bleach, a few minutes a day 2-3x daily for several weeks

Bolognia JL, Schaffer JV, Duncan KO, Ko CJ. *Dermatology Essentials*. Saunders; 2014.
Saavedra AP, Roh EK, Anar Mikailov. *Fitzpatrick's Color Atlas and Synopsis of Clinical Dermatology, 9/E*. McGraw Hill Professional; 2023.

Green Nail Syndrome



Dog/Cat Bites

- Infection of bite sites is common, esp. with streptococci, staphylococci, *Pasteurella multocida*, *Capnocytophaga canimorsus*, and anaerobes
  - Wound culture
- Examine wound for proximity to joints/tendons/bones, depth, foreign material, cosmetic implications, neurovascular status distal to wound
  - Radiographs (FB or bone involvement)
- Treatment- broad-spectrum antibiotics (e.g. amoxicillin-clavulanate)
  - Consider rabies vaccine and tetanus booster if indicated
- Most cases leave open to heal via secondary intention (due to infection risk)
  - Consult appropriate surgical service if management is unclear

Bolognia JL, Schaffer JV, Duncan KO, Ko CJ. *Dermatology Essentials*. Saunders; 2014.

Syphilis

- Caused by spirochete *treponema pallidum*
- Primary syphilis- characterized by one or more ulcers, usually anogenital
  - Chancre- painless, firm ulcers +/- regional lymphadenopathy
- Secondary Syphilis (hematogenous dissemination)- characterized by skin lesions that vary from macular to papulosquamous and from annular to granulomatous
  - Mucosal involvement is common
- Tertiary syphilis- can be latent for years- skin and mucous membranes as well as bones develop gummas
  - Cardiovascular syphilis and neurosyphilis major cause of death for those untreated
- Congenital syphilis
  - Primarily with secondary or tertiary syphilis

Bolognia JL, Schaffer JV, Duncan KO, Ko CJ. *Dermatology Essentials*. Saunders; 2014.

Syphilis

- Diagnosis- typically made with serology
- Dark-field microscopy
- Labs- RPR and VDRL, anti-t. pallidum antibodies (can take time to be positive average 3-6 weeks)
- A false positive VDRL can occur in pregnant women
  - Associated with APLS, SLE, lymphoma, drug abuse, infections
- Treatment
  - Benzathine penicillin, 2.4 millions units IM as a single dose
  - Reportable disease

Bolognia JL, Schaffer JV, Duncan KO, Ko CJ. *Dermatology Essentials*. Saunders; 2014.

Fungal Infections

Tinea (capitis, corporis, pedis, cruris, unguium)

- Erythematous, annular lesion with an active, scaly border
  - Superficial pustules or vesicles are possible
- Due to *trichophyton, microsporum, and epidermophyton*
- Transmission occurs via close contact with infected humans or domestic animals, occupational or recreational exposure (e.g. locker rooms), and contact with contaminated clothing, furniture, or brushes
- More common in adults
  - Except tinea capitis more common in children
- Diagnosis
  - KOH +/- fungal culture of skin scrapings or nail clippings

Bolognia JL, Schaffer JV, Duncan KO, Ko CJ. *Dermatology Essentials*. Saunders; 2014.

Dermatophytoses

- Tinea Capitis
  - Involving scalp
  - More common in children
- Tinea Corporis
  - Involves trunk, legs, arms, and/or neck (excludes feet, hands, groin)
- Tinea Pedis
  - Infection of the feet, “moccasin” distribution
- Tinea Cruris
  - Favors upper inner thighs and extend to lower abdomen and buttocks, often associated with tinea pedis
- Tinea Unguium
  - Involving the nail
  - More general term is onychomycosis includes other spp. like candida
  - Nail clipping
- Tinea Manuum
  - Associated with tinea pedis, can be unilateral “one hand two feet”

Bolognia JL, Schaffer JV, Duncan KO, Ko CJ. *Dermatology Essentials*. Saunders; 2014.





Ion A, Popa LG, Porumb-Andrese E, Dorobanțu AM, Tătar R, Giurcăneanu C, Orzan OA. A Current Diagnostic and Therapeutic Challenge: Tinea Capitis. Journal of Clinical Medicine. 2024; 13(2):376. https://doi.org/10.3390/jcm13020376
Mitchell G. Tinea Corporis.; 2020. Available from: https://dermnetnz.org/topics/tinea-corporis

Id Reactions and Tinea

- Id reactions can occur in setting of dermatophyte infections
- Dyshidrotic eczema-like papules and vesicles of the palms and fingers seen in association with tinea pedis
- Pruritic papules favoring the upper trunk in the setting of tinea capitis seen following initiation of appropriate therapy

Bolognia JL, Schaffer JV, Duncan KO, Ko CJ. *Dermatology Essentials*. Saunders; 2014.

Majocchi's Granuloma

- Erythematous papules or pustules within an area of tinea corporis
- Site of hair shaft invasion
- See in shaved areas or immunosuppressed patients

Bolognia JL, Schaffer JV, Duncan KO, Ko CJ. *Dermatology Essentials*. Saunders; 2014.

Dermatophytoses Treatment

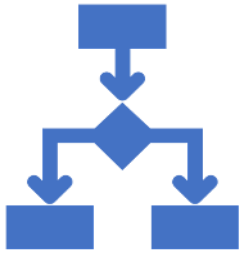

Topicals

Imidazoles (ketoconazole, clotrimazole, miconazole)

Allylamines (naftifine, terbinafine)

Naphthionates (tolnaftate)

Substituted pyridine (ciclopirox olamine)



Systemics

Duration depending on subtype being treated

Terbinafine 250 mg tab QD

Itraconazole 100 mg cap BID

Fluconazole (100, 150, 200 mg) tabs

Griseofulvin used in children/adolescents with tinea capitis

Saavedra AP, Roh EK, Anar Mikailov. *Fitzpatrick's Color Atlas and Synopsis of Clinical Dermatology, 9/E*. McGraw Hill Professional; 2023.





Candidiasis

- Most commonly due to *Candida albicans* or *C. tropicalis*
- Wide spectrum of clinical presentations
  - Mucosal candidiasis
    - Oral candidiasis (thrush)
    - White exudate resembling cottage cheese, other forms erythematous patches and adherent white plaques, glossitis, angular cheilitis, vulvovaginitis and balanitis
  - Cutaneous candidiasis
    - erosive, erythematous patch with satellite pustules in an intertriginous zone (inframammary, axillary, inguinal, beneath a pannus, on the scrotum, or diaper area)
- Predisposing factors
  - Diabetes mellitus, treatment with broad-spectrum antibiotics, inhaled corticosteroids, dentures, immunosuppression, common in otherwise healthy infants
- Diagnosis- culture or direct microscopy

Bolognia JL, Schaffer JV, Duncan KO, Ko CJ. *Dermatology Essentials*. Saunders; 2014.

Candidiasis Treatment

- Mucosal
  - Clotrimazole 10 mg troche 5x daily
  - Nystatin suspensions: 4-6 ml swish and swallor 4x daily, 1 ml 4x daily infants
  - Severe or recalcitrant: oral fluconazole 200 mg PO daily 1 then 100-200 mg daily for 7-14 days after clinical resolution
- Cutaneous
  - Prevention- keep areas dry, wash with benzoyl peroxide, use antifungal powder, antiperspirant gel or spray
  - Ketoconazole 2% cream BID
  - Fluconazole 50-100 mg PO QD x14 days OR fluconazole 150 mg PO weekly x2-4 weeks
  - Chronic: fluconazole 400-800 mg PO QD x4-6 months and may require lifelong suppression with 200 mg PO QD

Bolognia JL, Schaffer JV, Duncan KO, Ko CJ. *Dermatology Essentials*. Saunders; 2014.
Saavedra AP, Roh EK, Anar Mikailov. *Fitzpatrick's Color Atlas and Synopsis of Clinical Dermatology, 9/E*. McGraw Hill Professional; 2023.

Viral Infections

Molluscum Contagiosum

- Firm, skin-colored to pink papules or papulonodules with a waxy surface and central umbilication
  - Predilection for skin folds
- Common, caused by a poxvirus
- Spread by skin-to-skin contact > fomites (towels)
- More common in children, but can be sexually transmitted in adults
- Eczematous dermatitis can occur surrounding the MC
- Resolve spontaneously over months to years
- "BOTE" sign- lesional inflammatory response prior to spontaneous resolution of molluscum contagiosum lesions

Bolognia JL, Schaffer JV, Duncan KO, Ko CJ. *Dermatology Essentials*. Saunders; 2014.
Sil A, Bhanja DB, Chandra A, Biswas SK. BOTE sign in molluscum contagiosum. *BMJ Case Rep*. 2020;13(9):e239142. Published 2020 Sep 16. doi:10.1136/bcr-2020-239142



Available from: https://dermnetnz.org/imagedetail/19105-molluscum-contagiosum

Molluscum Contagiosum

- Treatment
  - No treatment (not recommended)
  - Destruction of the lesions
    - Cryotherapy, electrodessication
    - Extraction, curettage
    - Heating pad method
  - Topicals
    - cantharidin, imiquimod, retinoids
  - New FDA-approved cantharidin 0.7% solution

Bolognia JL, Schaffer JV, Duncan KO, Ko CJ. *Dermatology Essentials*. Saunders; 2014.

Herpes Simplex Virus (HSV)

- Recurrent vesicular lesions of the oral-labial (HSV1>HSV2) and genital skin (HSV2>HSV1)
- Primary infection
  - Onset 3-7 days after exposure
  - Small round grouped vesicles on erythematous base, painful or burning, may ulcerated and form hemorrhagic crusting
  - Generalized prodrome- fever, malaise, lymphadenopathy
- Reactivation
  - Localized prodrome- burning, tingling, pain, pruritus, tenderness
  - Similar outbreak, but less severe, fewer vesicles, and shorter duration
  - can occur spontaneously or due to stimulus (e.g. stress, fever, trauma, sun exposure)
- Transmission can occur during both symptomatic and asymptomatic periods of viral shedding

Bolognia JL, Schaffer JV, Duncan KO, Ko CJ. *Dermatology Essentials*. Saunders; 2014.

HSV

Herpetic whitlow

- HSV infection of the digits, most often seen in children

Eczema herpeticum

- Widespread eruption of HSV (in association with condition that disrupt the epidermal barrier (AD, Darier's, burns, etc)
- Punched out erosions with a scalloped border

Treatment

- Topical acyclovir 5% ointment (minimal efficacy) 6x daily
- Oral Acyclovir 400 mg TID or 200 mg 5x daily x7-10 days
- Oral Valacylovir 1g BID x7-10 days (preferred due to bioavailability)
- Oral Famciclovir 250 mg TID x5-10 days (preferred due to bioavailability)

Bolognia JL, Schaffer JV, Duncan KO, Ko CJ. *Dermatology Essentials*. Saunders; 2014.
Saavedra AP, Roh EK, Anar Mikailov. *Fitzpatrick's Color Atlas and Synopsis of Clinical Dermatology, 9/E*. McGraw Hill Professional; 2023.

Varicella-Zoster Virus (VZV)

- Primary Varicella Infection (chickenpox)
  - Infects 98% of adults
- Characterized by disseminated pruritic vesicles
  - “Dew drop on a rose petal”
  - Establishes lifelong infection in sensory ganglia
- Can reactivate years later in dermatomal pattern (i.e. herpes zoster)
- VZV vaccine has reduced the incidence of varicella and herpes zoster
- Treatment
  - Supportive- antihistamines, anti-itch creams
  - If given within 24 hours of onset, can consider oral antivirals

Bolognia JL, Schaffer JV, Duncan KO, Ko CJ. *Dermatology Essentials*. Saunders; 2014.

Herpes Zoster Virus (HZV)

Reactivation of VZV is herpes zoster (shingles)

- Incidence, severity, and risk increase significantly with age
- Sensory neuritis and painful neuralgia followed by dermatomal vesicular eruption
- Exposure of a susceptible person to an individual with chickenpox or zoster can lead to primary varicella but not zoster
- Characterized by papules, vesicles, pustules, and crusts on an erythematous edematous base

Treatment

- Early antiviral treatment is key (within 72 hours of onset)
  - Valacyclovir 1 g q8hr x7 days, famciclovir 500 mg q8hr x7 days, acyclovir 800 mg 5x daily x7 days
  - Vaccination reduces incidence by 51%

Saavedra AP, Roh EK, Anar Mikailov. *Fitzpatrick's Color Atlas and Synopsis of Clinical Dermatology, 9/E*. McGraw Hill Professional; 2023.

Herpes Zoster Virus Complications

- Post-herpetic neuralgia and post-herpetic itch
  - Can last months to years
  - Treatment- gabapentin, tricyclic antidepressants (e.g. amitriptyline), topical capsaicin or lidocaine, ibuprofen, avoid opioids if possible (ineffective, may worsen condition)
- Ocular Involvement
  - Due to VZV reactivation in the first division of the trigeminal nerve (V1), occurs about 10% of people with VZV
  - Hutchinson's sign- presence of vesicles at the tip, side, or bridge of nose
  - Ophthalmology evaluation
- Ramsay-Hunt Syndrome
  - Reactivation of VZV in geniculate ganglia
  - Vesicles in ear canal, tongue, and/or hard palate
  - May have ear pain, facial nerve paralysis, taste loss, tinnitus hearing loss, vertigo
  - Referral to otolaryngology

Bolognia JL, Schaffer JV, Duncan KO, Ko CJ. *Dermatology Essentials*. Saunders; 2014.

Dew Drop on a Rose Petal





HZV

Human Papillomaviruses



HPV comprises a large group of at least 200 genotypes of DNA viruses that infect the skin and mucosa



Different genotypes cause different skin lesions



Clinical variants differ as to anatomic location, morphology, histopathology and HPV subtype



Correlation of clinical and histopathologic finding important for Bowenoid papulosis and verrucous carcinoma

Bolognia JL, Schaffer JV, Duncan KO, Ko CJ. *Dermatology Essentials*. Saunders; 2014.

Verruca Vulgaris (common wart)

- Hyperkeratotic exophytic or dome-shaped papules or plaques with punctate black dots (thrombosed capillaries)
  - May need to pare to see
- Spread via person-to-person contact or contact with contaminated objects
- Prevalence 20% in schoolchildren
- About 1/3 will regress in 1-2 years
- Any site, but most common on hands and other places prone to trauma
- Other types include palmar/plantar warts, flat warts, oral warts

Bolognia JL, Schaffer JV, Duncan KO, Ko CJ. *Dermatology Essentials*. Saunders; 2014.

Verruca Treatment

Can be difficult to eradicate and may spontaneously resolve

Clinician-administered

- Cryotherapy
- Curettage and electrodessication
- Cantharidin
- Intralesional immunotherapy
- Laser

Patient/parent administered topical therapy

- Salicylic acid, imiquimod, 5-flurouracil, topical retinoid +/- occlusion

Adjunct options

- Oral cimetidine
- Oral retinoid

Bolognia JL, Schaffer JV, Duncan KO, Ko CJ. *Dermatology Essentials*. Saunders; 2014.

Filiform verruca



Hand-Foot-and-Mouth Disease

- Caused by coxsackievirus
- Presents with fever and sore mouth
- Mouth- rapidly ulcerating vesicles surrounded by red areola on buccal mucosa, tonge, soft palate, and gingiva
- Hands/feet- asymptomatic red papules that become small grey vesicles surrounded by red halo
- Affects children age 6 months to 10 years old

James WD, Elston DM, Treat J, Rosenbach MA, Neuhaus I, George Clinton Andrews. *Andrews' Diseases of the Skin : Clinical Dermatology.* 13th ed. Elsevier; 2019.

Condyloma Acuminata

- Involve primarily anogenital region
- Range from discrete, sessile, smooth-surfaced papillomas to large cauliflower-like lesions
- Skin-colored to pink to brown
- If present in children, esp. those >3 y/o, consider sexual abuse
- Other high-risk HPV subtypes in anogenital region
  - Bowenoid papulosis, SCC in situ, verrucous carcinoma
- Treatment- similar to verrucae vulgaris except excision of high-risk subtypes

Bolognia JL, Schaffer JV, Duncan KO, Ko CJ. *Dermatology Essentials*. Saunders; 2014.

Cutaneous manifestations of HIV

- Exanthem of primary HIV infection (acute retroviral syndrome)
  - Follows incubation period of 3-6 weeks
  - Morbilliform eruption appears in the setting of peak viremia along with orogenital ulcerations and fever, fatigue, headache, pharyngitis, arthralgia, myalgia, GI symptoms
  - Eruption lasts 4-5 days, constitutional symptoms may last days to months
  - Diagnosis- viral RNA by PCR and/or p24 antigen in the plasma or assays for anti-HIV-1 antibodies
- Other signs are dermatologic conditions that are exacerbated or recalcitrant to treatment
  - Consider immunocompromised state

Bolognia JL, Schaffer JV, Duncan KO, Ko CJ. *Dermatology Essentials*. Saunders; 2014.

Kaposi's Sarcoma

- Multifocal systemic disease; extramucocutaneous sites include GI track, lymph nodes, and lungs
- Skin findings- pink to dark violet patches and plaques, which can become nodular
- 4 main variants
  - Older men from the Mediterranean basin or of Ashkenazi Jewish decent with lesions on the lower extremities
  - African endemic
  - Iatrogenic/immunocompromised
  - AIDS-related epidemic
- Associated with HHV-8 infection
- Diagnosis- skin biopsy
- Treatment- refer to oncology (radiotherapy, chemotherapy, immunotherapy)

Bolognia JL, Schaffer JV, Duncan KO, Ko CJ. *Dermatology Essentials*. Saunders; 2014.





Courtesy of Shannon McKeen, DO

Monkeypox

- Zoonotic illness caused by the monkeypox virus (Orthopoxvirus in the same genus as the variola, vaccinia, and cowpox viruses)
- First described in 1958 among monkeys shipped from Singapore to Denmark
- WHO declared monkeypox a Public Health Emergency of International Concern in 2022
- Unprecedented global spread of the disease outside previously endemic countries in Africa
- Recent outbreak primarily associated with close intimate contact (including sexual activity)
  - most cases have been diagnosed among men who have sex with men
- Incubation period ranges from 7 days to 10 days
- Presentation
  - systemic illness that includes fever and myalgia
  - characteristic rash- papules that evolve to vesicles, pustules, and crusts in the genital, anal, or oral regions and often involve the mucosa.

Mitjà, O., Ogoina, D., Titanji, B. K., Galvan, C., Muyembe, J.-J., Marks, M., & Orkin, C. M. (2023). Monkeypox. *The Lancet*, *401*(10370), 60–74. https://doi.org/10.1016/s0140-6736(22)02075-x

Monkeypox

- Mostly self-limited illness- between 1% and 13% require hospital admission (for treatment or isolation), and the case-fatality rate is less than 0-1%.
- Diagnosis- presence of Orthopoxvirus DNA in PCRs from lesion swabs or body fluids.
- Complications that require medical treatment occur in up to 40% of patients
  - Rectal pain, odynophagia, penile edema, and skin and anorectal abscesses
  - Consider antivirals (tecovirimat), antibacterials, pain control if indicated
- Post-exposure or pre-exposure prophylaxis with the non-replicating modified vaccinia Ankara (high-risk persons)

Mitjà, O., Ogoina, D., Titanji, B. K., Galvan, C., Muyembe, J.-J., Marks, M., & Orkin, C. M. (2023). Monkeypox. *The Lancet*, *401*(10370), 60–74. https://doi.org/10.1016/s0140-6736(22)02075-x

Parasitic Infections

Pediculosis Capitis (Head lice)

- *Pediculus capitis*
  - Blood-sucking, six-legged insect that lays its eggs near the base of the hairs on the scalp
  - Casing remains after the eggs hatch and migrates outward with the growth of the hair shaft
  - Transmission person to person or via fomites (hats, brushes)
  - Erythema, scaling, and excoriations in addition to lice and eggs
  - Diagnosis- visual, clinical, can do microscopic inspection

Bolognia JL, Schaffer JV, Duncan KO, Ko CJ. *Dermatology Essentials*. Saunders; 2014.

Pediculosis Pubis (Crab Lice)

- *Phthirus pubis*
  - blood-sucking, six-legged insect that lives on the terminal hairs of the pubic region, beard, eyelashes, axillae, and perianal region
  - “crab lice”- shorter and broader than head/body lice
  - Transmission via direct contact (sexual) or occasionally fomites (towels, bedding, clothing)
  - Check patient for other STIs
  - Hemorrhagic crusts, perifollicular erythema, and macula caerulea (asymptomatic slate-gray to blue macules on the trunk and thighs) may be seen as well

Bolognia JL, Schaffer JV, Duncan KO, Ko CJ. *Dermatology Essentials*. Saunders; 2014.

Pediculosis Corporis (Body Lice)

- *Pediculus humanus*
  - Bloodsucking 6-legged insect
  - Associated with overcrowding, poor hygiene, poverty, wars, and natural disasters
  - Severe pruritus is common
  - Body lice and nits are primarily found in clothing seams
  - Incinerate clothing and bedding if possible, otherwise wash and dry with high heat

Bolognia JL, Schaffer JV, Duncan KO, Ko CJ. *Dermatology Essentials*. Saunders; 2014.

Lice Treatment

- Topical
  - Permethrin 5% cream
  - Spinosad 0.9% topical suspension
  - Ivermectin 0.5% lotion
- Oral
  - Ivermectin (3 mg tabs)
  - Levamisole
  - Albendazole

Bolognia JL, Schaffer JV, Duncan KO, Ko CJ. *Dermatology Essentials*. Saunders; 2014.
Saavedra AP, Roh EK, Anar Mikailov. *Fitzpatrick's Color Atlas and Synopsis of Clinical Dermatology, 9/E*. McGraw Hill Professional; 2023.

Scabies

- Infection by *Sarcoptes Scabiei* var. *hominis*
  - Mite that lives in the stratum corneum of the skin
- Transmission direct contact with infected person, less frequently infected clothing
- Incubation can be up to 6 weeks
- Asymptomatic infestation is not uncommon, “carriers” of scabies
- If symptomatic- pruritus is severe, worse at night or after hot shower
- Skin lesions variable- erythematous papules with scale-crust, small patches of eczema, excoriations, vesicles, nodules
  - Classic burrow- a thread-like , grayish-white wavy 1-10 cm linear structure, favors acral sites

Bolognia JL, Schaffer JV, Duncan KO, Ko CJ. *Dermatology Essentials*. Saunders; 2014.

Scabies

- Diagnosis- Clinical confirmation
  - Mineral oil examination of skin scrapings
- Treatment
  - Permethrin 5% cream- Two overnight applications 1 week apart, neck down
    - Immunocompromised, infants, elderly need to include face/scalp
  - New FDA-approved scabies treatment- spinosad 0.9% suspension
    - Only one application required
  - Oral ivermectin (200-400 mcg/kg given on days 1 and 8) – good for when large number of individuals affected (i.e. nursing home)
  - All clothing and bedding washed in hot water, dried on high heat, stored in bag for 10 days
  - All family members and close contacts should be treated simultaneously, even if asymptomatic
- Resolution
  - Pruritus and cutaneous lesions can take another 2-4 weeks to resolve after treatment
  - One treatment has occurred, can give topical corticosteroids for pruritus
  - Crusted scabies- more severe, may require several rounds of treatment

Bolognia JL, Schaffer JV, Duncan KO, Ko CJ. *Dermatology Essentials*. Saunders; 2014.





Available from: https://dermnetnz.org/imagedetail/24288-scabies

Leishmaniasis

Three major forms

Cutaneous	Mucocutaneous	Visceral (liver, spleen)

Vector- sandfly, caused by more than 15 different species of *Leischmania*

Seen worldwide, but endemic in areas of Asia, Africa, Latin America, and the Mediterranean basin

Bolognia JL, Schaffer JV, Duncan KO, Ko CJ. *Dermatology Essentials*. Saunders; 2014.

Cutaneous Leishmaniasis

- Affects skin only and is commonly a papule that expands and ulcerates
  - Pattern may be sporotrichoid
  - Lesions may heal spontaneously
- For isolated lesion, conservative therapy (observation, heat, cryo) or topical paromycin
- Extensive cases: IV or IM pentavalent antimony (sodium stibogluconate, meglumine antimonate), oral miltefosine
- Reference CDC and WHO for additional information

Bolognia JL, Schaffer JV, Duncan KO, Ko CJ. *Dermatology Essentials*. Saunders; 2014.

Cutaneous Larva Migrans

- Secondary to larvae of animal hookworms
- Occurs most commonly in tropical/subtropical areas and southwestern USA
- Larvae of infected soil, including sand, penetrate the skin
- Pruritic, inflamed serpiginous tracks are produced by migrating organizations about 1-2 cm a day
- Most common lower extremities- feet/buttocks walking around on beach
- Treatment- disease is self-limited, but can consider oral albendazole or ivermectin, topical thiabendazole for localized disease

Bolognia JL, Schaffer JV, Duncan KO, Ko CJ. *Dermatology Essentials*. Saunders; 2014.

Borreliosis

Most common USA (northeast, upper Midwest, west coast), Scandinavia and central Europe

Hosts- white-footed mice and white-tailed deer

Can be localized to the site of the bite of an infected *Ixodes* tick (several species transmit disease)

May become disseminated

Bolognia JL, Schaffer JV, Duncan KO, Ko CJ. *Dermatology Essentials*. Saunders; 2014.

Erythema migrans

- Cutaneous manifestation of the earlier stages of infection with *Borrelia burgdorferi* spirochetes
- At the site of tick bite, usually after 1-2 weeks an annular, erythematous patch or plaque appears tat expands over days to weeks to reach a diameter of at least 5 cm, with central clearing
  - “bull’s-eye appearance”
- Primary lesions often are asymptomatic and spontaneously resolve (without treatment) within 6 weeks
- Transmission usually requires attachment of the infected tick for over 24 hours
  - Untreated can lead to arthritis, Bell’s palsy, and atrioventricular heart block
- Seen in 60-90% of those diagnosed with Lyme borreliosis

Bolognia JL, Schaffer JV, Duncan KO, Ko CJ. *Dermatology Essentials*. Saunders; 2014.

Borreliosis Treatment

Early localized disease- doxycycline 100 mg PO BID x14-21 days

Early disseminated disease, mild chronic disease, or cranial nerve palsy- doxycycline 100 mg PO BID x14-28 days

Severe chronic disease or meningitis- ceftriaxone 2 g IV QD x14-28 days

Consider amoxicillin 500 mg PO q8 hours x14-28 days in children or pregnant women

Bolognia JL, Schaffer JV, Duncan KO, Ko CJ. *Dermatology Essentials*. Saunders; 2014.

Swimmer's Itch

- Worldwide, endemic to the Great Lakes
- Acute, pruritic papular eruption at the sites of cutaneous penetration (exposed skin) by *cercariae* larvae of schistosomes whose usual hosts are birds and small mammals
- Humans are "dead-end" hosts
  - Penetrate, cause inflammatory response, and die w/o invading tissue further
- Self-limited 7-10 days
  - Topical or systemic corticosteroids in more severe cases

Bolognia JL, Schaffer JV, Duncan KO, Ko CJ. *Dermatology Essentials*. Saunders; 2014.
Saavedra AP, Roh EK, Anar Mikailov. *Fitzpatrick's Color Atlas and Synopsis of Clinical Dermatology, 9/E*. McGraw Hill Professional; 2023.

Tungiasis

- *Tunga penetrans*
  - Burrowing flea
  - 1-2 cm nodule with surrounding erythema develops, may be multiple lesions
  - Pregnant female flea burrows into the skin esp. feet of those who do not wear shoes or only flip-flops
  - Endemic to central and south America, Caribbean islands, Africa, Pakistan, and India
  - Remove the flea, tetanus prophylaxis
  - Prevention- wear shoes and avoid sitting on sandy beaches in endemic areas

Bolognia JL, Schaffer JV, Duncan KO, Ko CJ. *Dermatology Essentials*. Saunders; 2014.

Insect Bites (bed bugs, fleas, fire ants, spiders, etc.)

- Bite can lead to local cutaneous reaction whose intensity can vary depending on the individuals level of sensitivity
  - Typically 2-8 mm erythematous, urticarial papules in an exposed area, often multiple and grouped
  - Secondary changes: excoriations, vesicles, bullae possible
- Reactions typically resolve over 5-10 days
- Post-inflammatory hyperpigmentation is common
- Secondary infection is a possible complication
- Anaphylaxis with urticaria and angioedema more commonly due to stings from hymenopterids (bees, wasps, hornets, fire ants)
- Especially in children- bites can trigger papular urticaria with edematous papules more widespread and longer lasting

Bolognia JL, Schaffer JV, Duncan KO, Ko CJ. *Dermatology Essentials*. Saunders; 2014.

Insect Bites



Prevention

Insect repellents (DEET)

Mosquito netting

Protective or permethrin-treated clothing

Exterminator if indicated



Treatment

Anti-itch creams

Topical corticosteroids

Intralesional corticosteroids

Bolognia JL, Schaffer JV, Duncan KO, Ko CJ. *Dermatology Essentials*. Saunders; 2014.

References

1. Bobonich M, Nolen M, Honaker J, DiRuggiero D. *Dermatology for Advanced Practice Clinicians*. Lippincott Williams & Wilkins; 2021.
2. Bolognia JL, Schaffer JV, Duncan KO, Ko CJ. *Dermatology Essentials*. Saunders; 2014.
3. Dinulos J. *Habif's Clinical Dermatology : A Color Guide to Diagnosis And Therapy*. 7th ed. Elsevier; 2021.
4. James WD, Elston DM, Treat J, Rosenbach MA, Neuhaus I, George Clinton Andrews. *Andrews' Diseases of the Skin : Clinical Dermatology.* 13th ed. Elsevier; 2019.
5. Mitjà, O., Ogoina, D., Titanji, B. K., Galvan, C., Muyembe, J.-J., Marks, M., & Orkin, C. M. (2023). Monkeypox. *The Lancet*, *401*(10370), 60–74. https://doi.org/10.1016/s0140-6736(22)02075-x
6. Saavedra AP, Roh EK, Anar Mikailov. *Fitzpatrick's Color Atlas and Synopsis of Clinical Dermatology, 9/E*. McGraw Hill Professional; 2023.
7. Shah M, Crane JS. Ecthyma Gangrenosum. [Updated 2023 Jun 28]. In: StatPearls [Internet]. Treasure Island (FL): StatPearls Publishing; 2024 Jan-. Available from: https://www.ncbi.nlm.nih.gov/books/NBK534777/
8. Sil A, Bhanja DB, Chandra A, Biswas SK. BOTE sign in molluscum contagiosum. *BMJ Case Rep*. 2020;13(9):e239142. Published 2020 Sep 16. doi:10.1136/bcr-2020-239142