

# I am Not Spineless...

## Lumbar Spine Evaluation and Treatment

### Skin, Bones, Hearts, & Private Parts

Dr. Chris Hemmer, DNP, ANP, ONP-C, FAANP  
Assistant Professor Saint Louis University School of Nursing  
V.P. Piper Spine Care



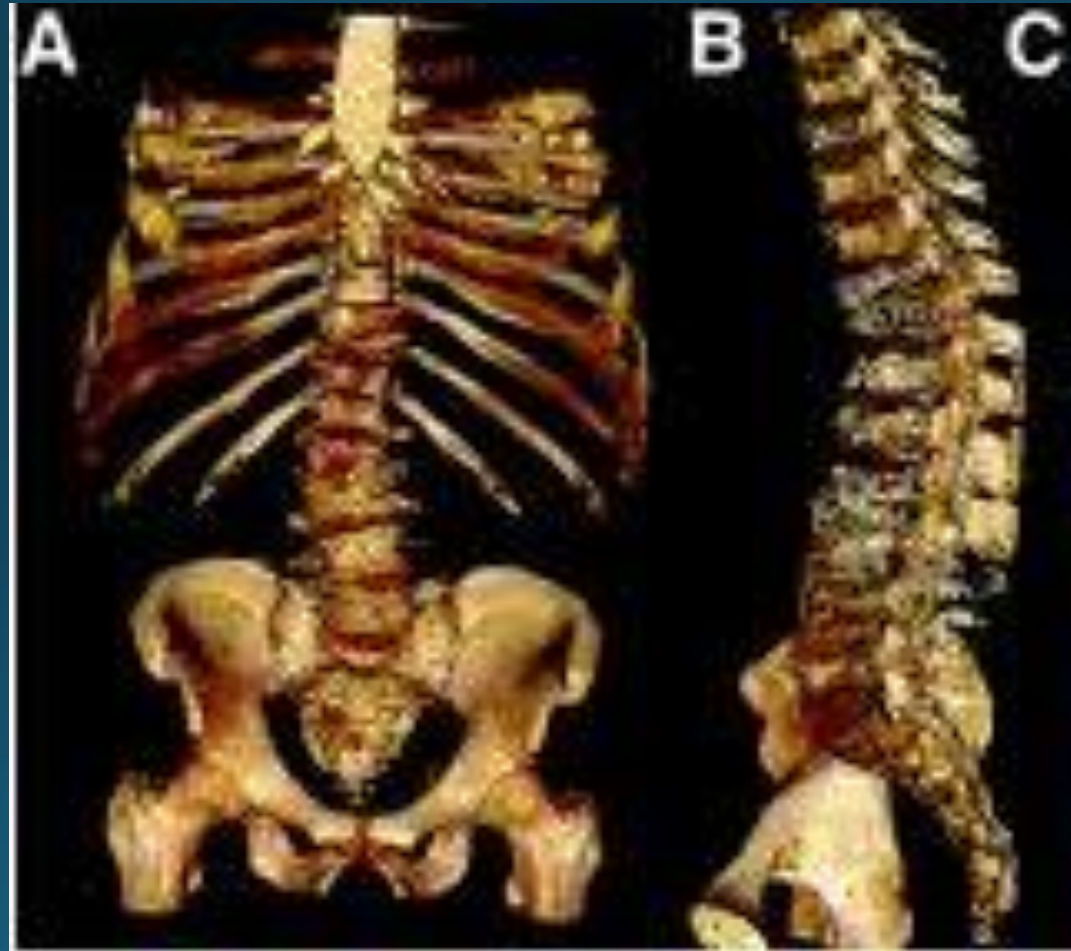I Have No Financial Disclosures



# Objectives

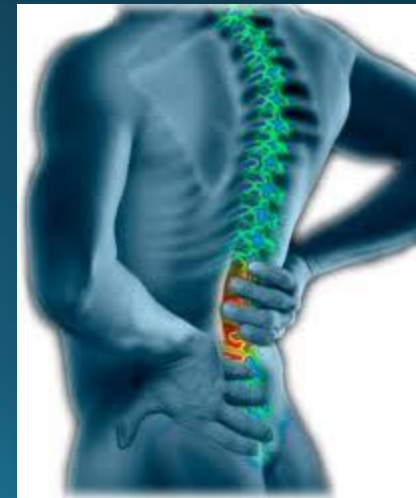- Demonstrate knowledge of lumbar spine anatomy with case presentation
- Be able to describe what a pathological reflex is and give an example
- List some of the red flags discussed in the presentation
- Describe some of the treatment options for patient with lumbar spine pathology

# Lumbar Spine



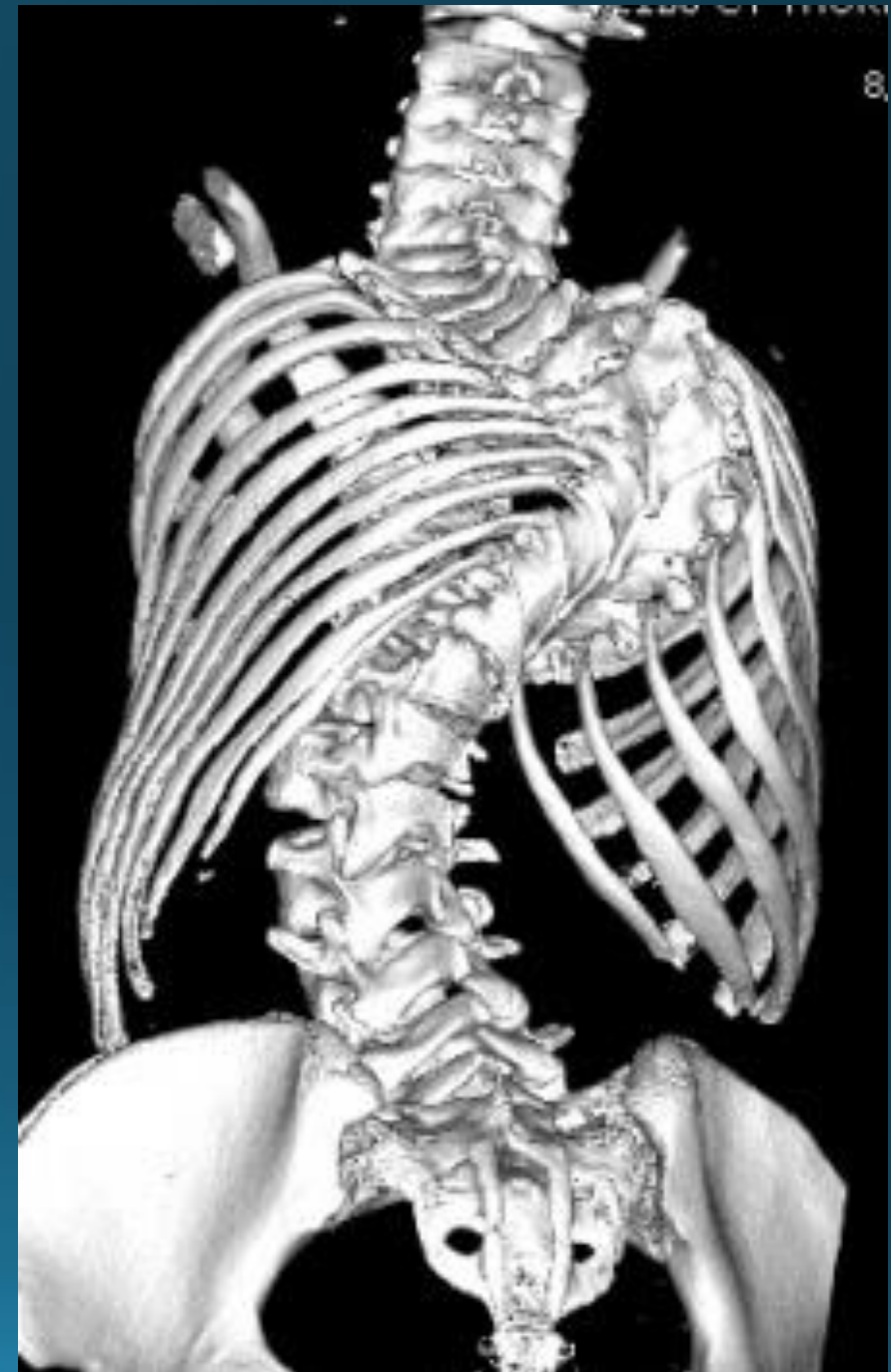## Epidemiology of Low Back Pain

- Approximately 80-85% of the population will have some form of back pain in their lifetime.
- The majority of those with back pain lasting less than 12 weeks is considered acute/ subacute. Pain lasting greater than 12 weeks is considered chronic
- Most patients that are affected by low back pain are considered non-specific and is self resolving. Some thoughts are that it is musculoskeletal in nature
- Risk factors include smoking, obesity, age, female, sedentary work, physical demanding work (this is debatable in the literature), low level education, job dissatisfaction, litigious issues such as work comp, and psychiatric problems such as chronic depression or somatization disorders

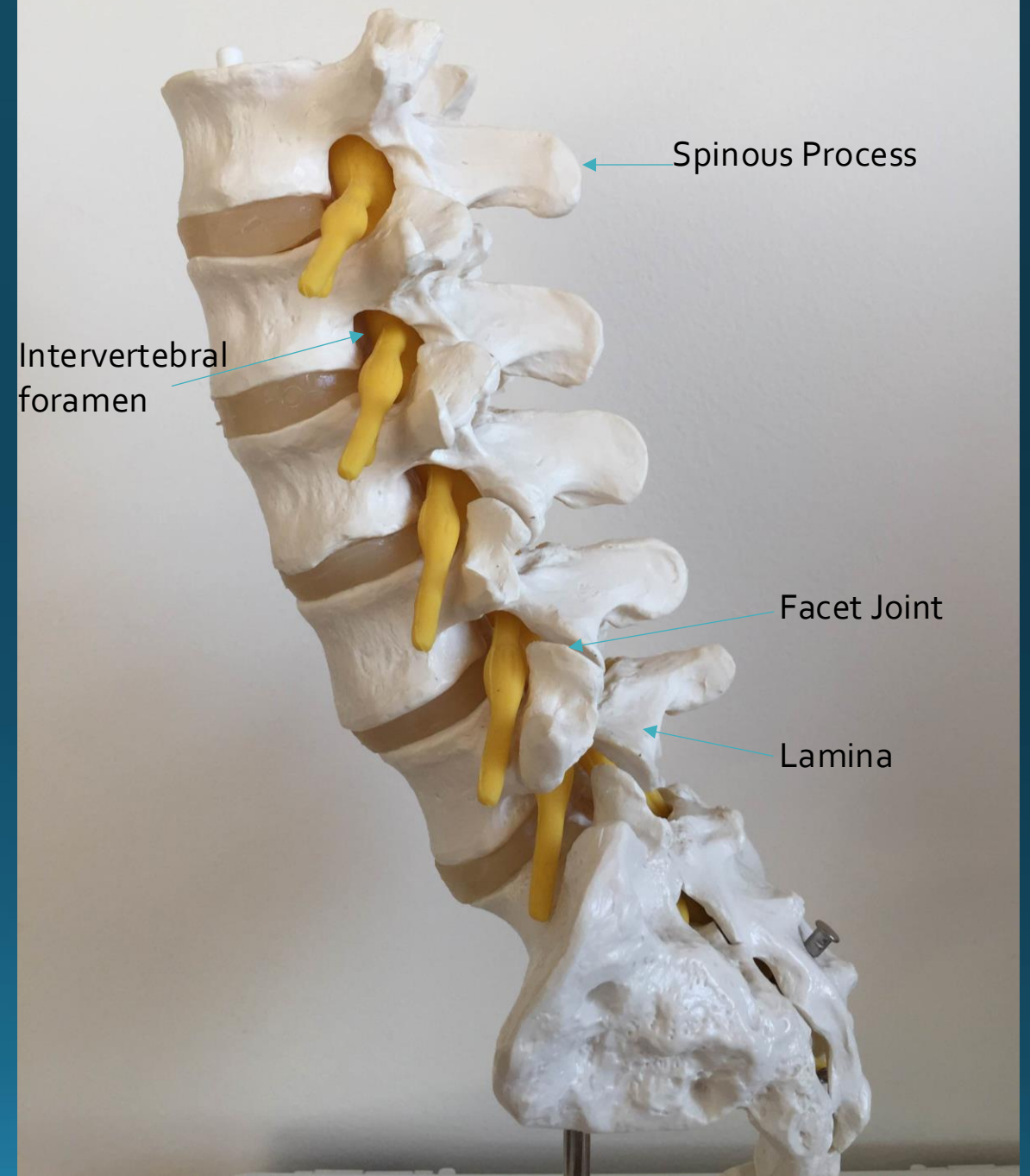
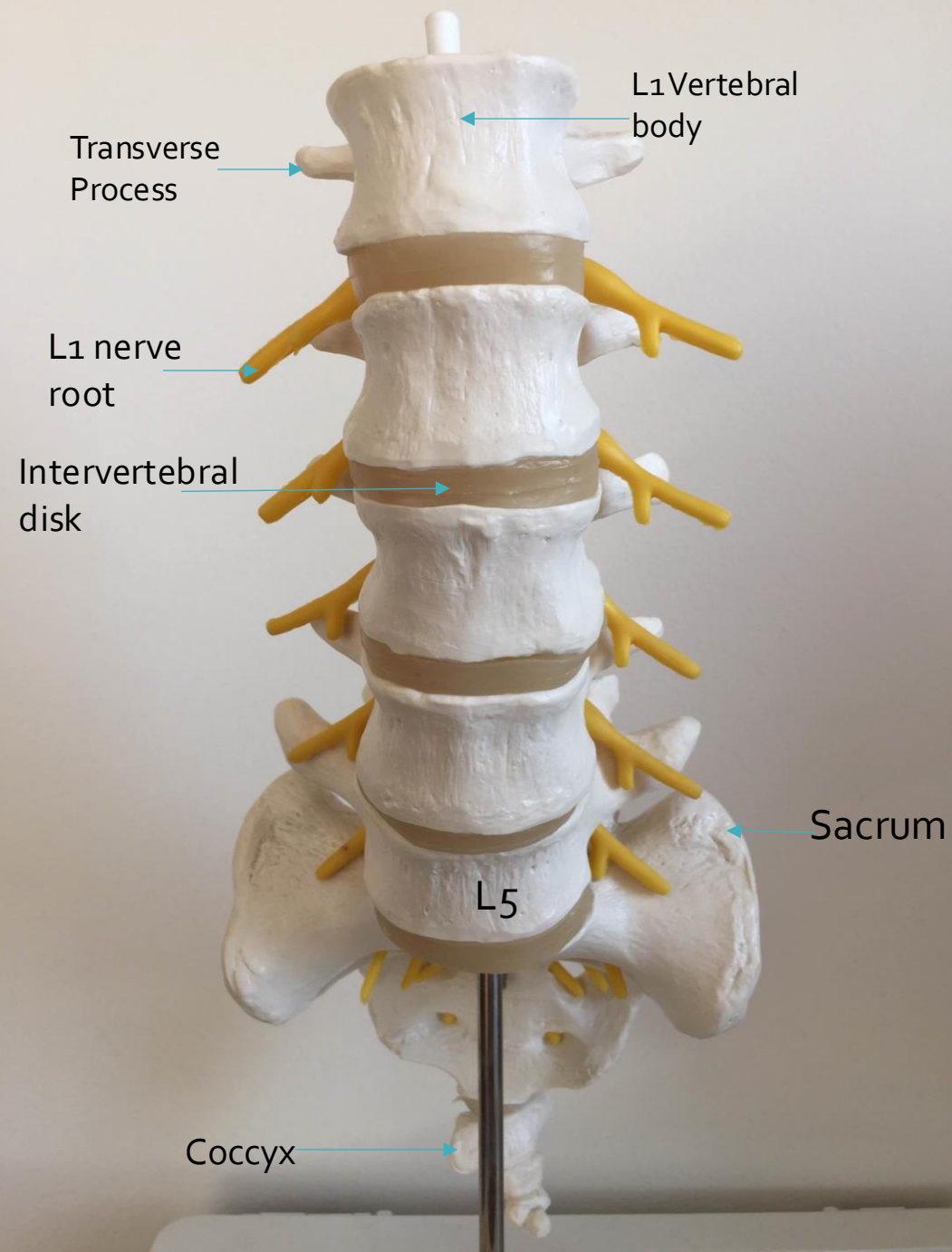


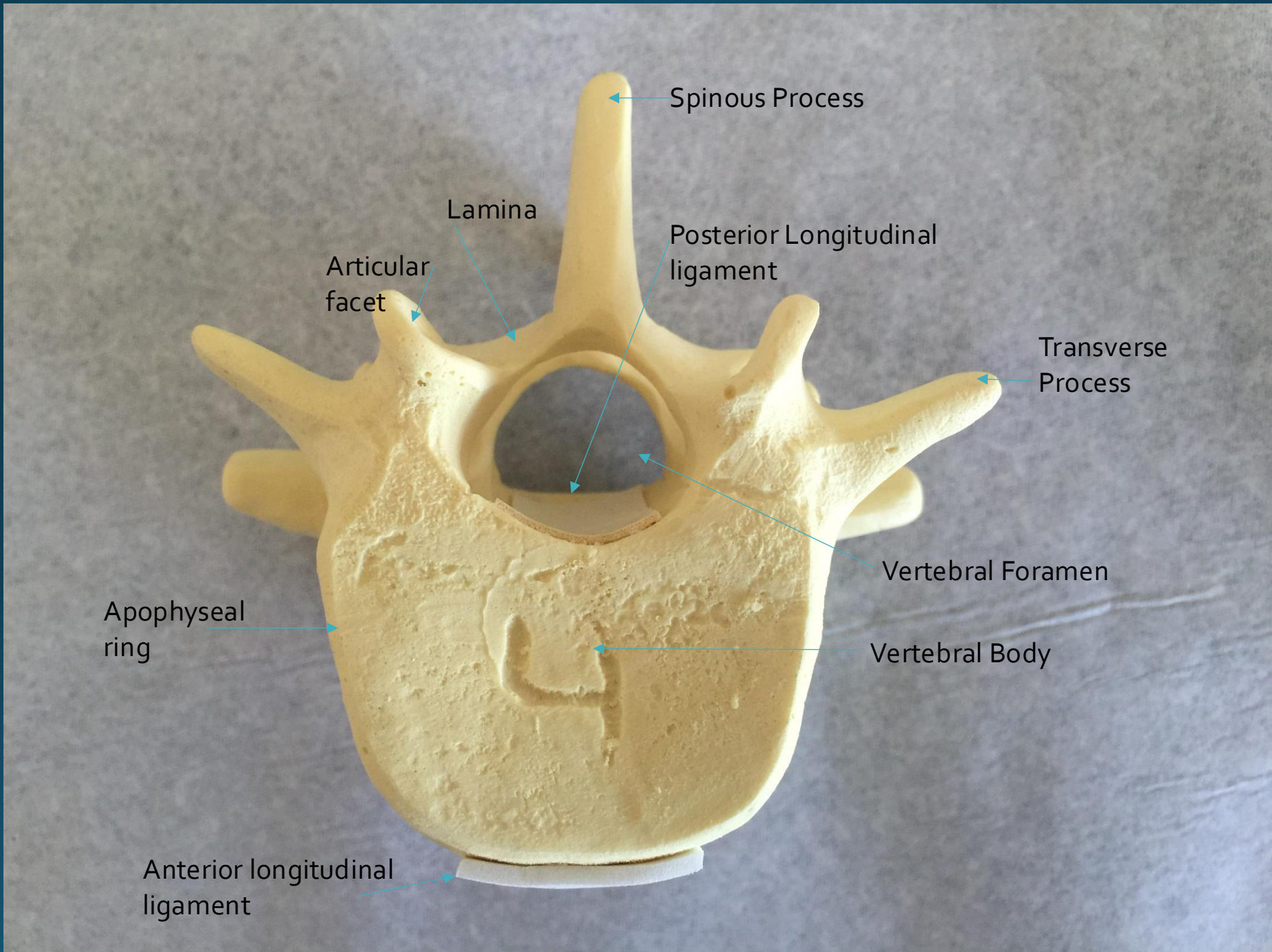
# Anatomy

- The lumbar spine is made of 5 vertebral bodies and rest on the sacrum at the L5-S1 segment
- Each vertebrae is made of a vertebral body, pedicle, transverse process, spinous process, lamina, and facet joint (aka zygapophysial joint)









Spinous Process

Lamina

Articular  
facet

Posterior Longitudinal  
ligament

Transverse  
Process

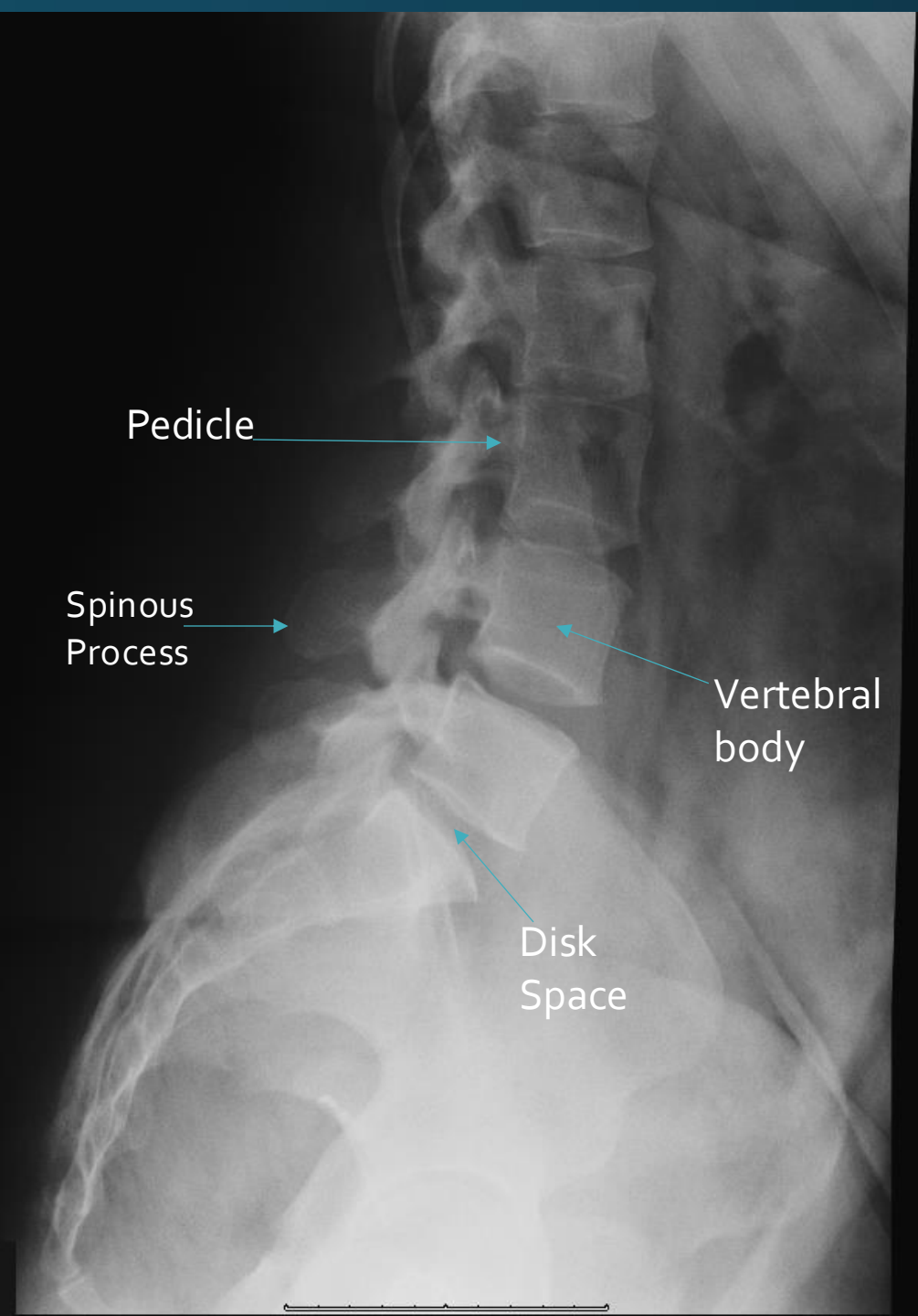
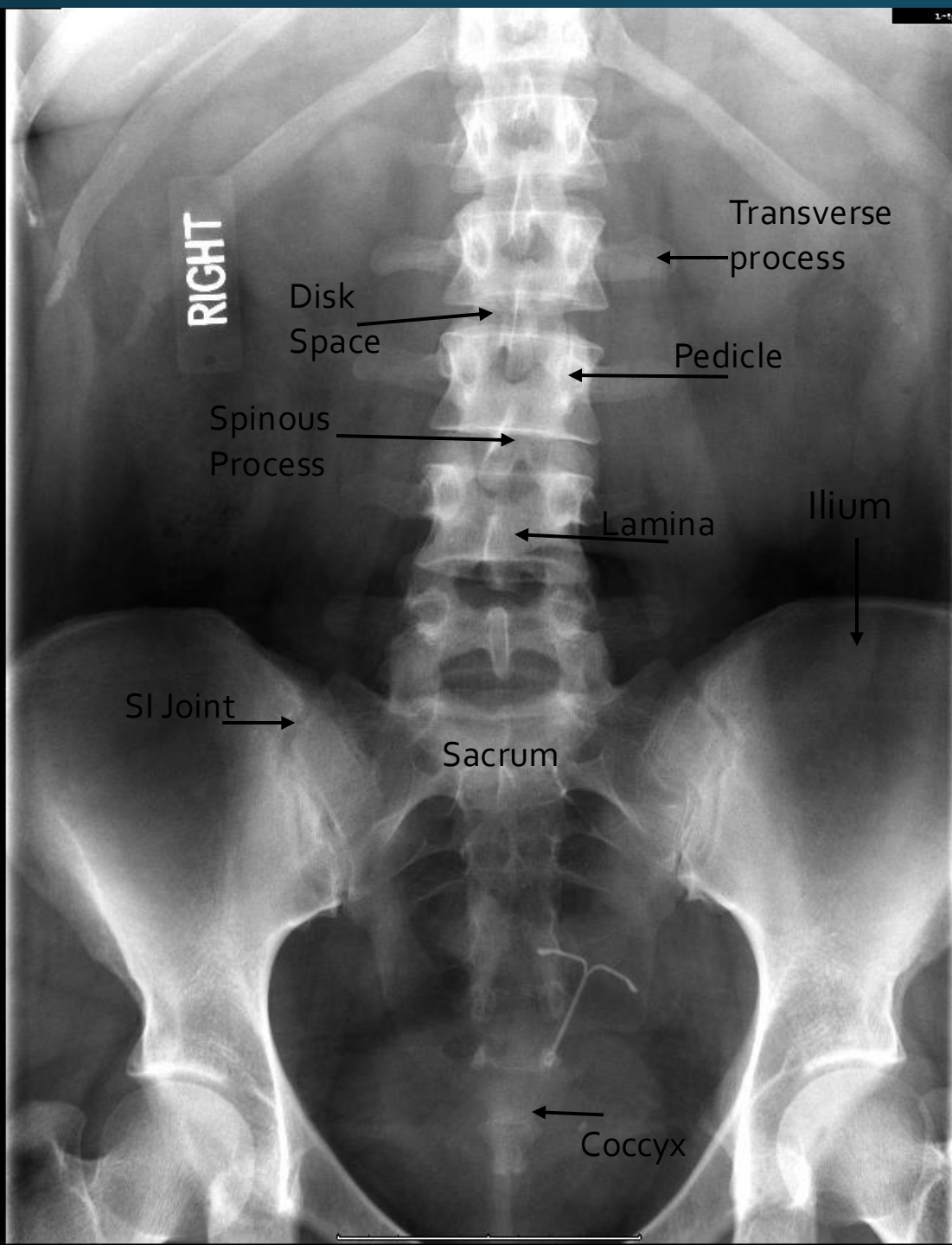
Vertebral Foramen

Vertebral Body

Apophyseal  
ring

Anterior longitudinal  
ligament





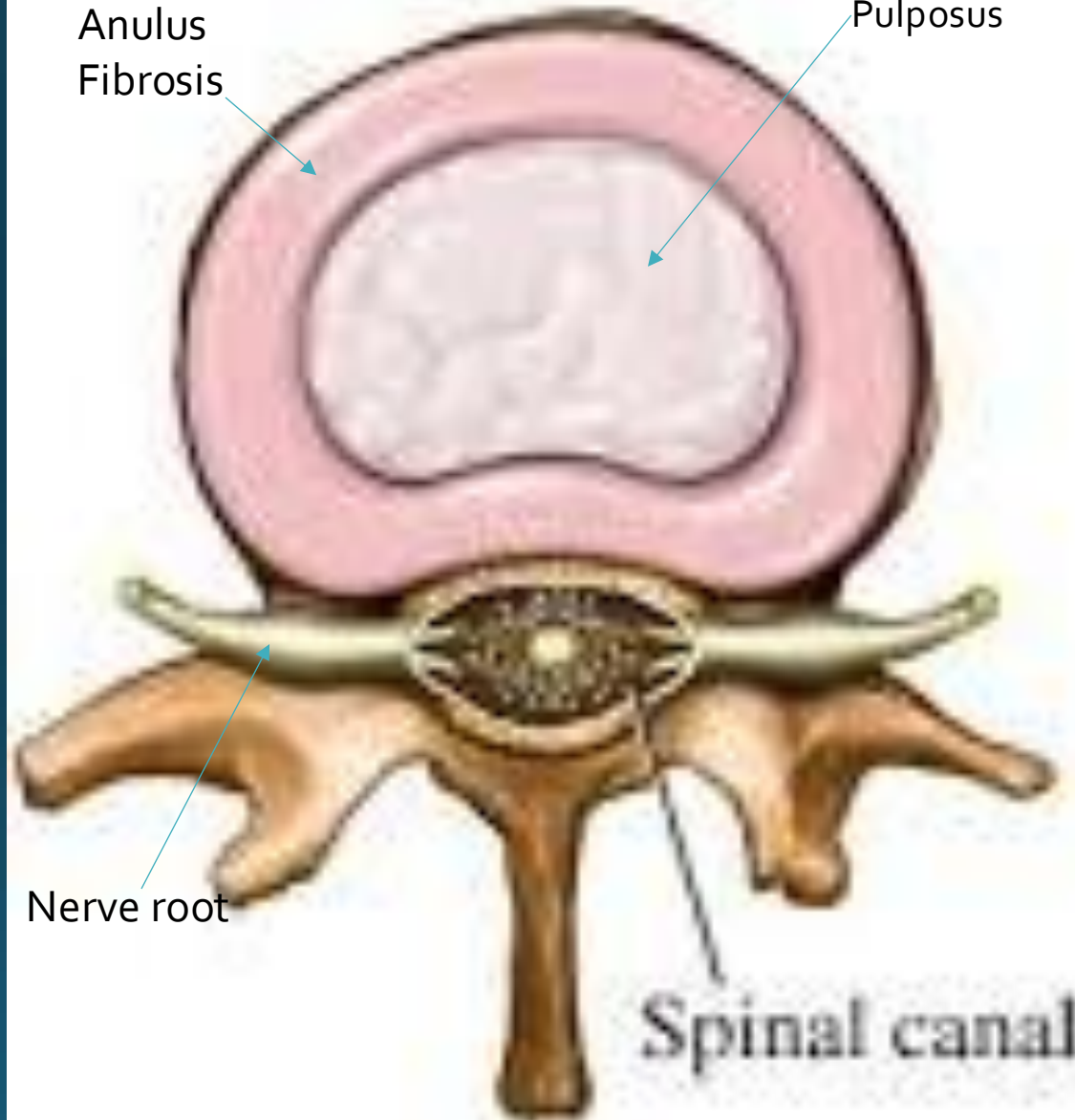
# Normal disc

Anulus  
Fibrosis

Nucleus  
Pulposus

Nerve root

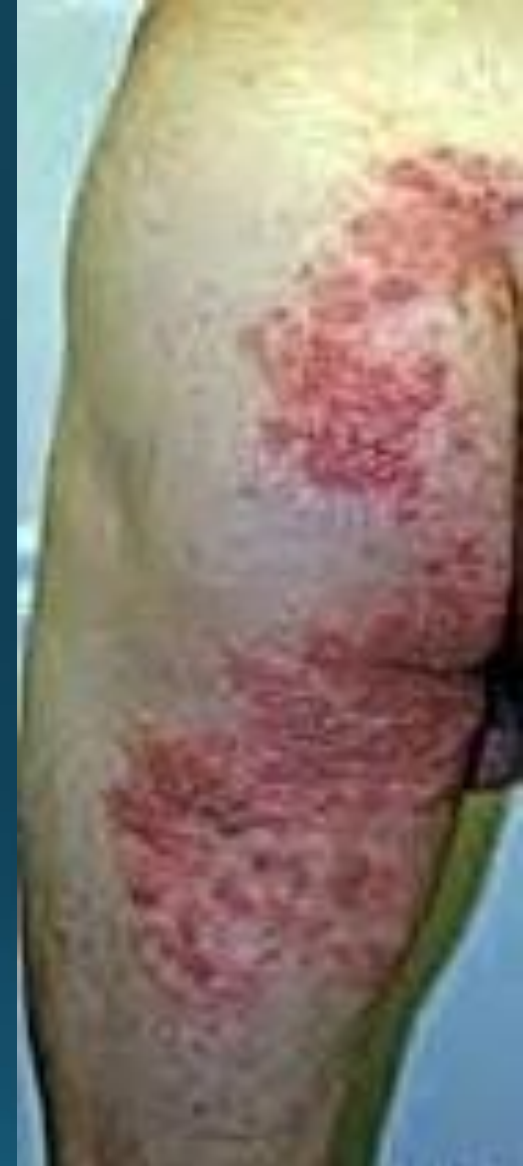Spinal canal



## Physical exam

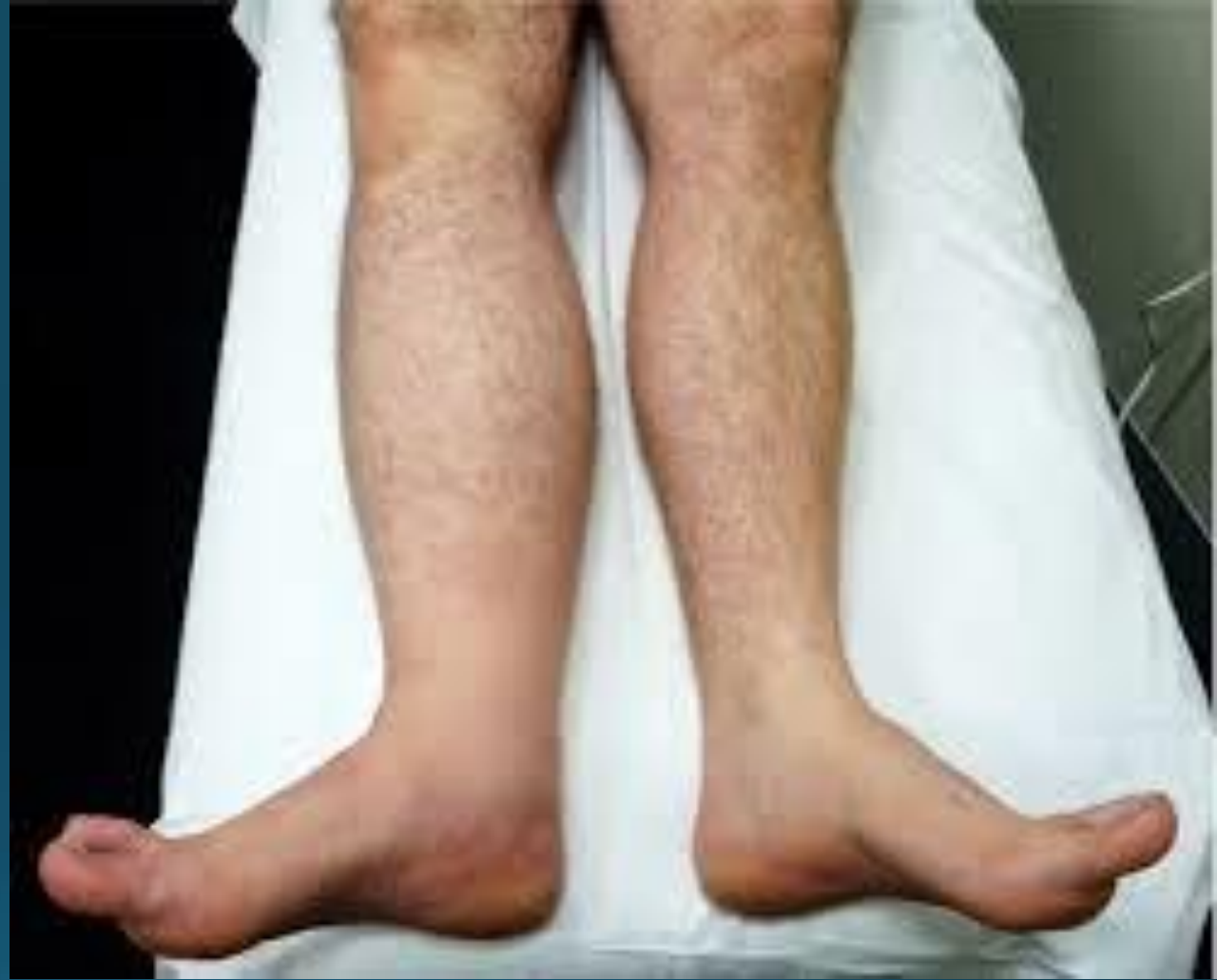- Observation: how is the patient doing when observed walking or sitting (are they limping, is the foot slapping, how is their gait pattern, when seated are they off to one side, are they rubbing their leg)
- Look at them completely as it relates to spine and low extremities. Physically look at their back, buttocks, and legs. Observe for rash, lesions, atrophy, muscle fasciculation, etc)

Here is a picture of a patient who was seen in the ER and referred to our office for back pain / sciatica. He was seen in less than 24 hours from ER presentation.



When measuring for atrophy in the lower limbs it is important that you measure both sides at the same place for a fair comparison.

For example, when measuring calf size you can use the tibial tuberosity and measure down 10cm to get your circumference point. A similar technique can be used for measuring the thigh diameter by using the patella as a reference point.



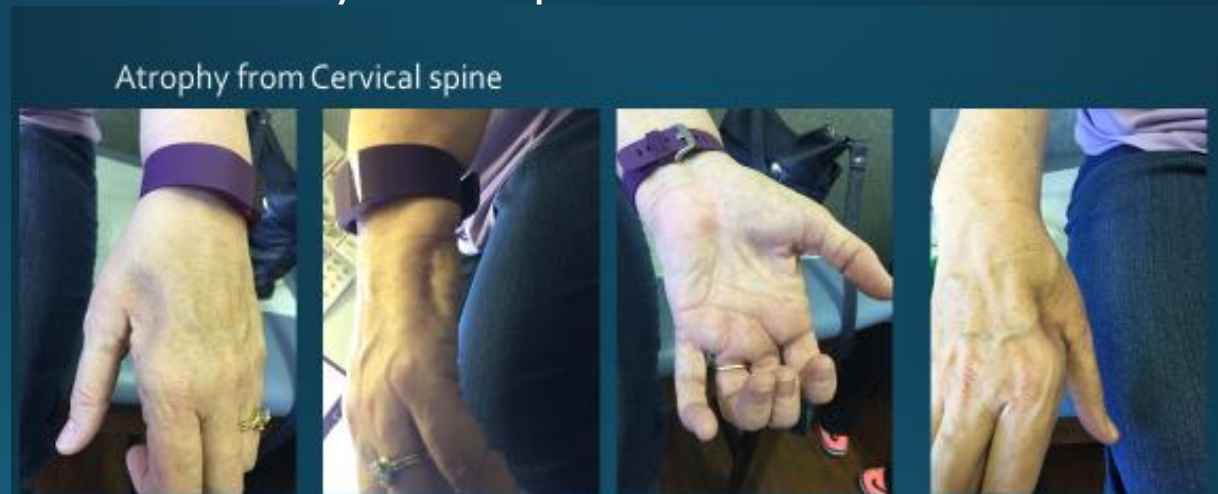


- The Lumbar spine has six planes of motion similar to the cervical spine.



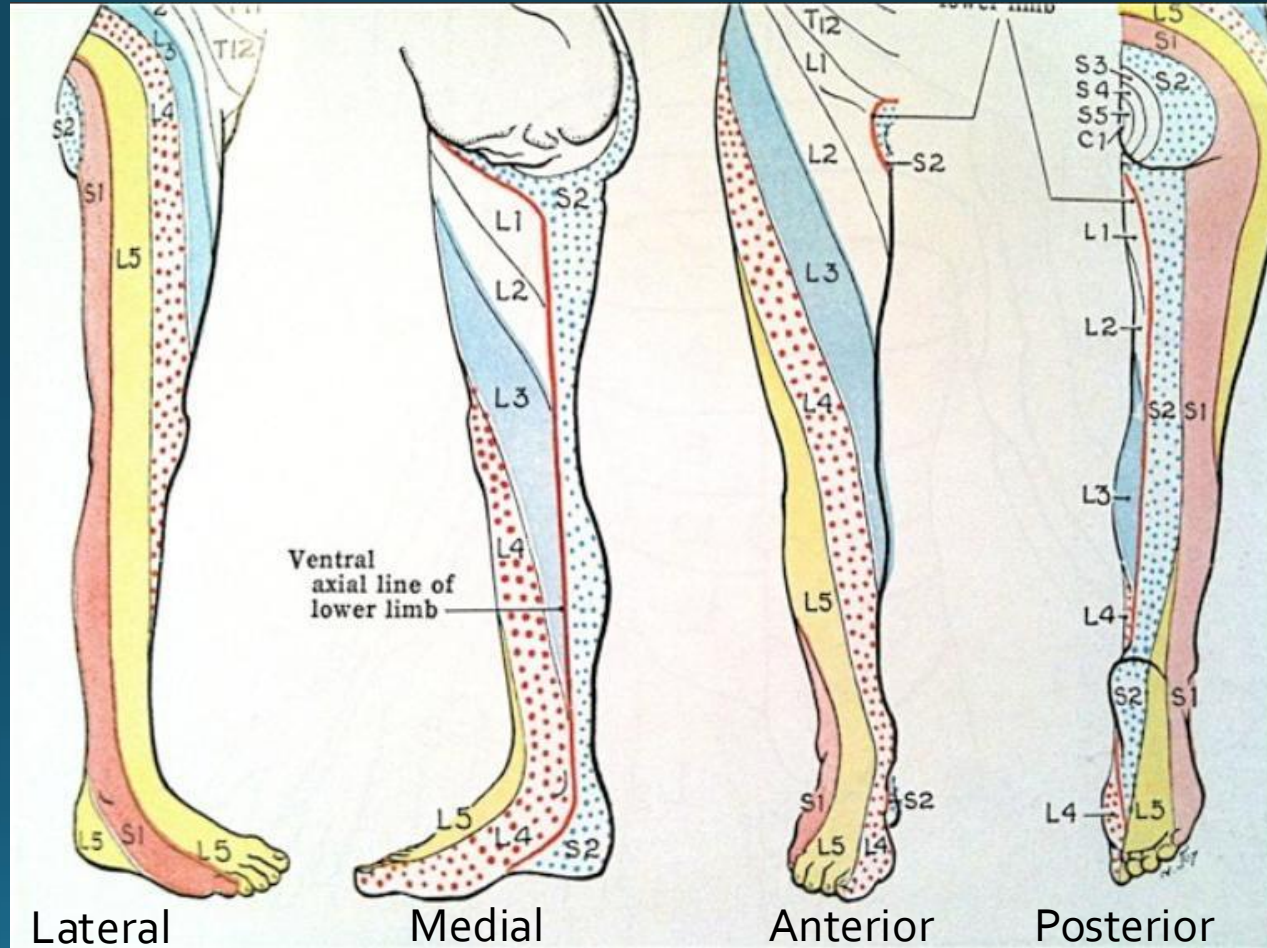
- Flexion of the lumbar spine (bending at the waist): 40-60 degrees of movement, watch for compensatory movements in thoracic spine. The normal lumbar lordosis should flatten. Watch for jerky or painful movements and note how far forward the patient performs the flexion.
- Extension: 20-35 degrees of movement, patient must place hands on hips in order to stabilize the movement and not compensate with pelvic movements.
- Lateral flexion (right/ left): 15-20 degrees, patient runs their hand down the side of the leg while attempting not to make any forward or backward movements. Compare with other side and note amount of rotation performed together with the flexion.
- Rotation: 3-18 degrees, can be performed in standing or sitting (to eliminate compensatory hip movement).

- Palpation of the major muscle groups of the lower extremities is important to determine muscle bulk.
- Muscle tone is the slight tension in the muscle during relaxed period. This is accomplished by having the patient relax their muscle and the examiner passively moves the extremity. Findings for abnormal tone include spasticity (limb moves freely for a short period then a catch occurs requiring more force to move limb), rigidity (a ratchet like affect which is uniform throughout movement), paratonia (the person involuntarily resist passive ROM).



Dermatome: area of skin innervated by the spinal cord. Each cord segment has a representative skin area (Tabers 18<sup>th</sup> edition)

- Having a reasonable understanding of the lumbar dermatomes can help narrow the level of pathology. This is helpful when used with the PE for weakness or reflex changes in determining actual pathology.





# Strength Grading

- American Spinal Injury Association (ASIA)
- Strength Grading
- Grade Strength Measured
- 0 Total paralysis
- 1 Palpable or visible contraction
- 2 Active movement
- 3 Active movement against gravity
- 4 Active movement against gravity with some degree of resistance
- 5 Active movement with full resistance (normal)



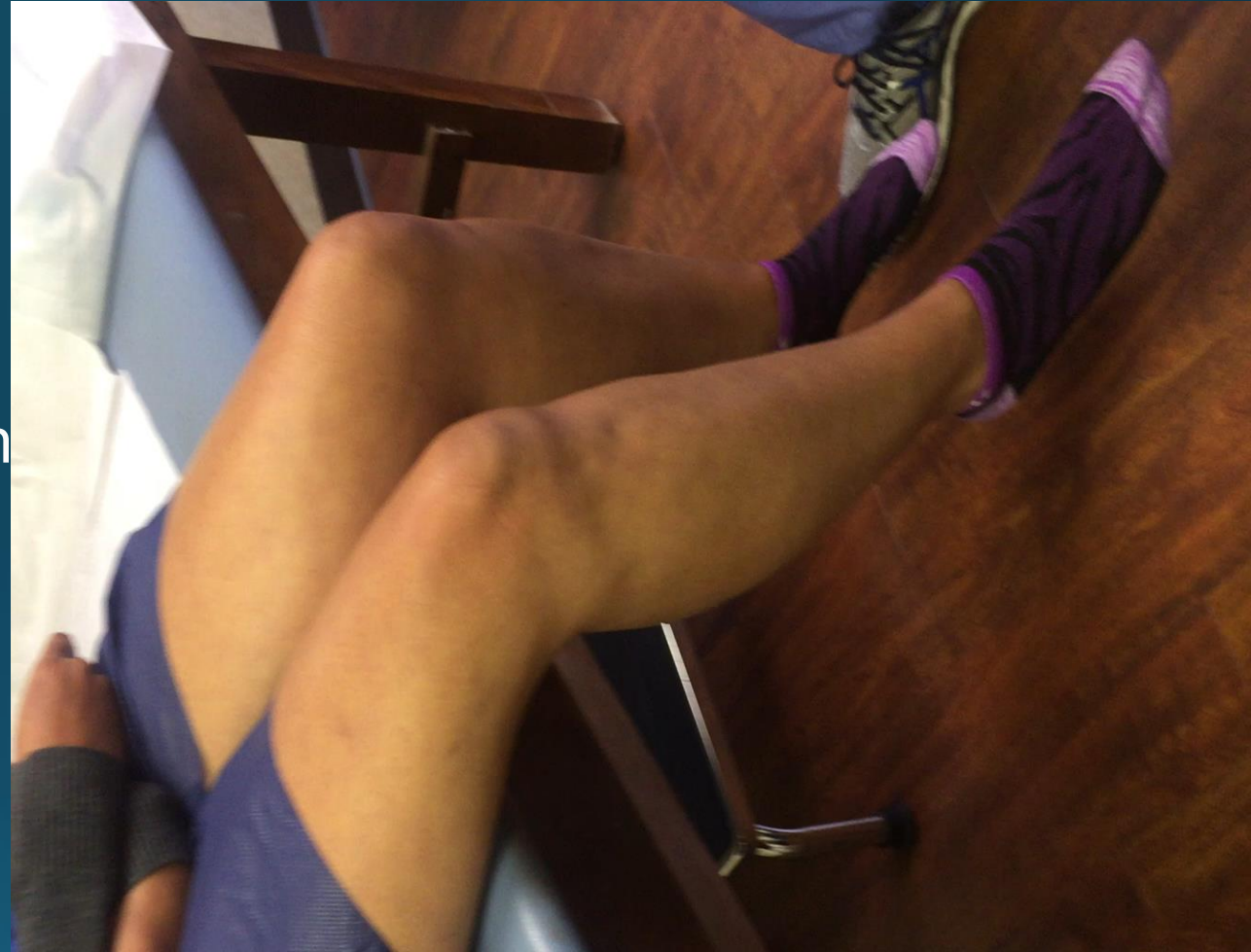## Strength exam

- L2-3 Hip flexors
- L3-4 Knee extension
- L4-5 Dorsiflexion / heel walking/ EHL
- L5-S1 Plantar flexion/ toe walking



## Deep tendon reflexes

- Not all the nerves into the lower extremity can be tested with a reflex.
- L3-4 (mostly L4) is elicited from the patella reflex
- L4-5 (L5) can be elicited from internal hamstring but is not commonly tested
- L5-S1 (S1) can be evaluated by the Achilles reflex



## Example of Hyper-Reflexia



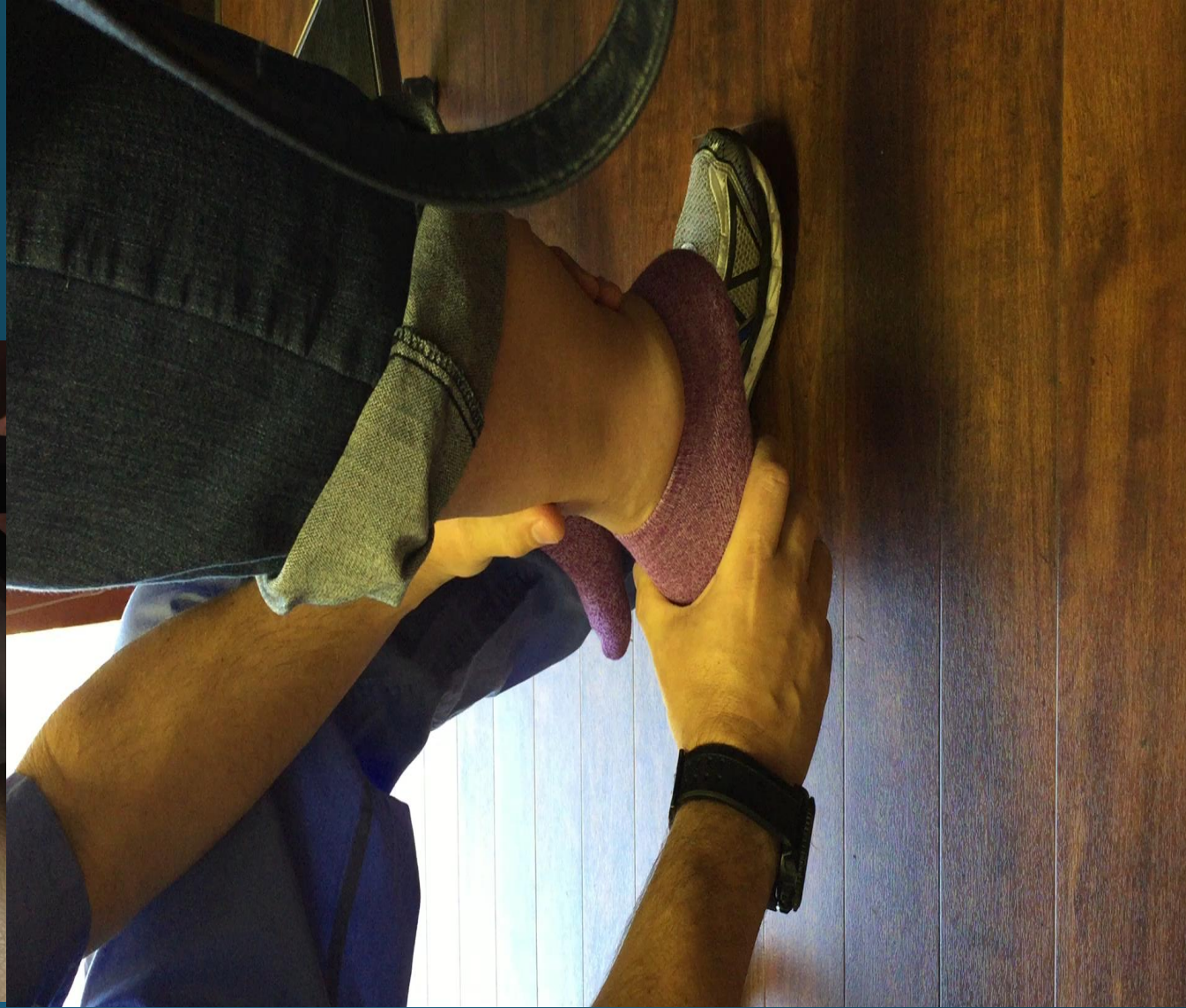
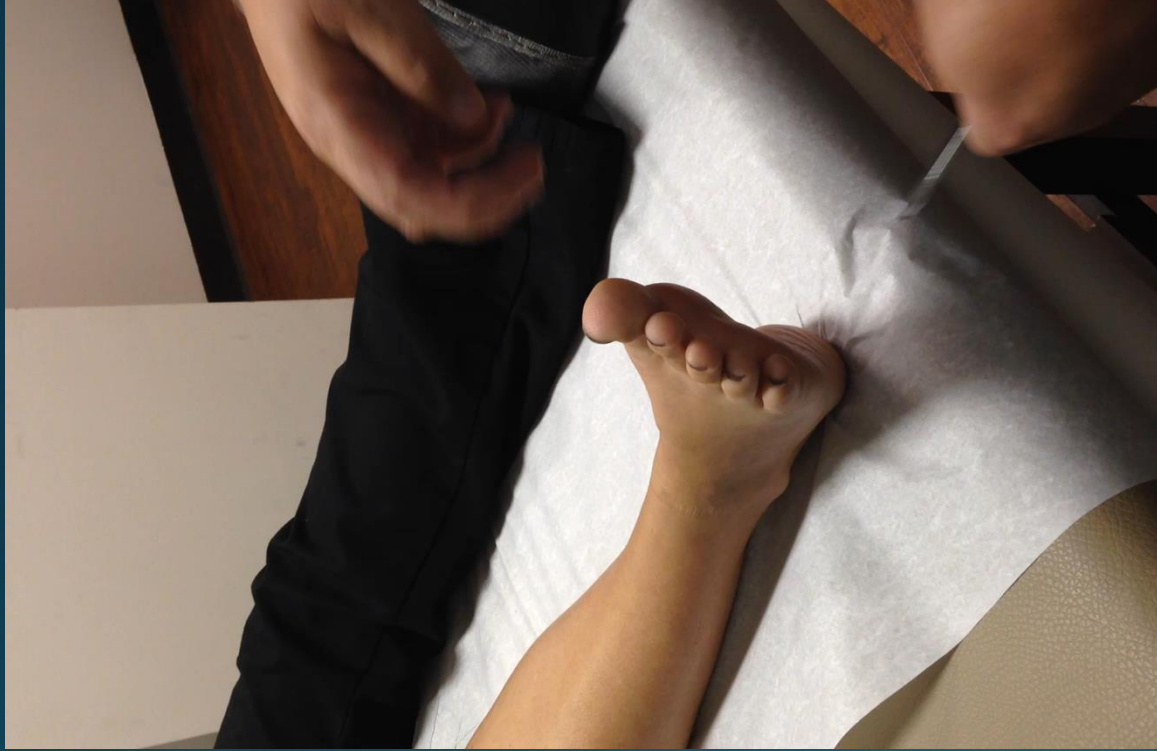
## Example of depressed patella reflex



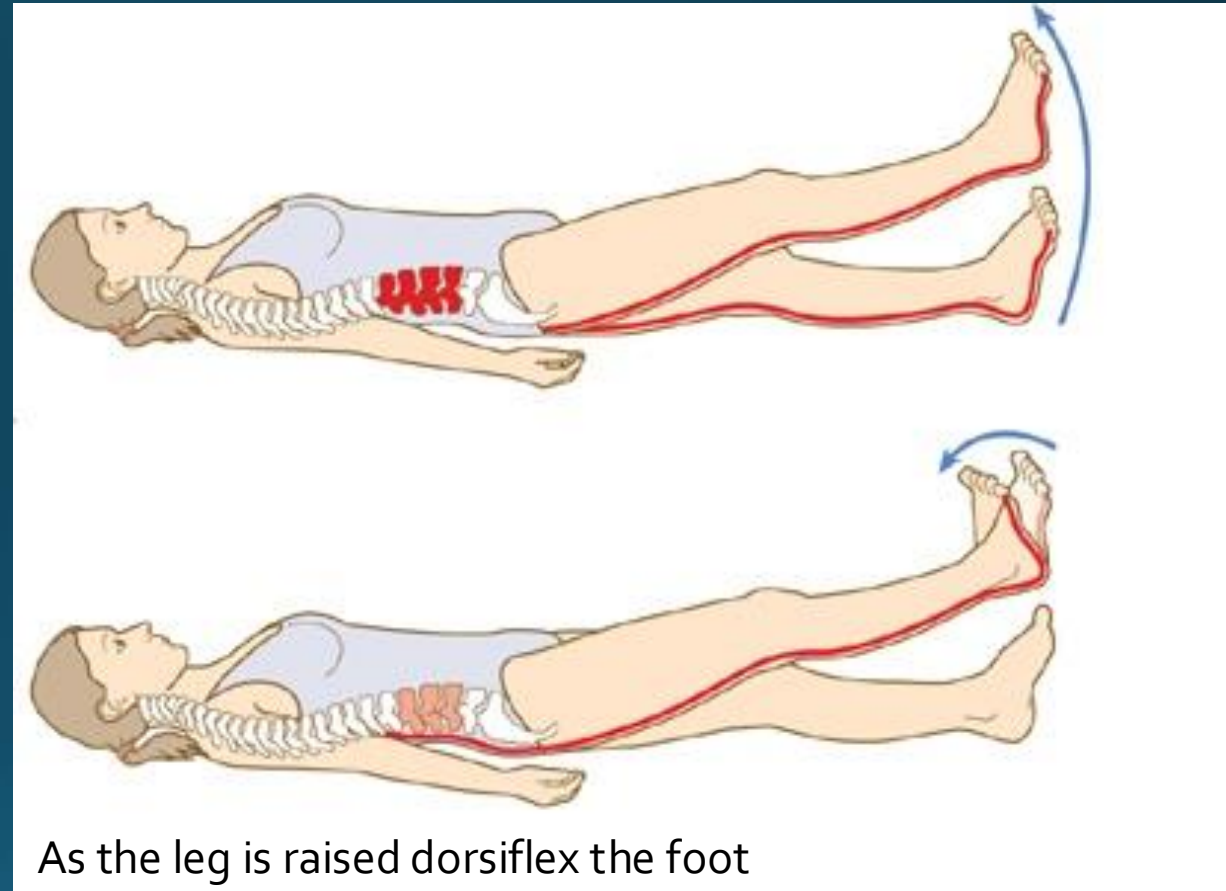


## Special pathologic reflexes

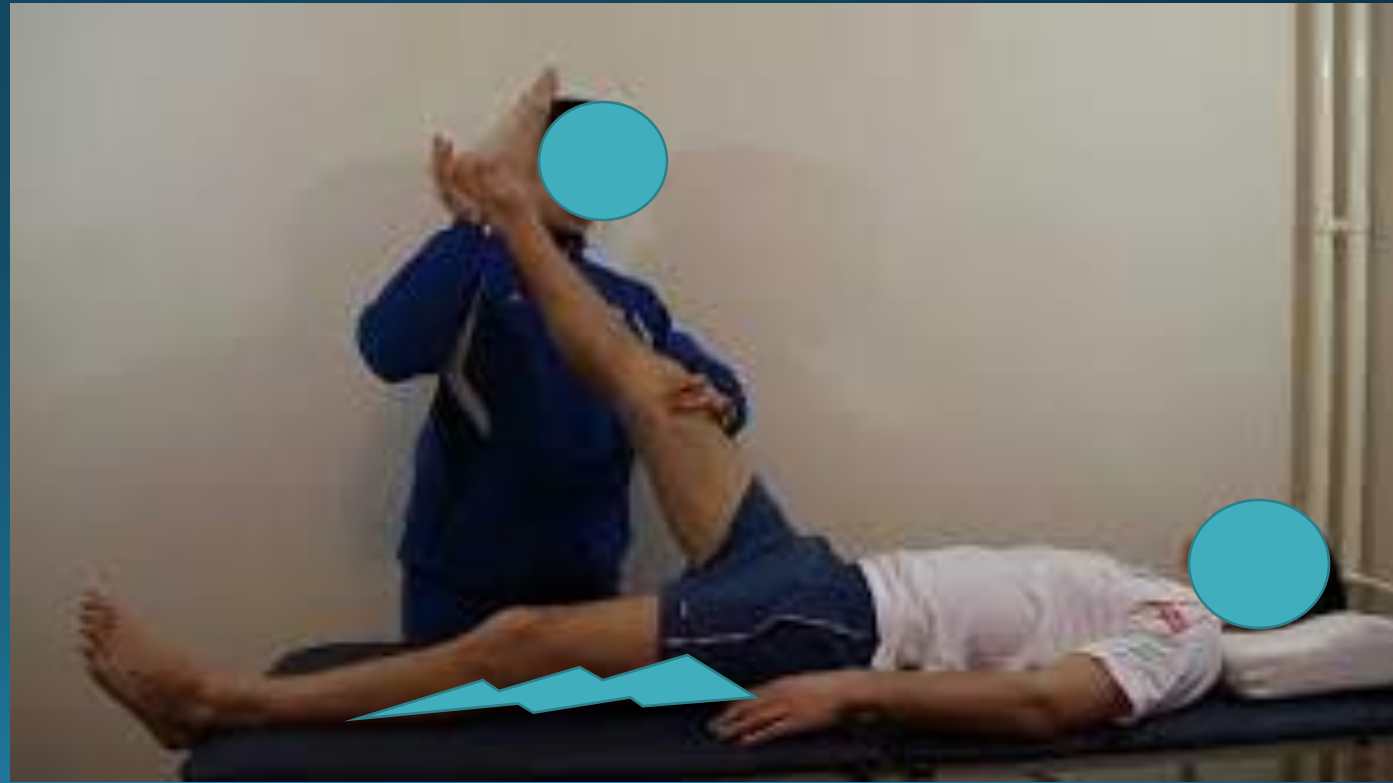

## Special physical exam testing

- Straight leg raise: may be completed while sitting or laying. Cup the heel of their foot and gently raise the leg. If there is nerve root irritation, the patient will experience their typical pain when the leg is elevated between 30 and 60 degrees.

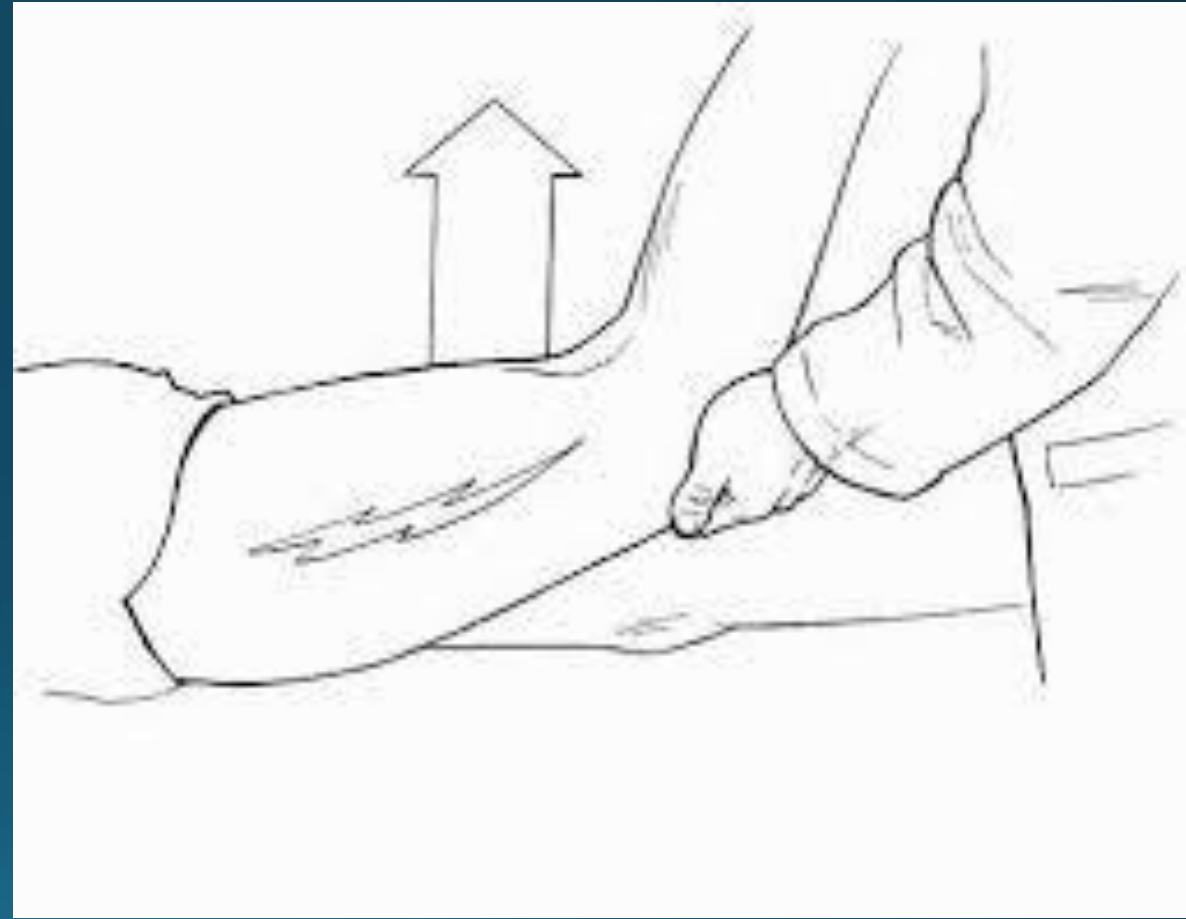

- Opposite straight leg raise (crossed straight leg raise): If the straight leg test is positive, repeat the same test on the opposite leg. This is called the crossed straight leg raised test and is 85-95% specific for root irritation, but not sensitive. Therefore, positive test makes root irritation the likely etiology of the symptoms.





- The femoral stretch test is a valuable sign in diagnosing upper lumbar nerve root compression  $L3-4 > L2-3$
- The patient lies prone, the knee is passively flexed to the thigh and the hip is passively extended; the test is positive if the patient experiences anterior thigh pain

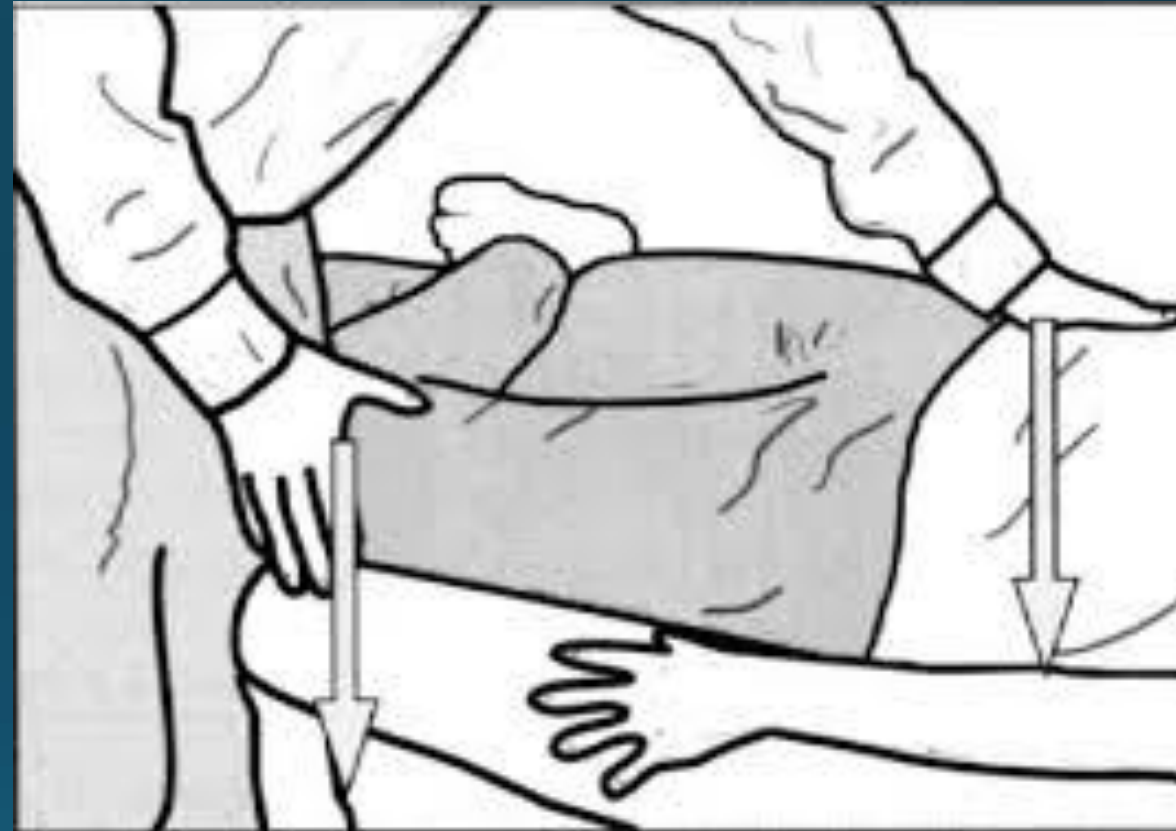



- Asking about Valsalva signs can help the examiner distinguish between nerve root pain and non-specific back pain.
- When a patient complains of pain into the leg with cough, laugh, or sneeze this can be indicative of nerve root irritation.
- This occurs because when the above maneuvers are performed the pressure in the thecal sac is increased. When there is already compression on the thecal sac and these triggers occur the patient is likely to have a significant episode of radicular pain.

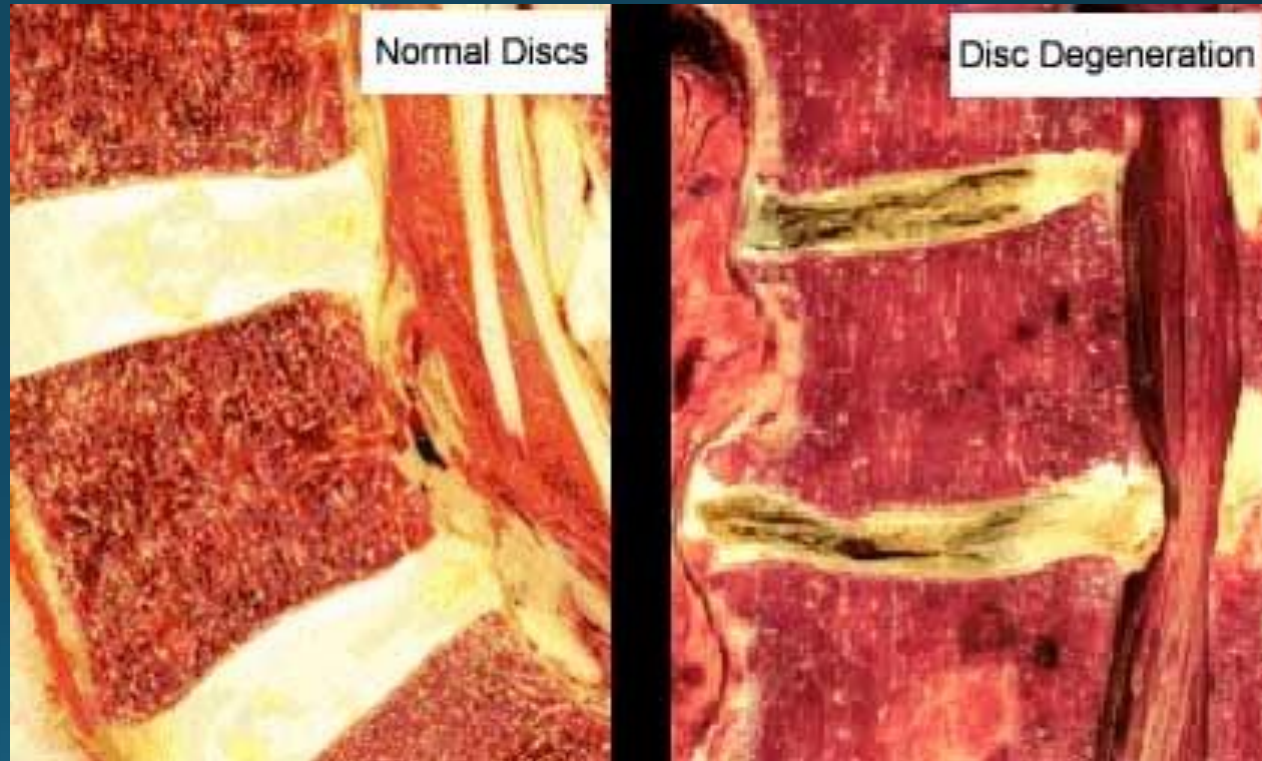


- FABER (flexion, abduction, and external rotation): this is common provocative test for the sacro-iliac joint.
- SI related pain can mimic sciatica and is becoming more commonly accepted as a source of back and leg pain

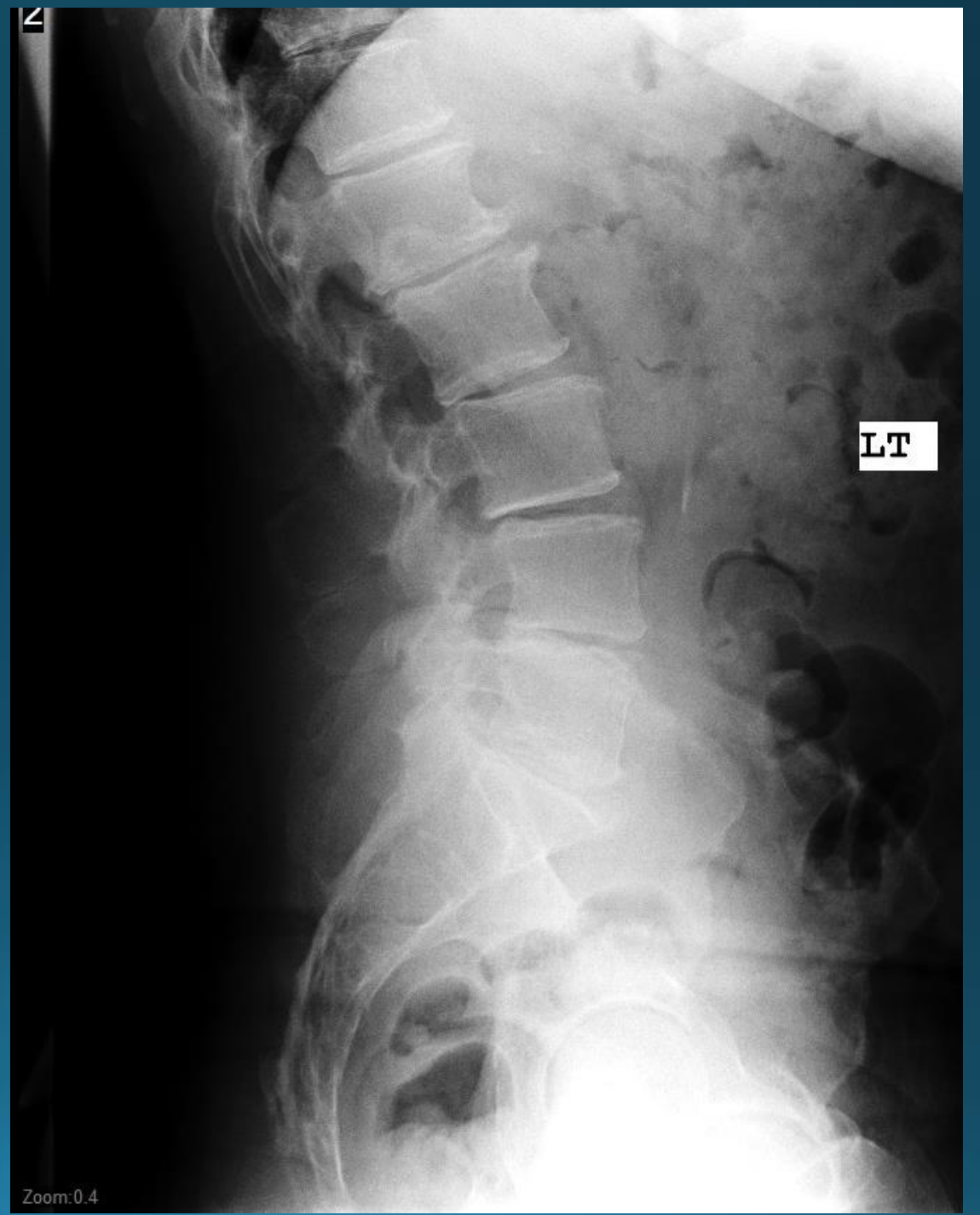
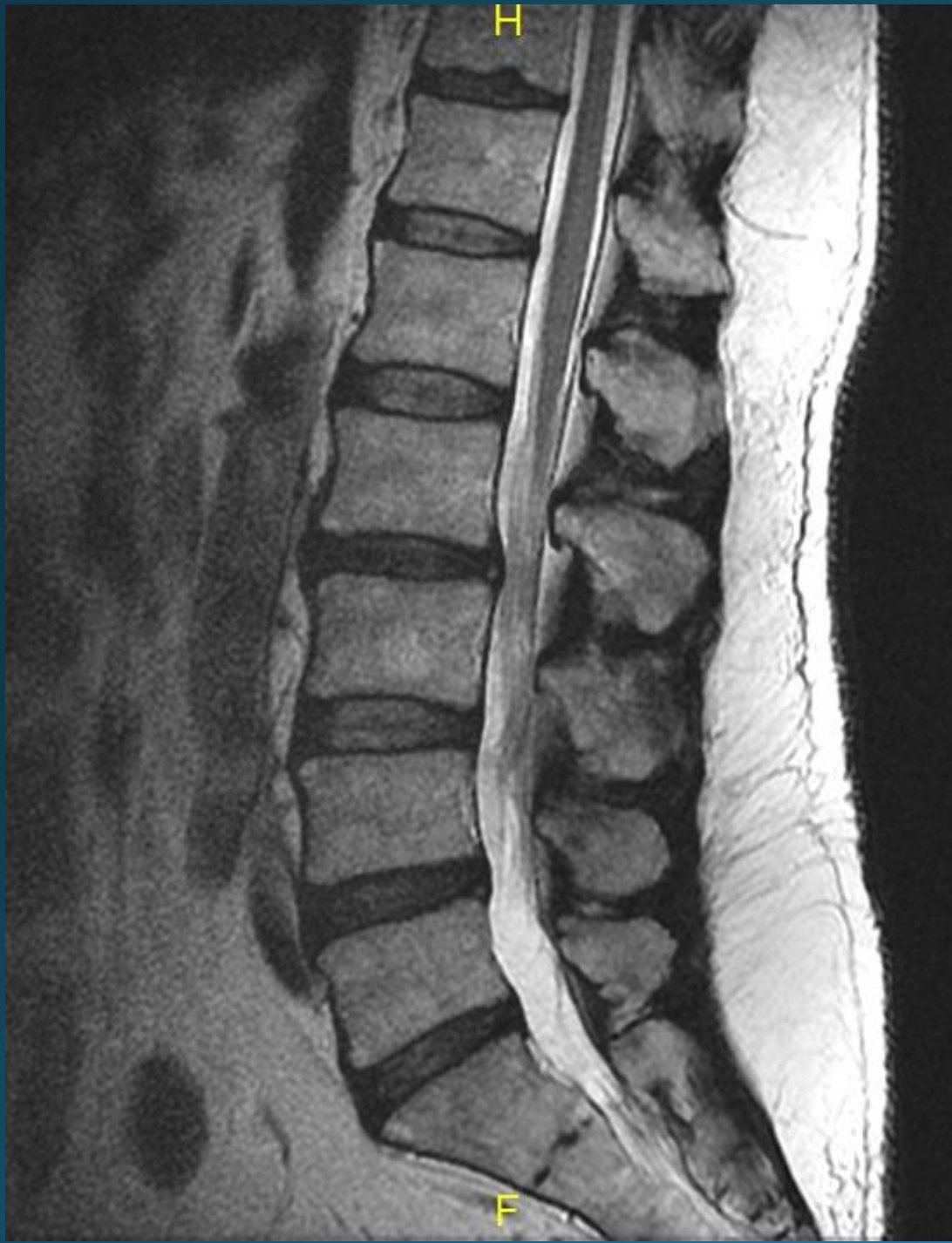

## Pathology....Mechanical vs Neuropathic

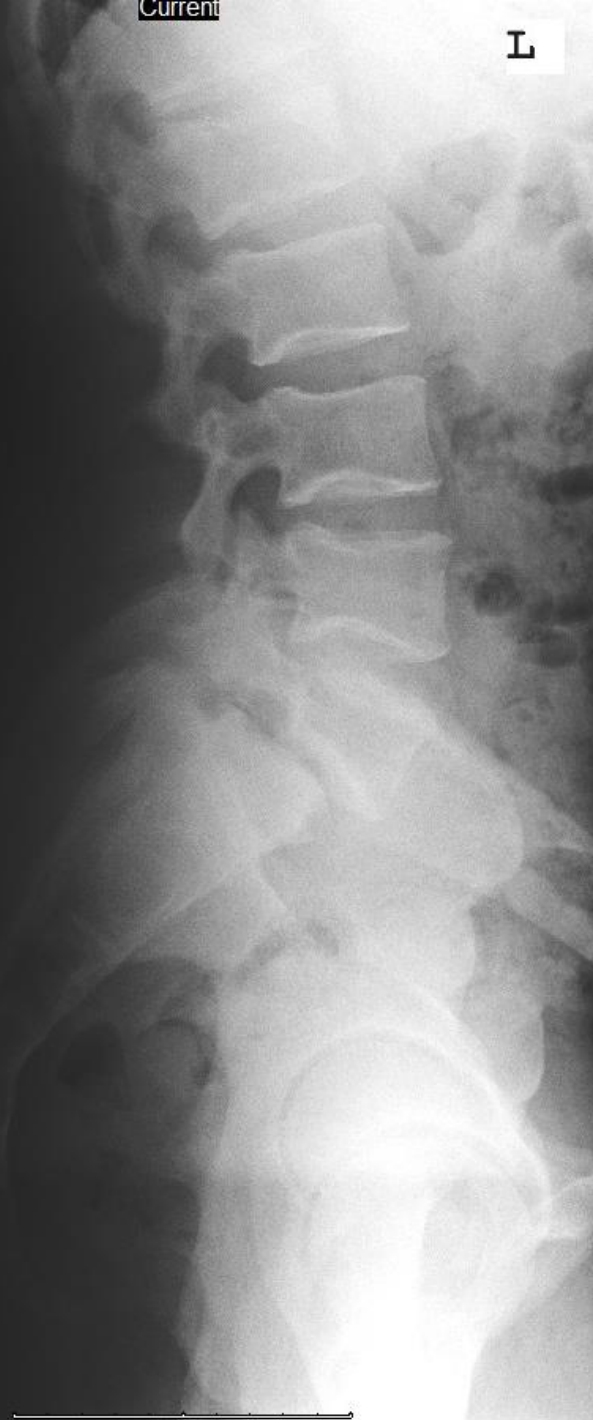- Mechanical back pain or axial column back pain is a very common complaint. This type of pain is generally in the low back alone and does not have much or any radicular component.
- This is the typical wear and tear
- Unfortunately disk do not regenerate



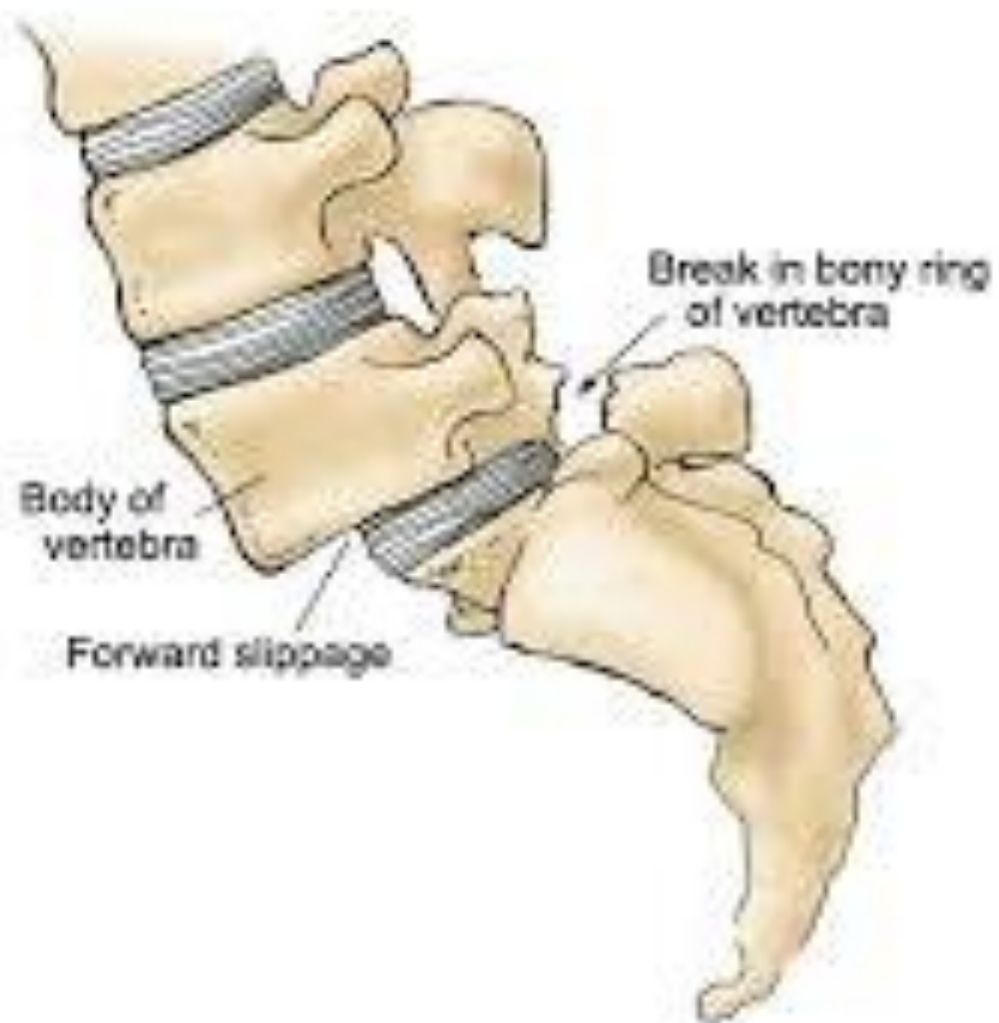


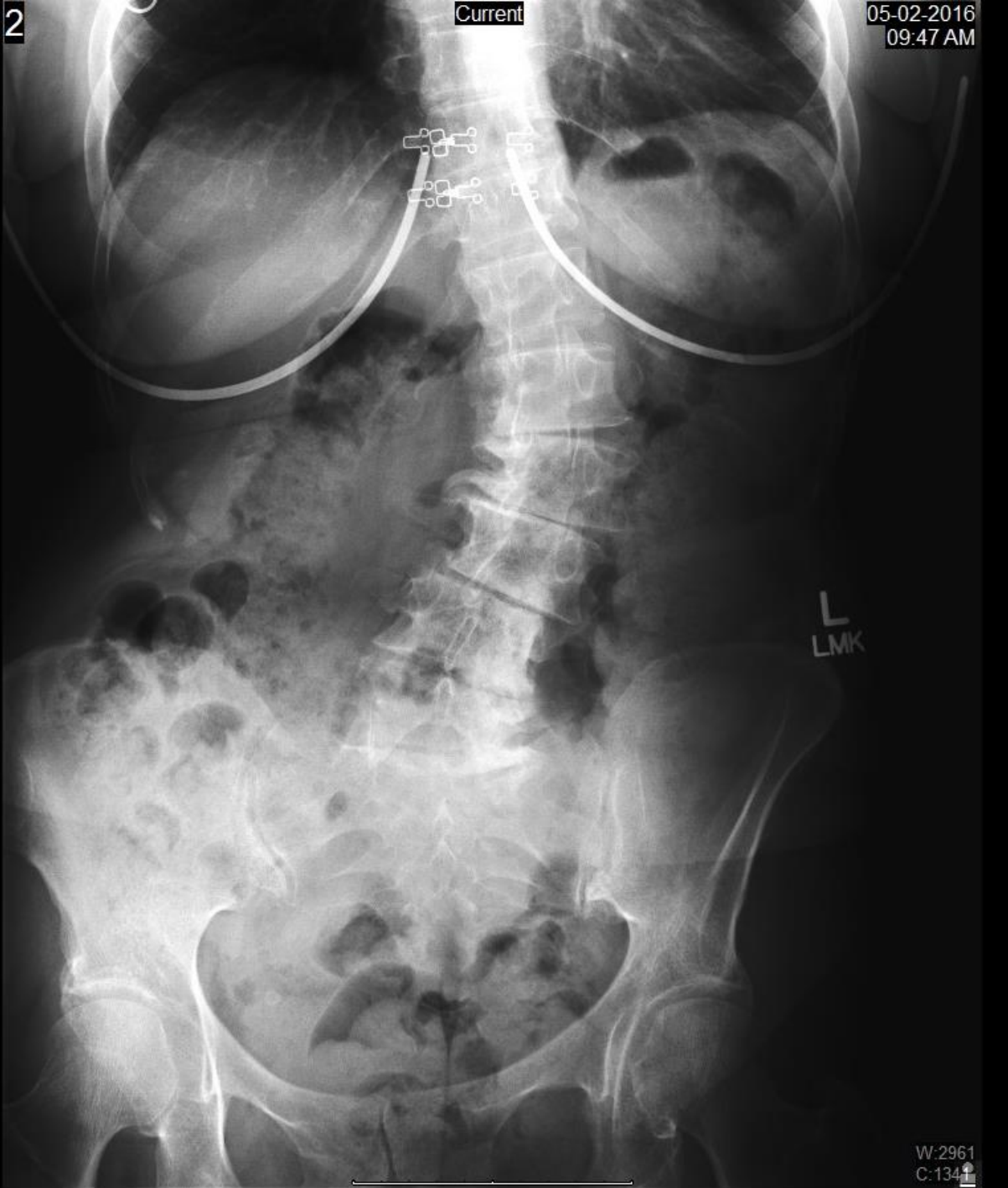





## Spondylolisthesis

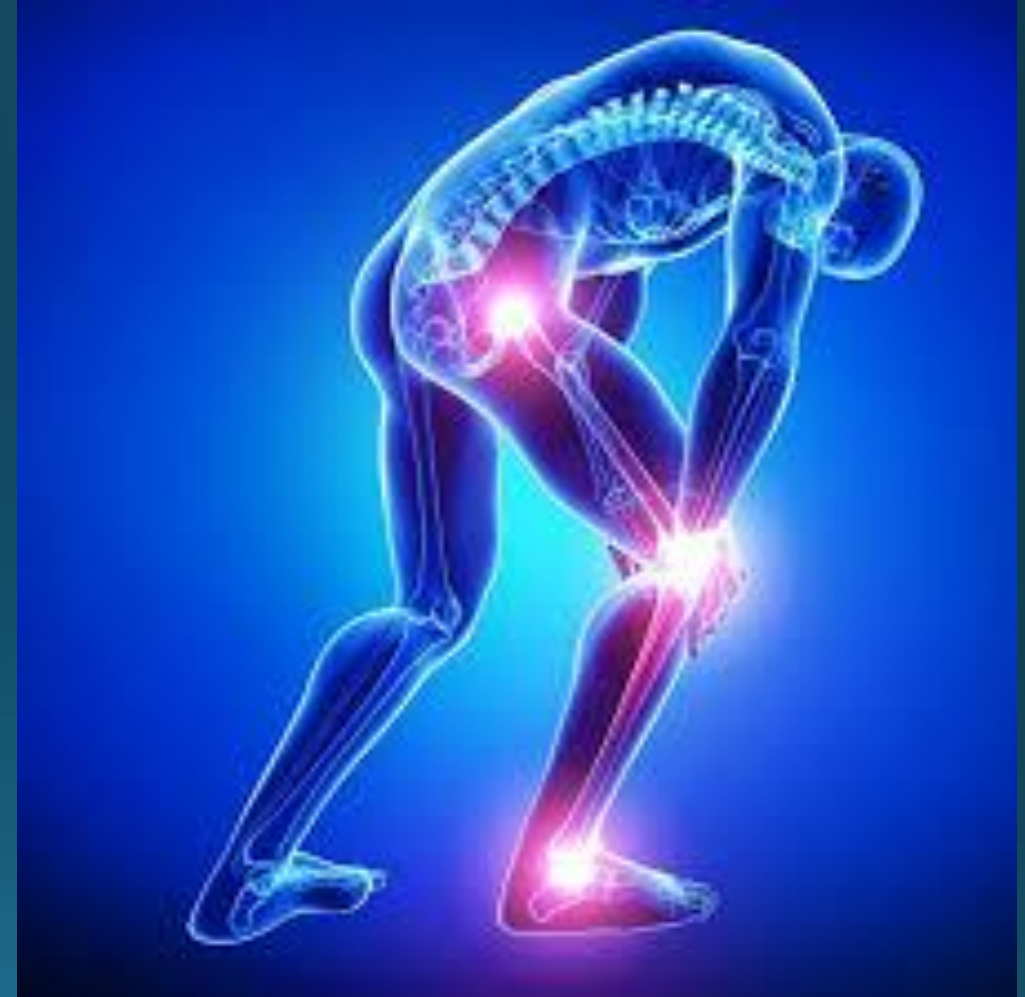



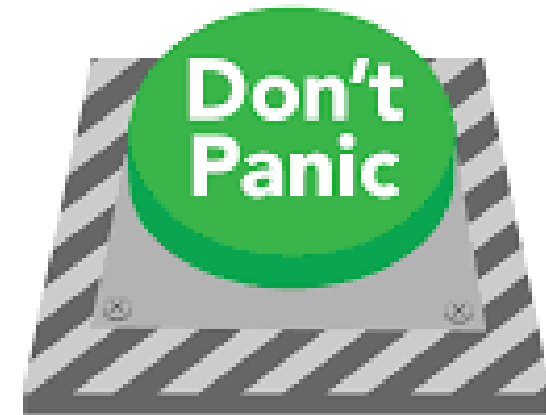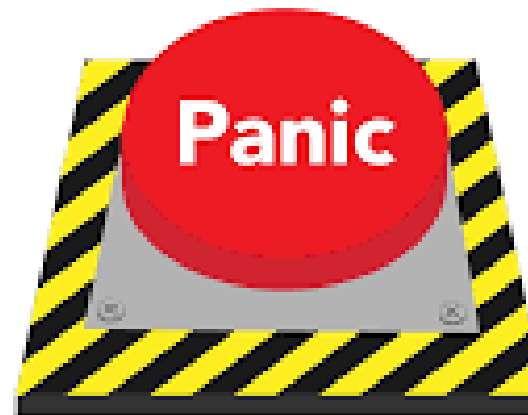With the aging population we are seeing this problem increase in frequency. This is a classic adult scoliosis

# Neuropathic Pain

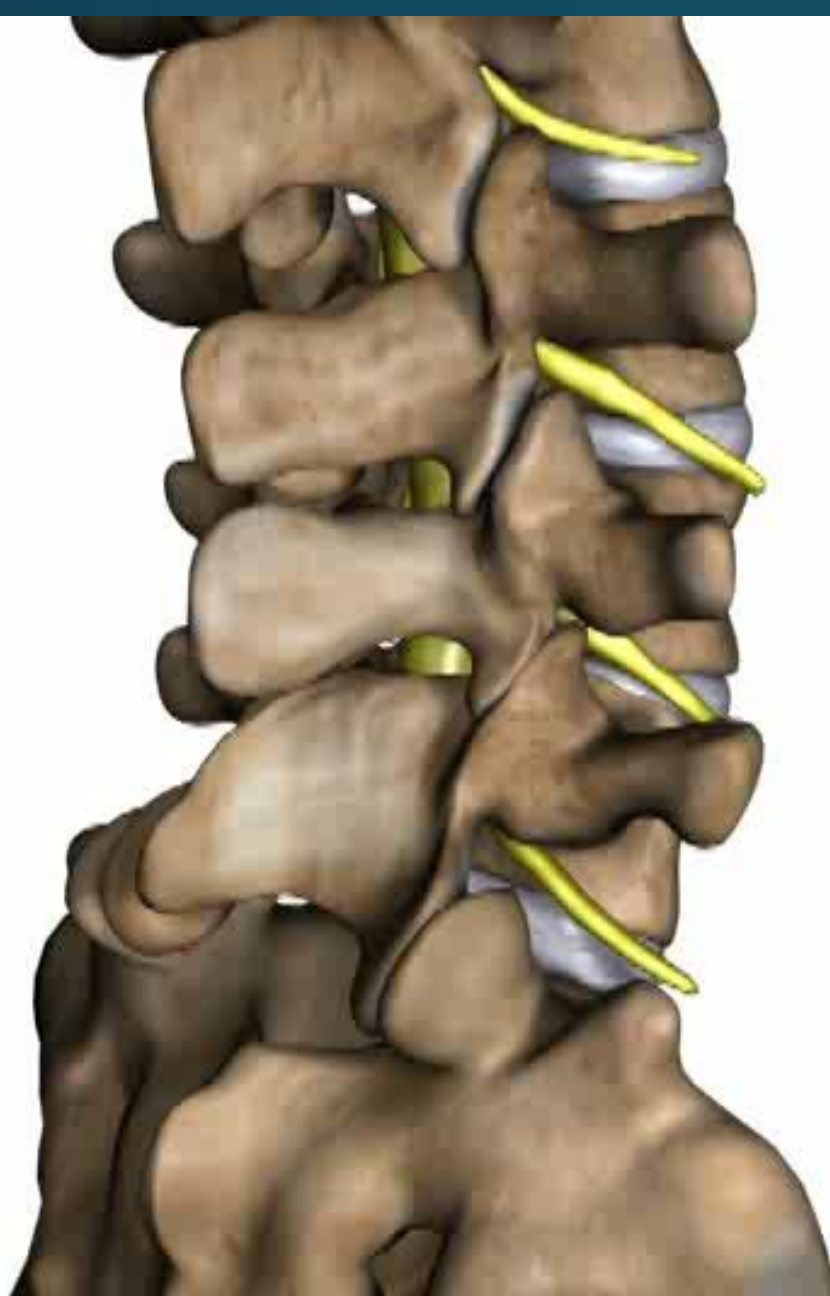
- Neuropathic pain is pain that causes numbness, tingling, burning, down into the leg.
- Patient demographics can help narrow the differential list when a patient presents with these complaints. For example, in a 20-40 y/o with radicular neuropathic pain HNP is most likely dx however in a 65 y/o with similar pain stenosis would much more likely

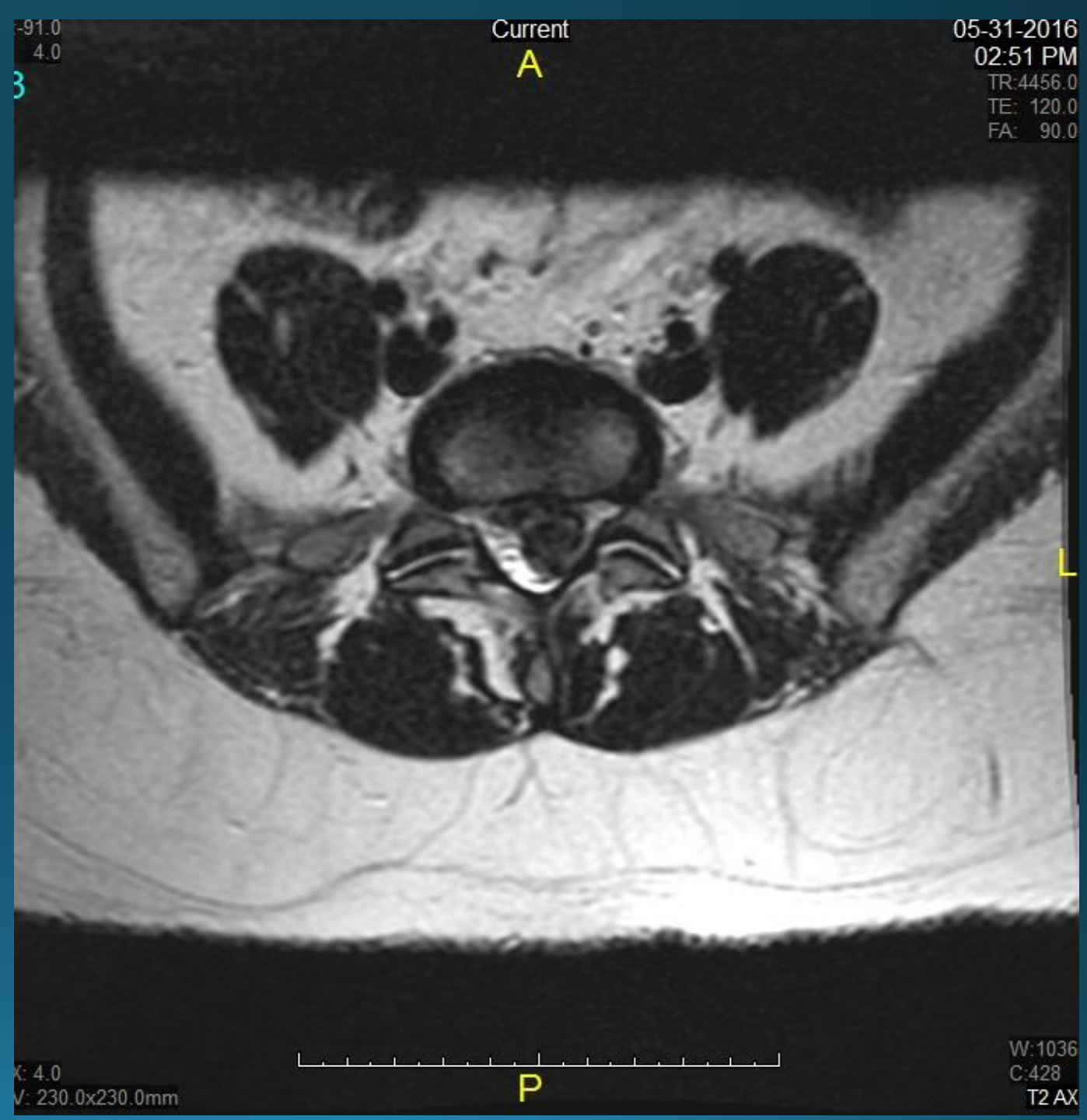
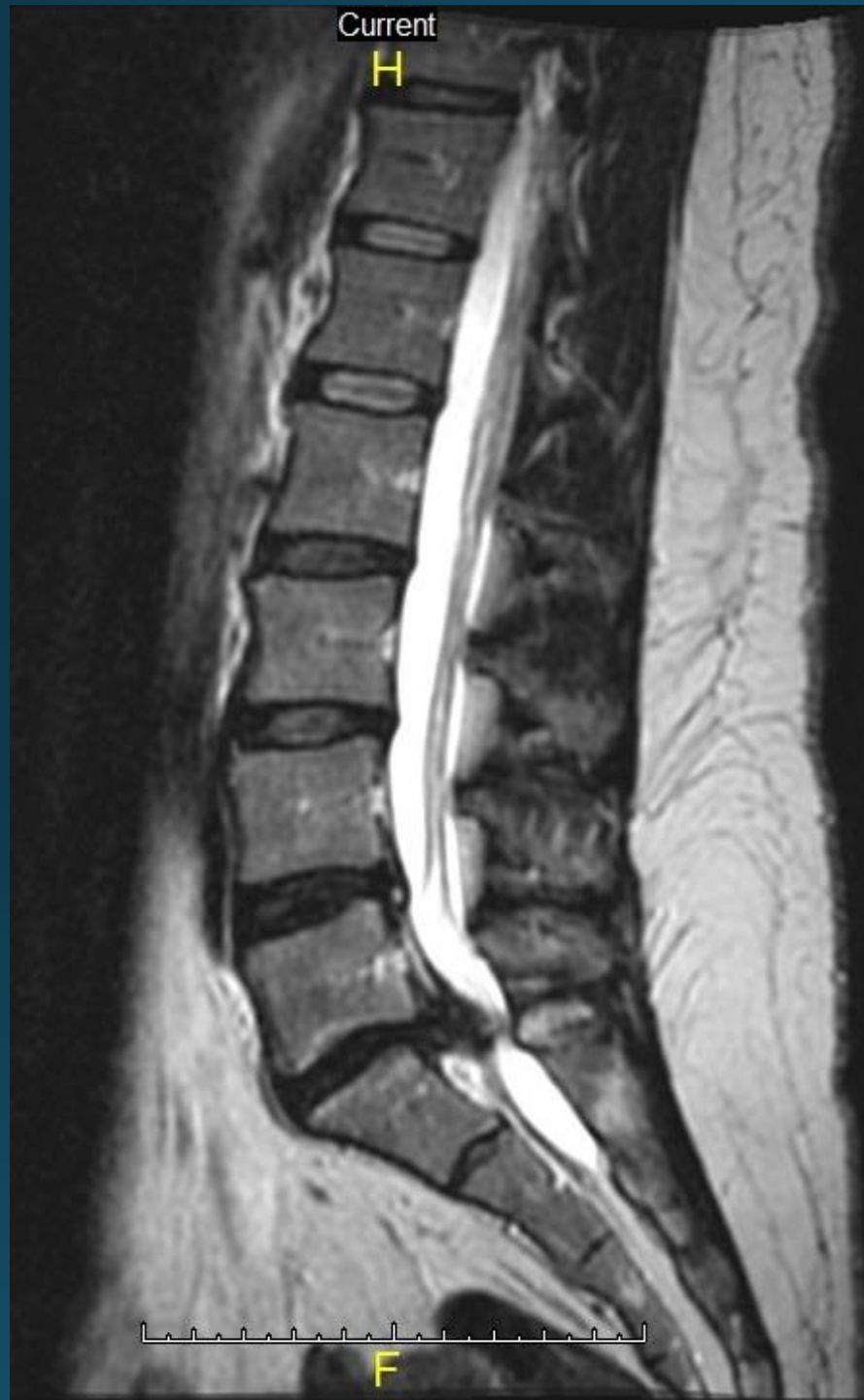

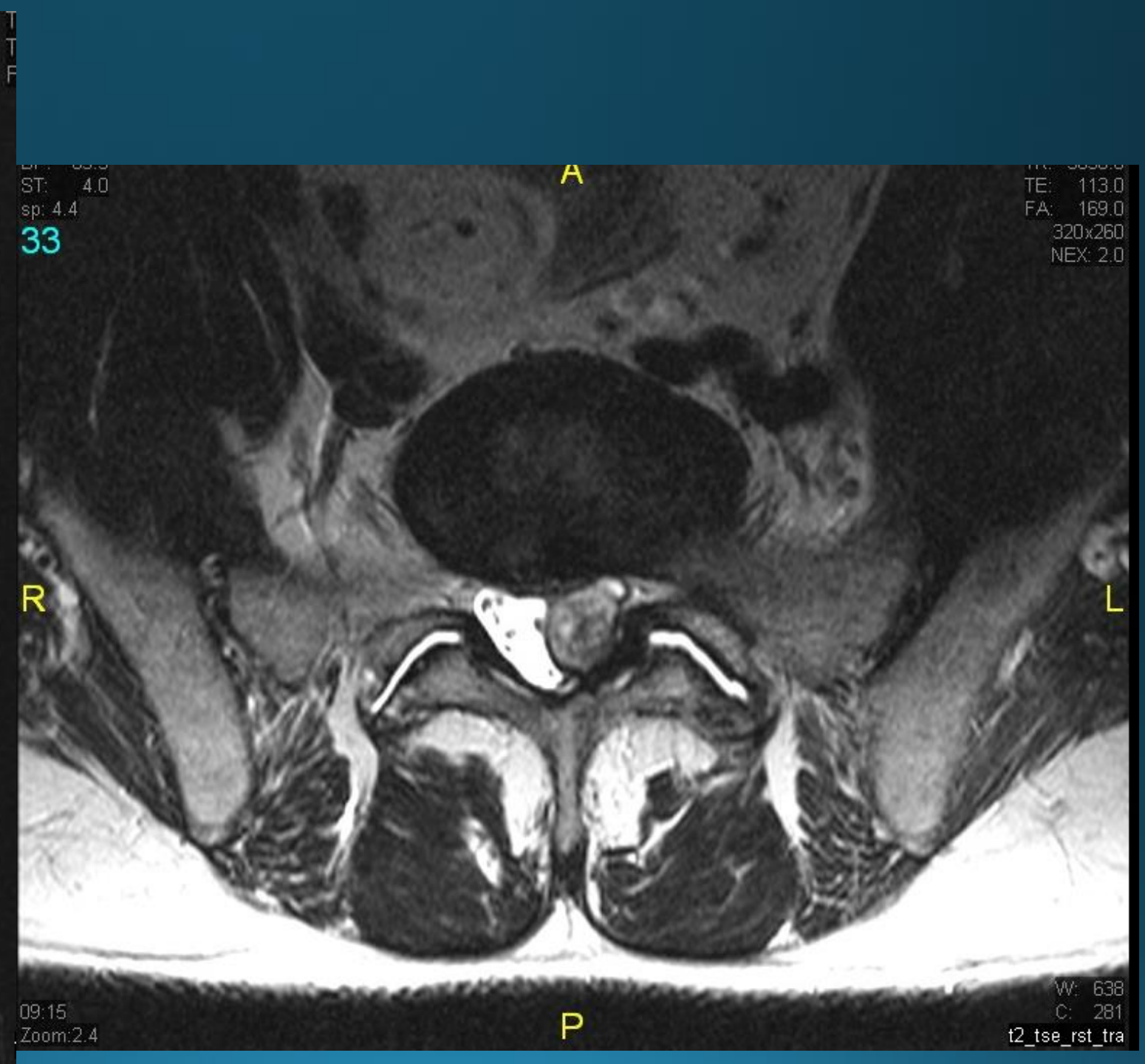
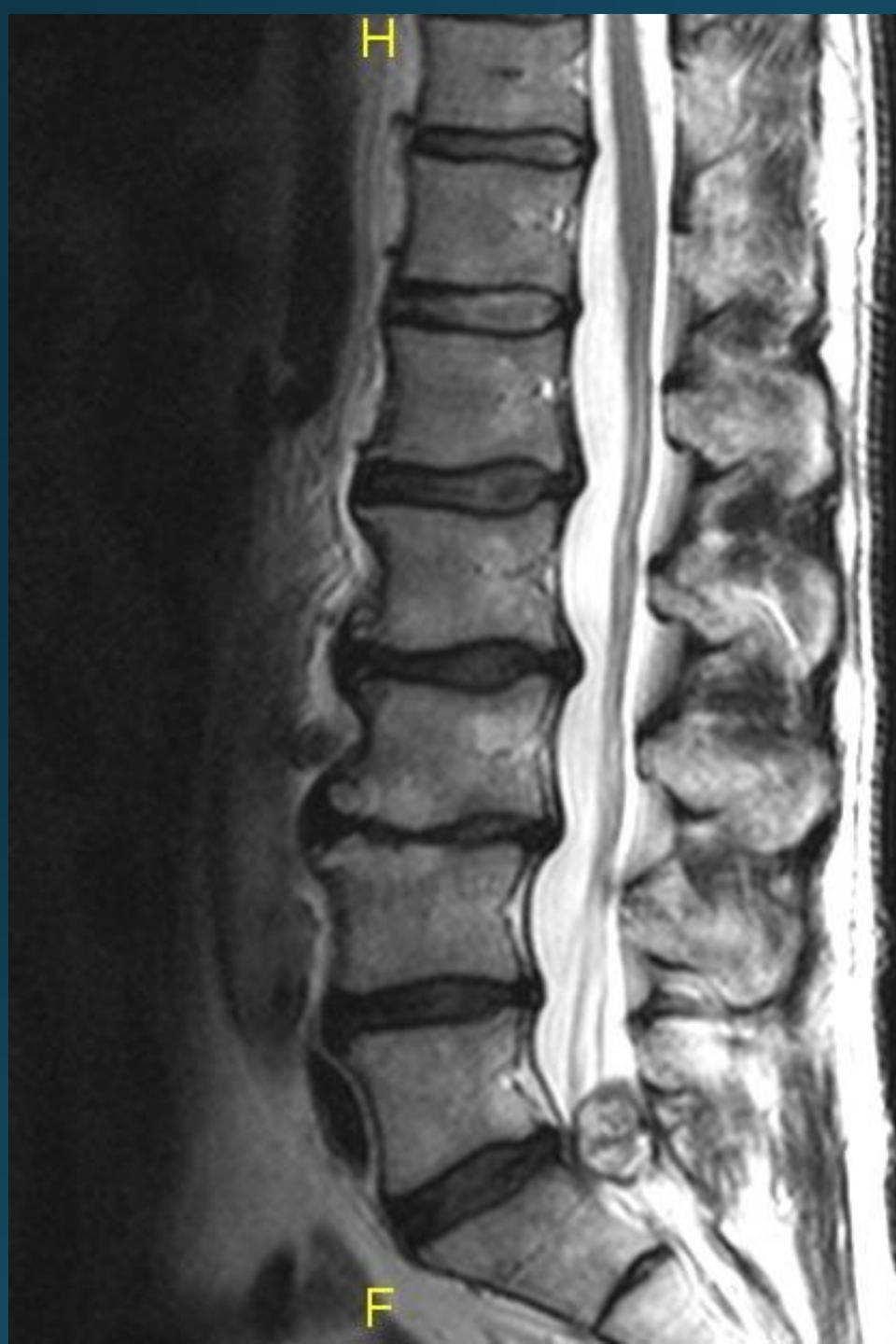- Differential diagnosis for a patient with sciatica can include HNP, stenosis (central or neuroforaminal), synovial cyst, epidural lipomatosis, arachnoiditis, tumors (benign and malignant), epidural abscess, and epidural hematoma



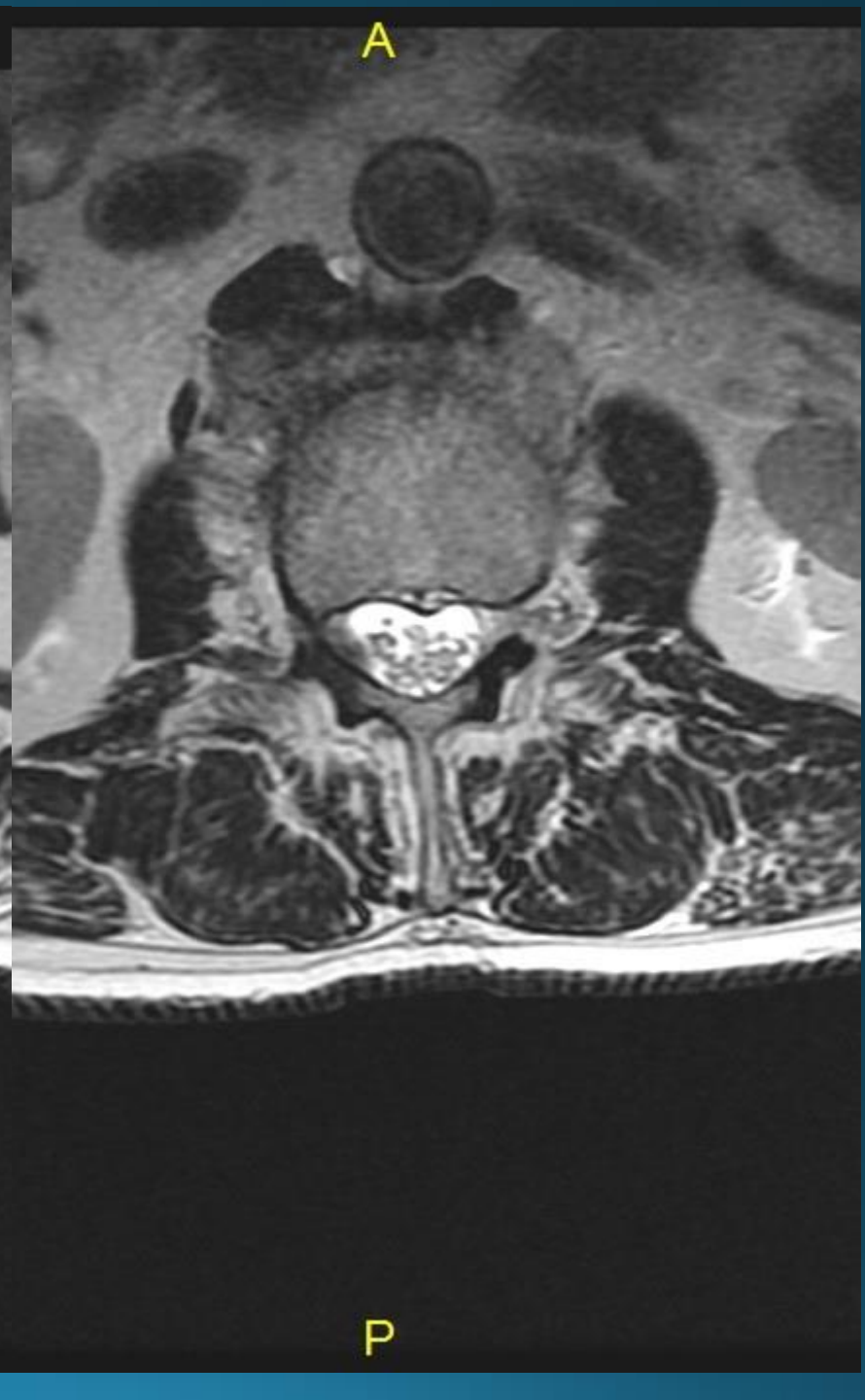
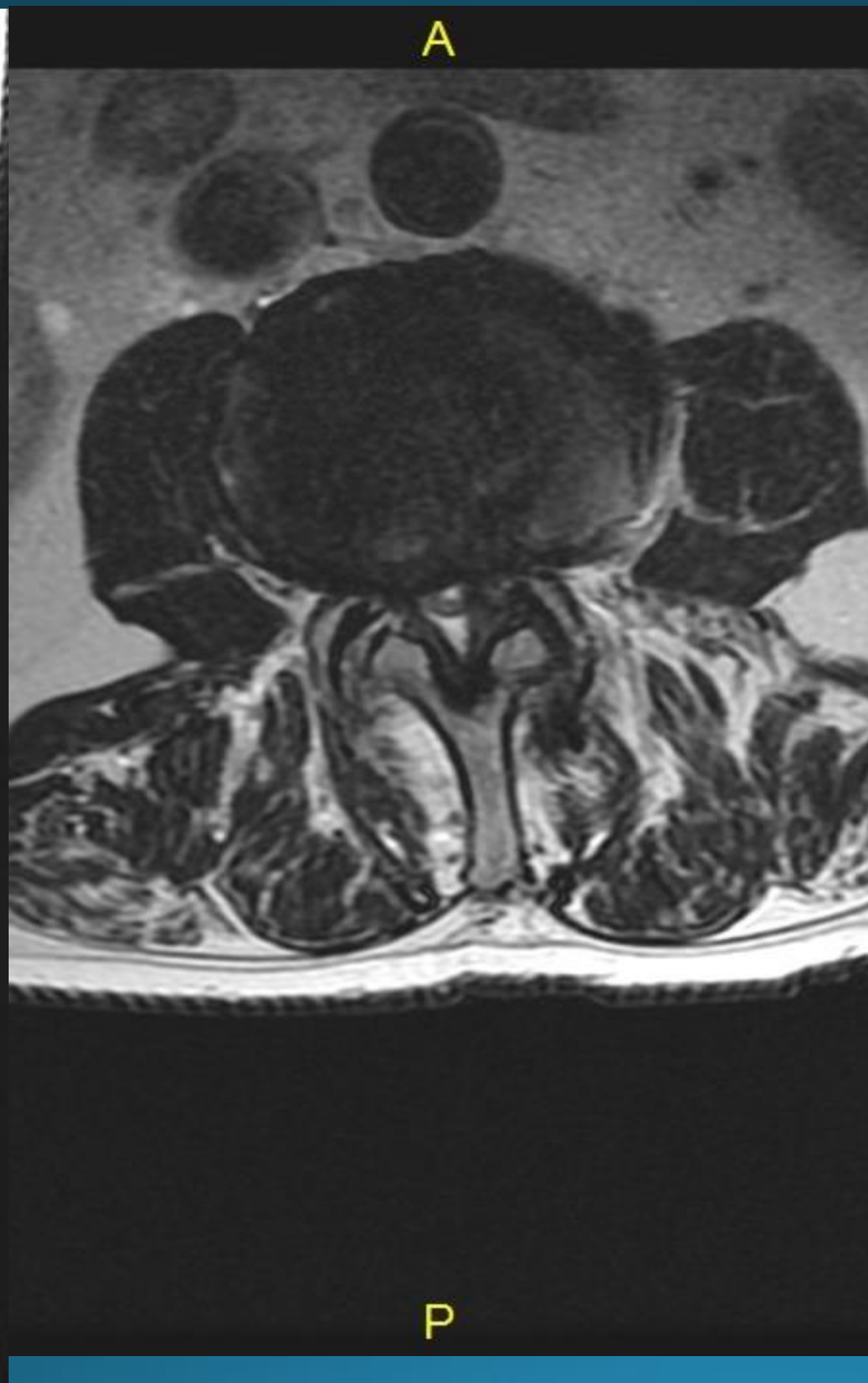
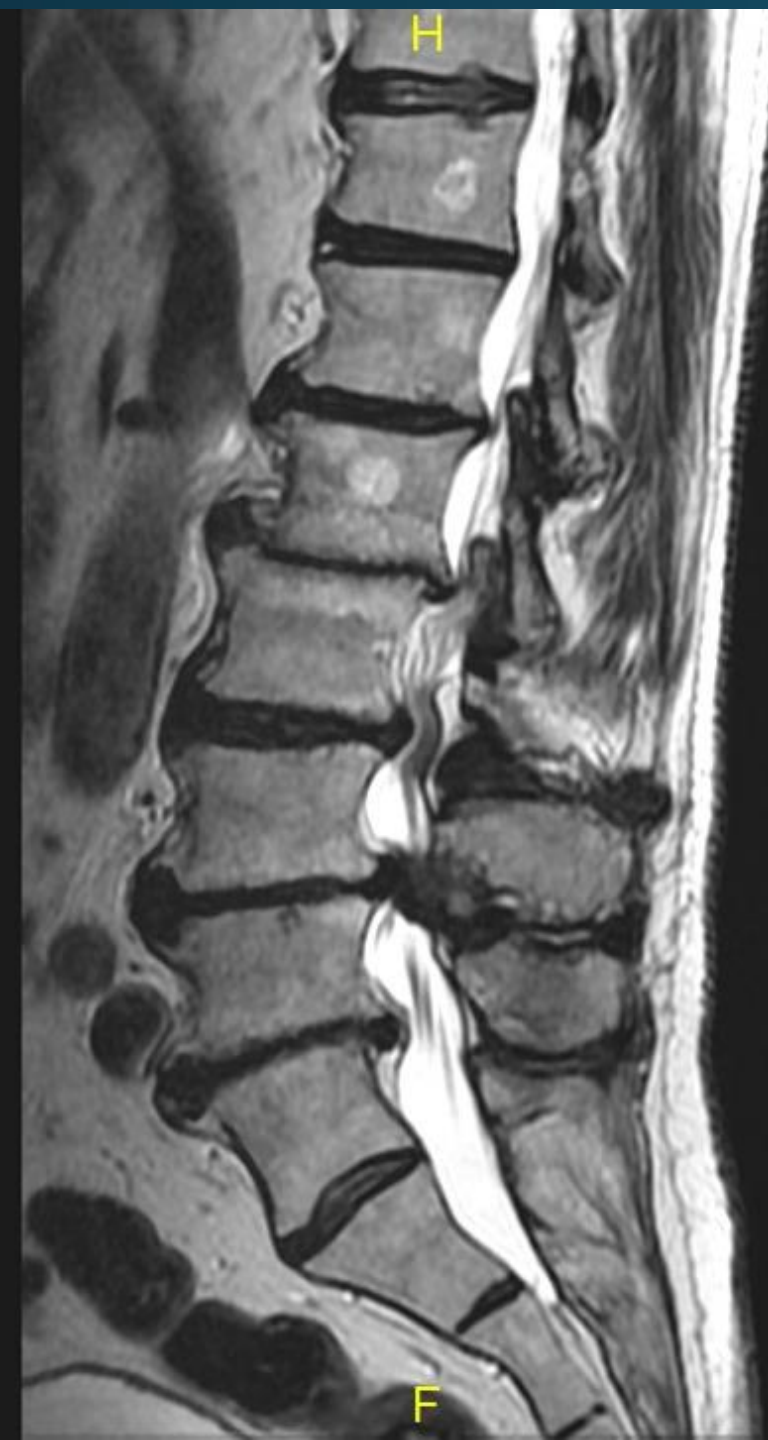





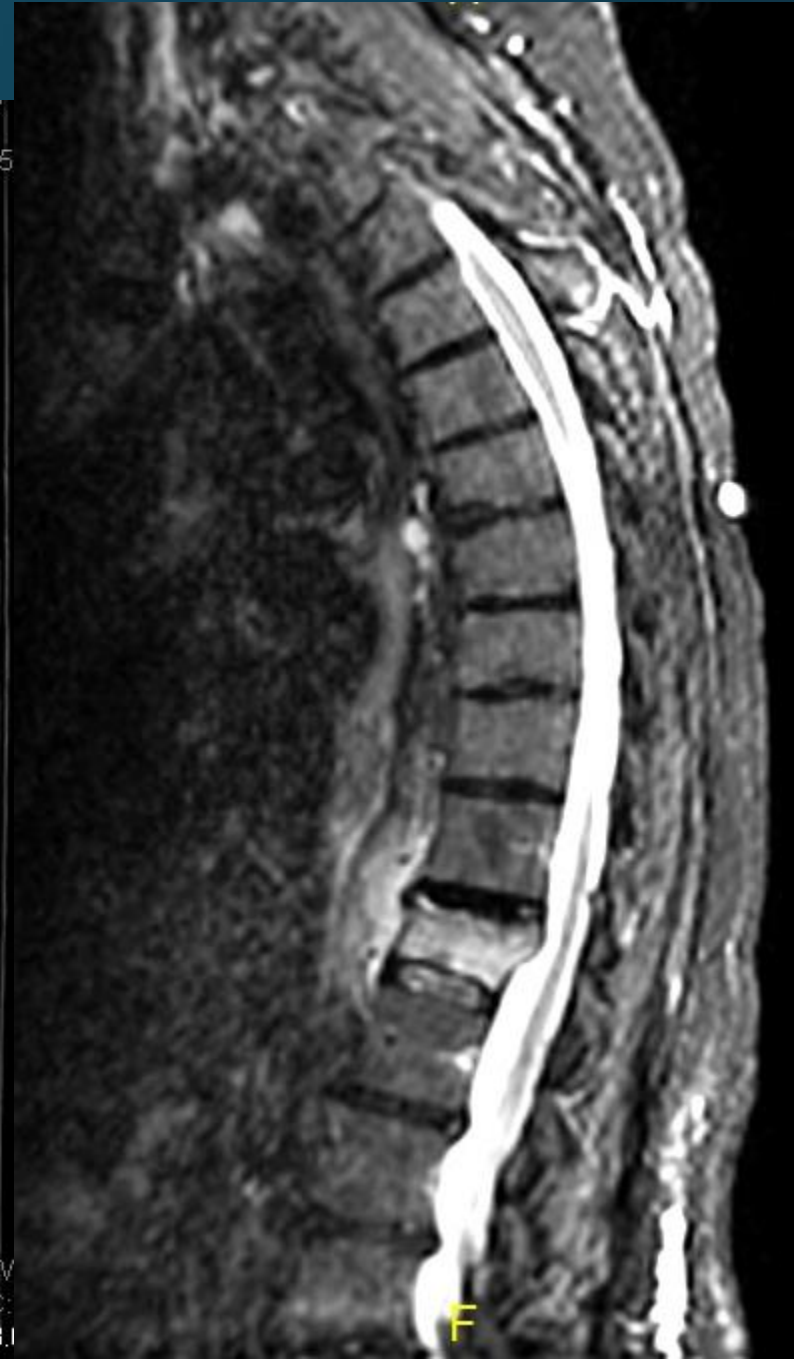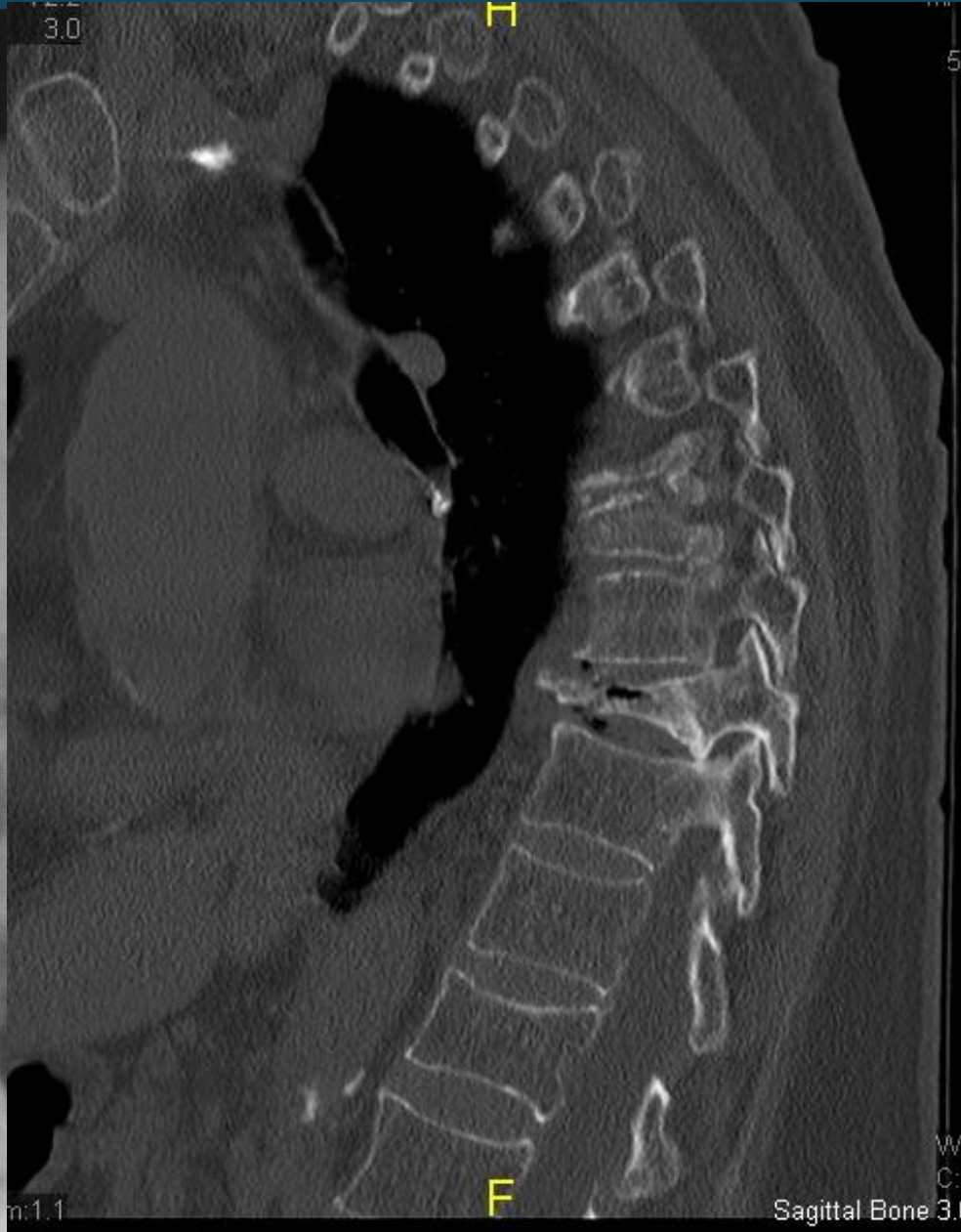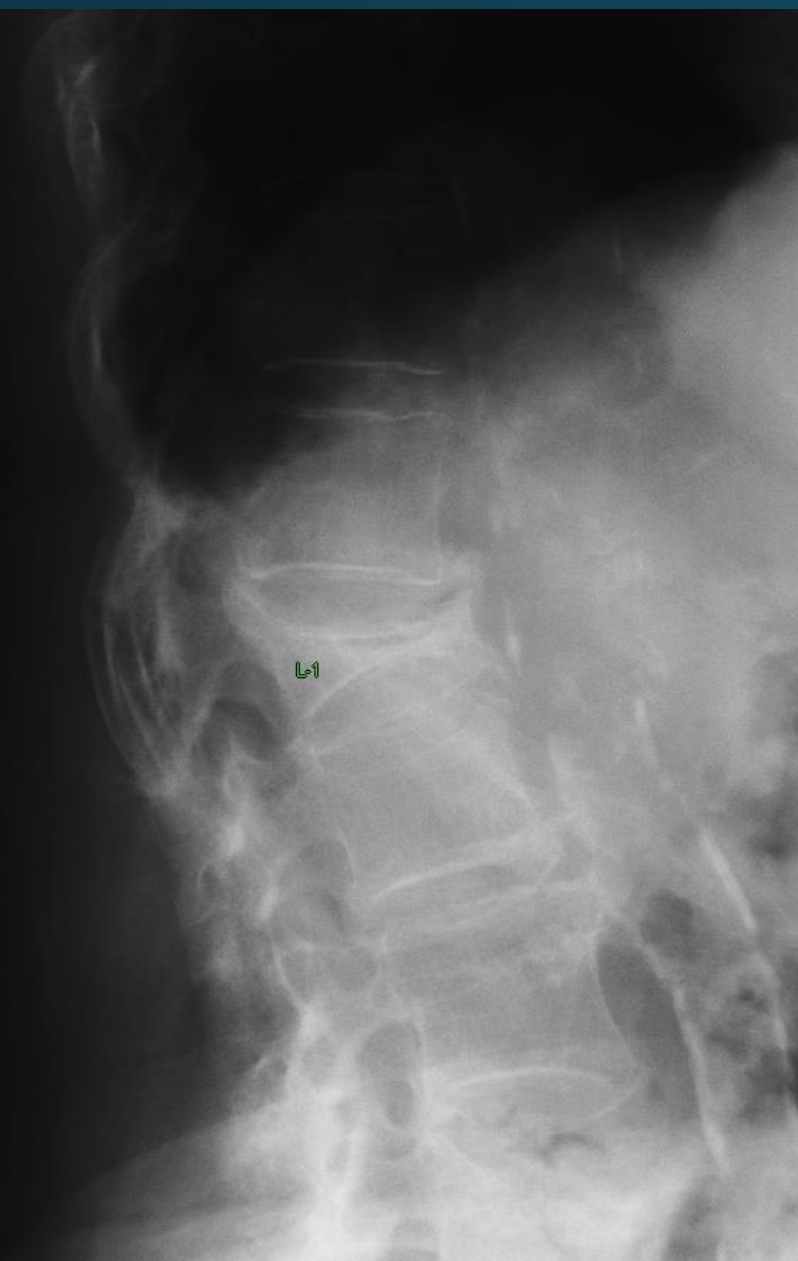








# Compression fractures on x-ray, CT, and MRI



Current

09-07-2011  
09:42 AM

LT

Don't forget other things that  
can mimic spine pain

W:2349  
C:1842

10:46 AM

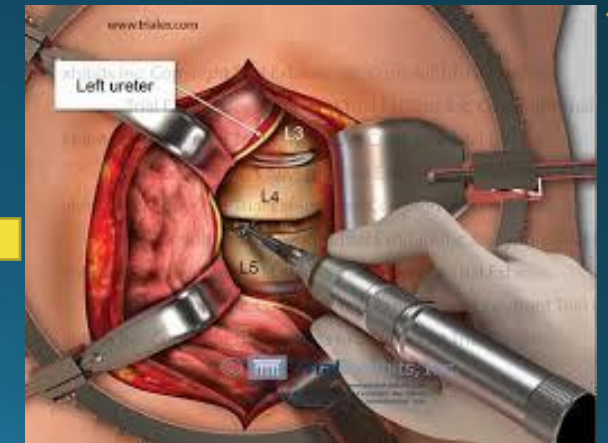
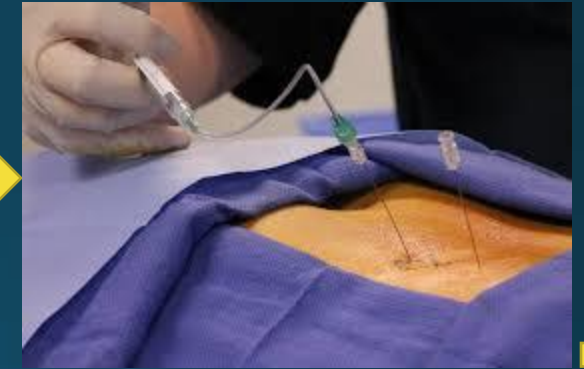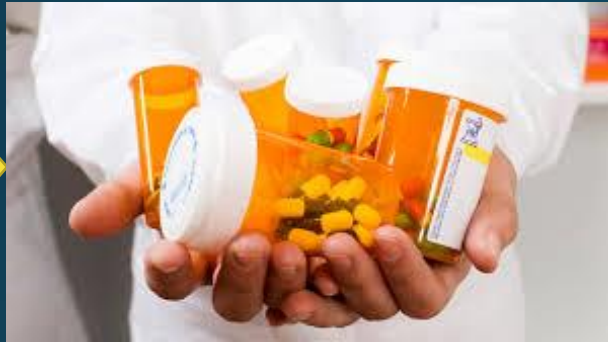UPRIGHT

W:3955  
C:2536



# Treatment Options

- Treatment for lumbar spine pathology can vary significantly based on the pathology. Overwhelmingly most low back complaints can be treated non-operatively.






## Red Flags

- Pain that doesn't get better when lying down/resting.
- Pain associated by systemic symptoms of inflammation (e.g. fever, chills), in particular in those at risk for systemic infection that could seed the spinal area (e.g. IV drug users, patients with bacteremia).
- Known history of cancer, in particular malignancies that metastasize to bone (e.g. prostate, breast, lung).
- Trauma, particularly if of substantial force.
- Osteoporosis, which increases risk of compression fracture (vertebrae collapsing under the weight they must bear). More common as people age, women > men.
- Anything suggesting neurological compromise. In particular, weakness in legs suggesting motor dysfunction. Also, bowel or bladder incontinence, implying diffuse sacral root dysfunction. Note: it can sometimes be difficult to distinguish true weakness from motor limitation caused by pain.


Pain referred to the back from other areas of the body (e.g. intra-abdominal or retroperitoneal processes). Could include: Pyelonephritis, leaking/rupturing abdominal aortic aneurysm, posterior duodenal ulcer, pancreatitis, etc.





# References and Guidelines

- North American Spine Society
- <https://www.spine.org/Portals/o/Documents/ResearchClinicalCare/Guidelines/NASSLBPClinicalQuestions.pdf>
- American Academy Orthopedic Surgery
- <http://orthoinfo.aaos.org/topic.cfm?topic=a00311>

A photograph of a sandy beach with gentle waves washing onto the shore. The water is a light blue-green color, and the sand is a pale yellow. In the foreground, the words "THANK YOU" are written in the sand in a simple, hand-drawn style. The text is positioned in the lower half of the frame, below the water's edge. The overall mood is peaceful and appreciative.

THANK YOU