

**TINEA**

**OR**

**NOT**

GINA MANGIN, MPAS, PA-C

# DISCLOSURES

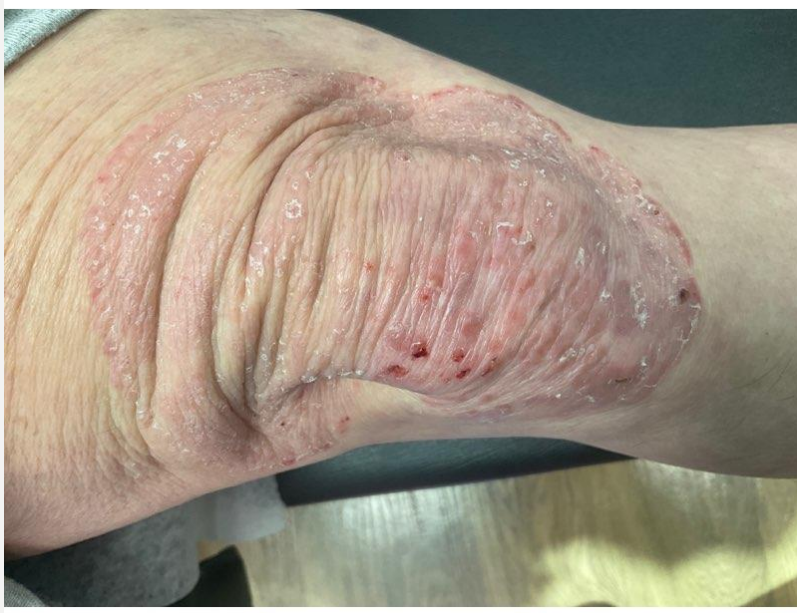- Speaker for Abbvie
- Speaker for Regeneron Sanofi- Genzyme
- Speaker for Dermavant
- Ad Board Consultant for Arcutis
- Ad Board Consultant for Amgen
- Ad Board Consultant for Bristol Myers
- Ad Board Consultant for Lilly
- Ad Board Consultant for Johnson and Johnson
- Ad Board Consultant for Incyte
- Ad Board Consultant for Leo

# LEARNING OBJECTIVES

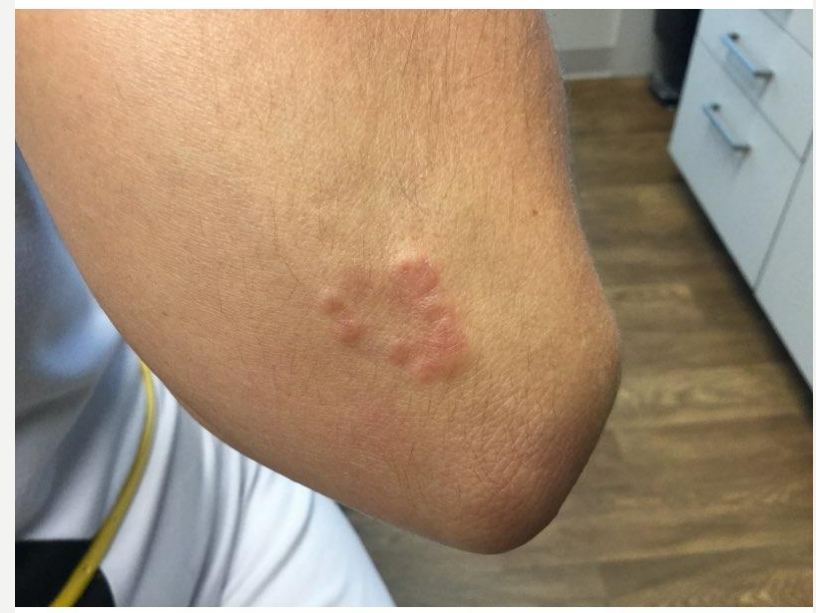- Recognize the different presentation of tinea on the skin
- List a DDX for tinea on the skin
- Describe the clinical features for tinea skin infections
- Discuss the proper treatment and length of treatment for specific tinea infections of the skin and nails
- Clarify the different KOH presentations with tinea skin infections

# 1. WHICH ONE IS TINEA?

**A**

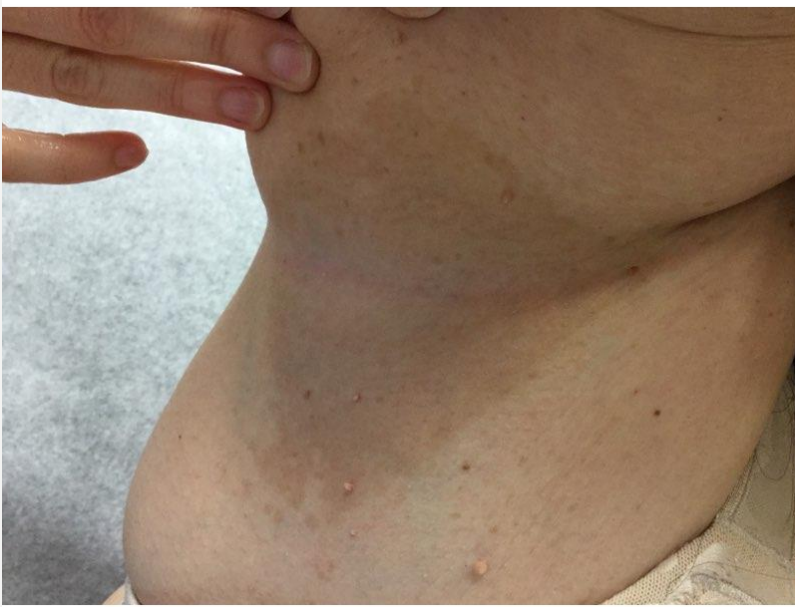

**B**

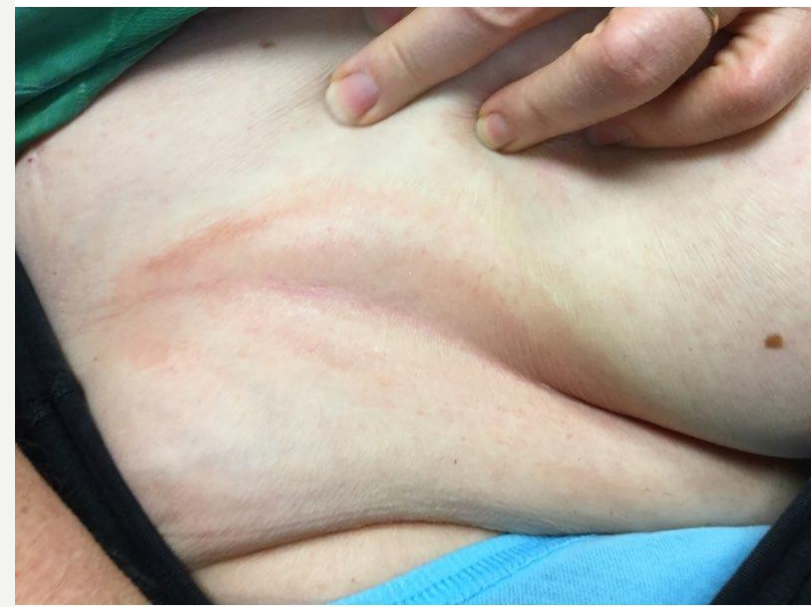

## 2. WHICH ONE IS TINEA ?

A

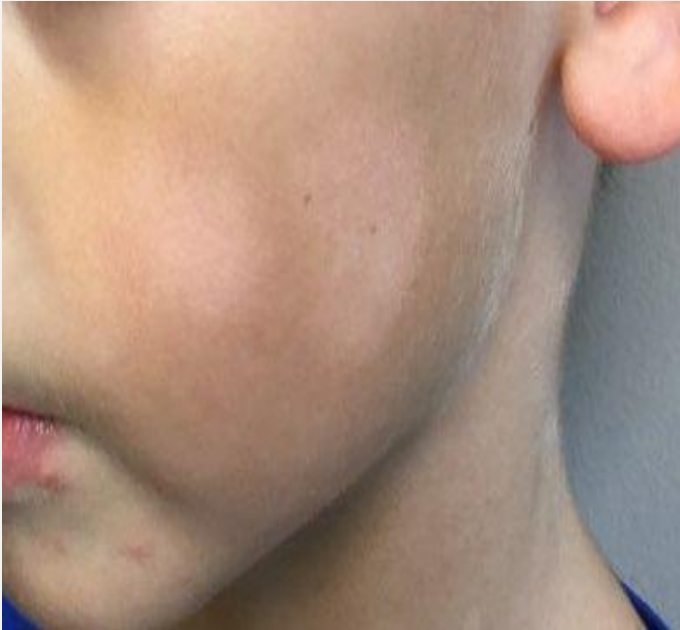

B

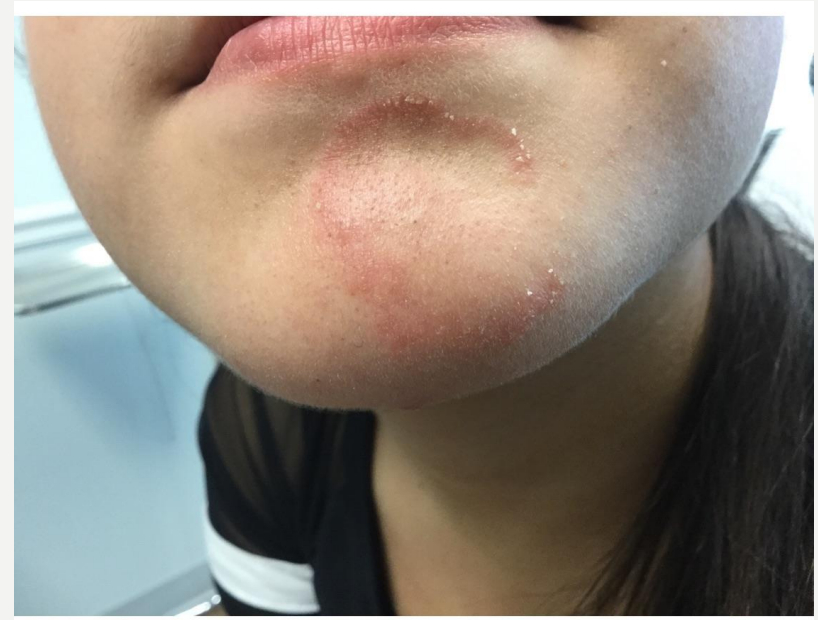

### 3. WHICH ONE IS TINEA ?

A



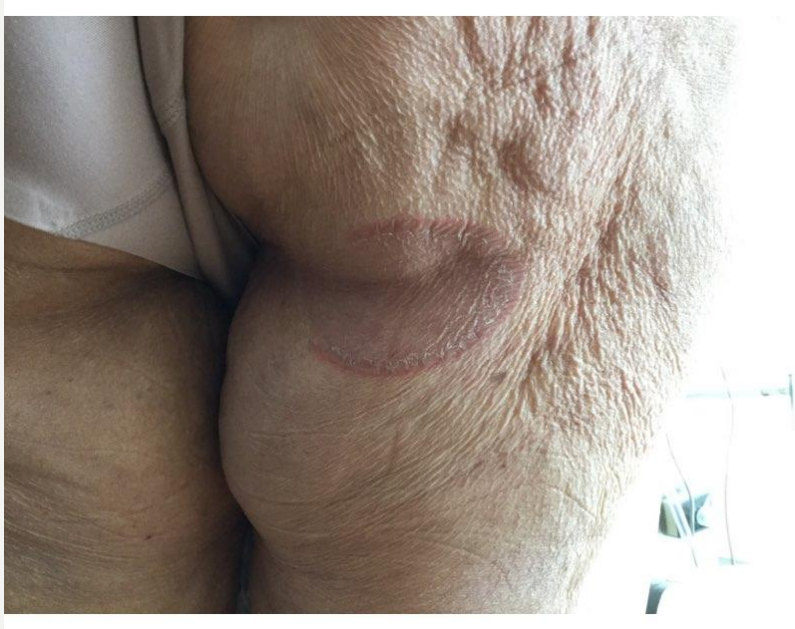B



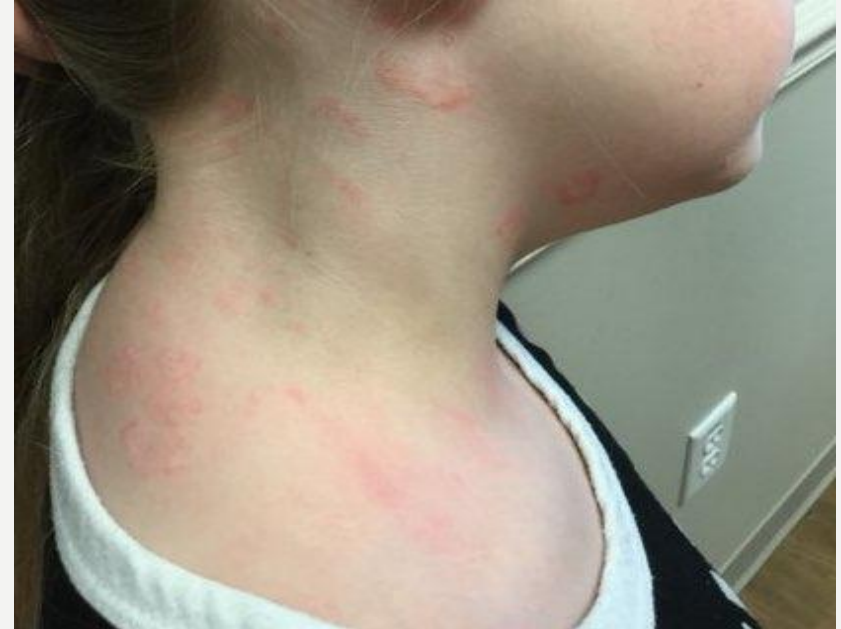

## 4. WHICH IS TINEA ?

**A**

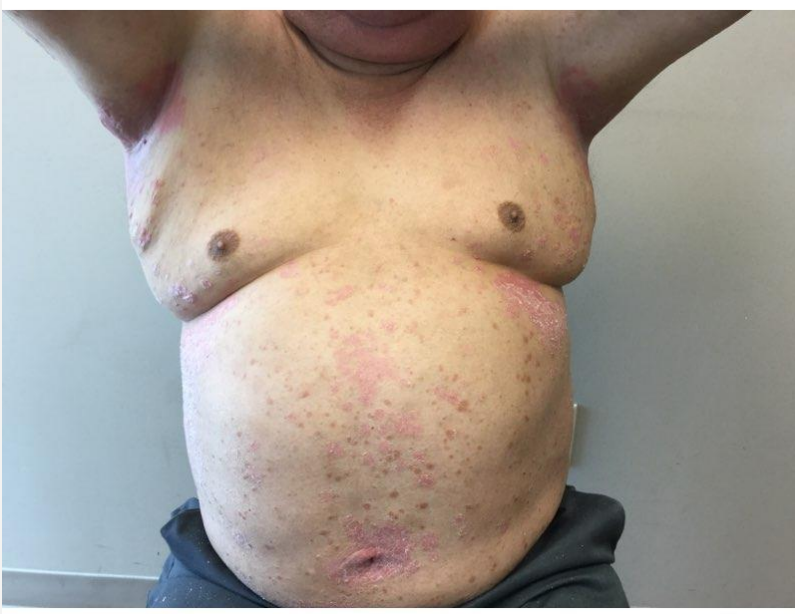

**B**

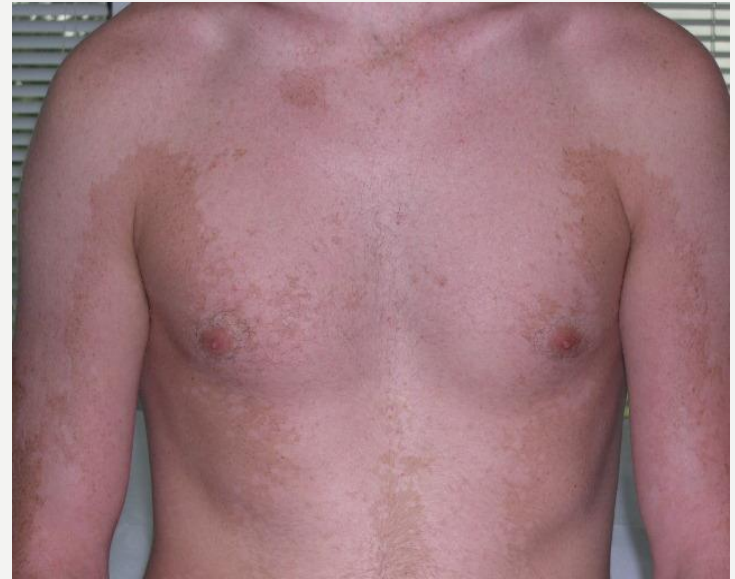

# 5. WHICH IS TINEA?

**A**



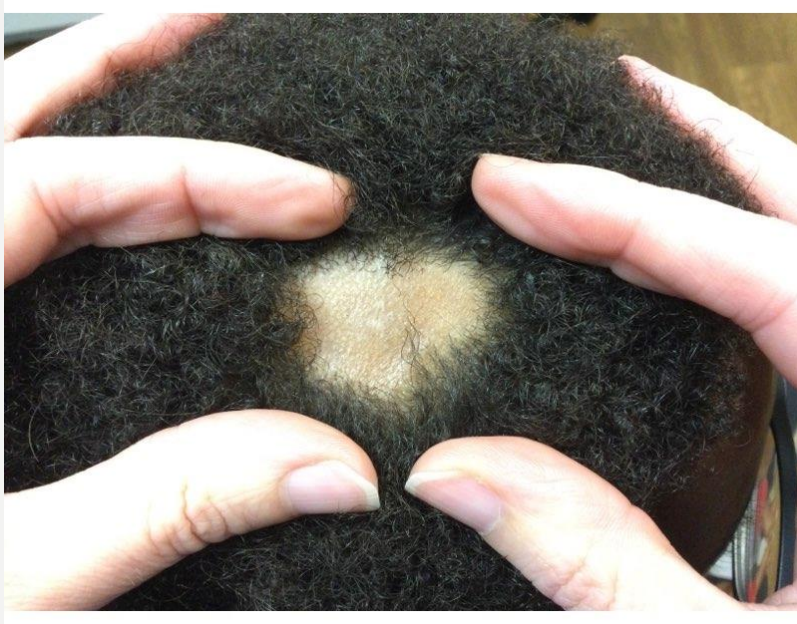**B**



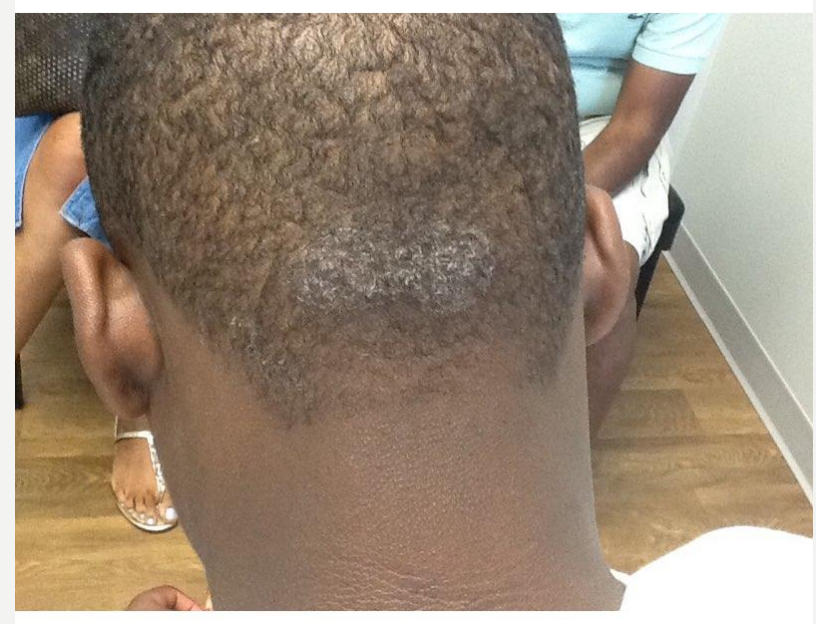

## 6. WHICH IS TINEA?

**A**

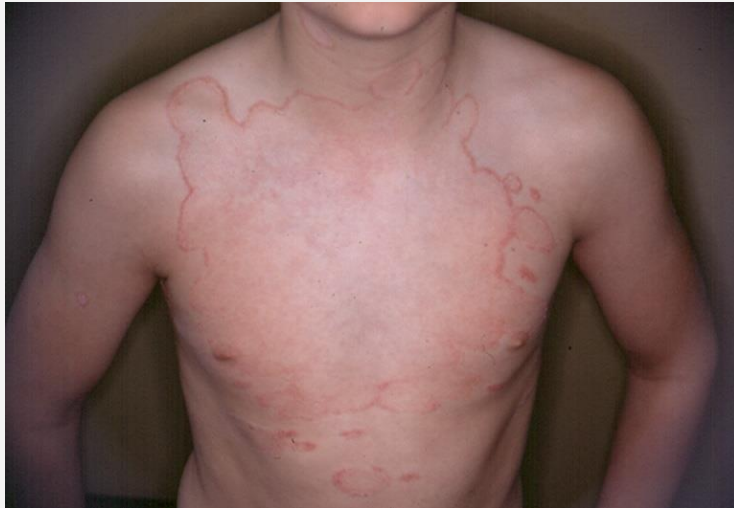

**B**

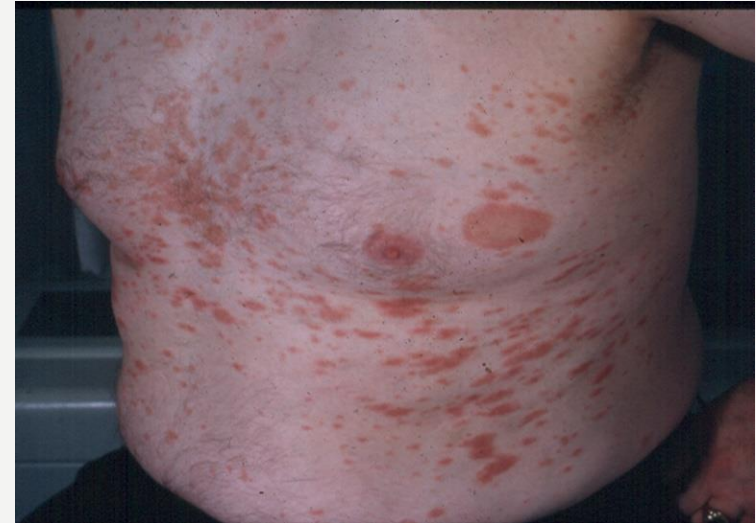

# 7. WHICH IS TINEA?

**A**

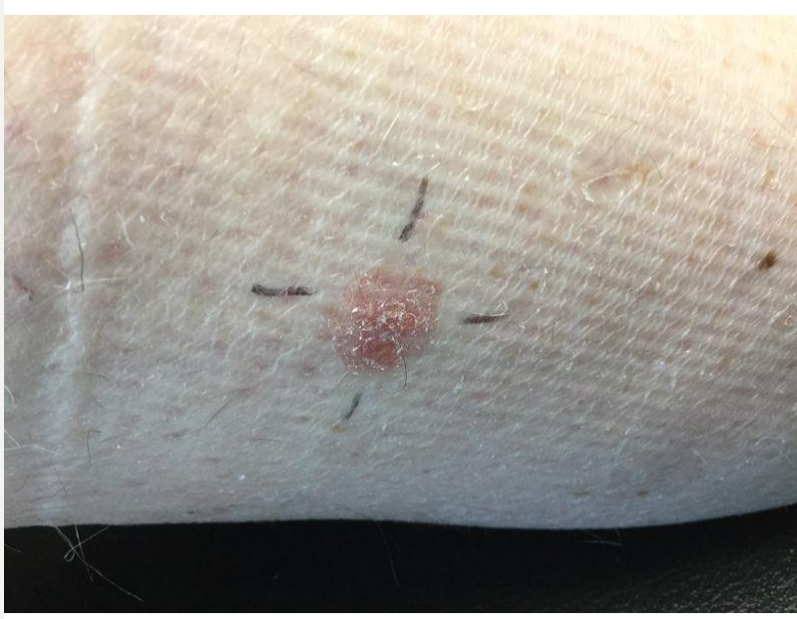

**B**

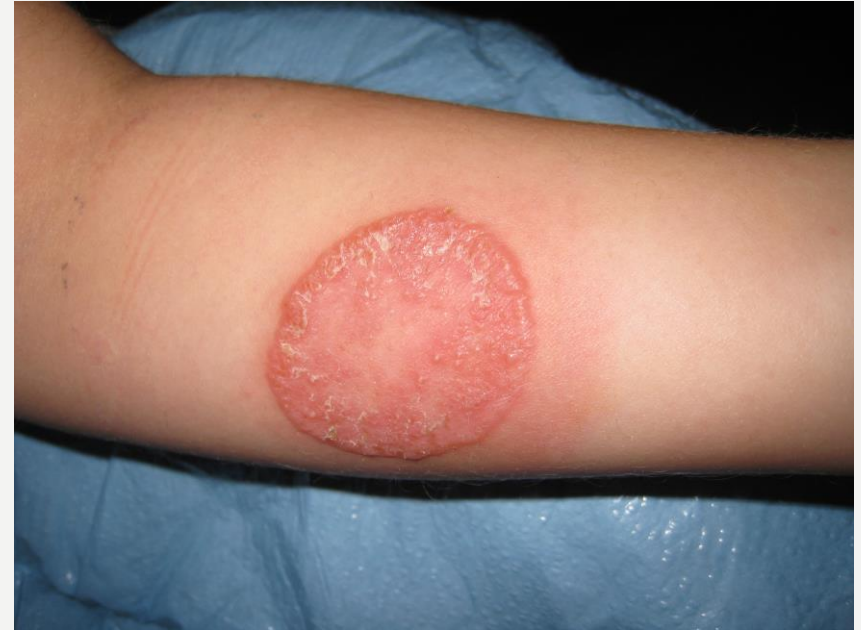

## 8. WHICH IS TINEA?

A



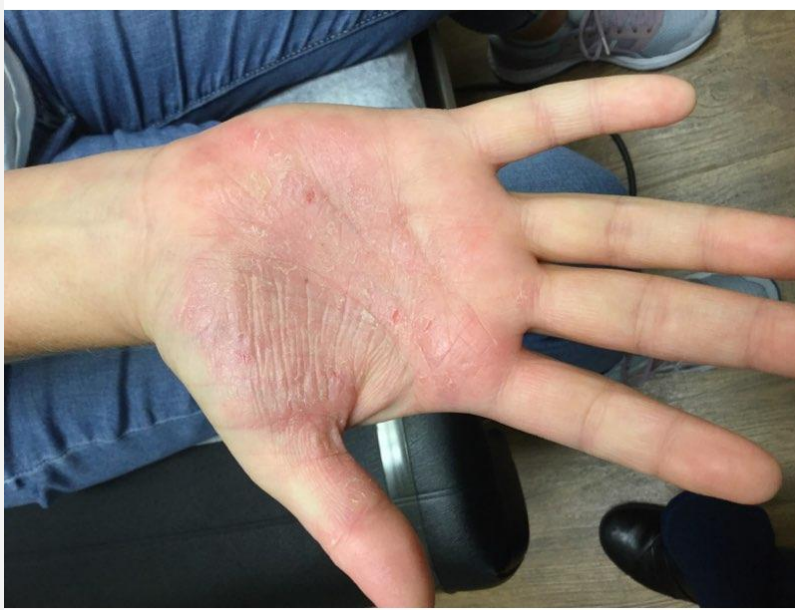B



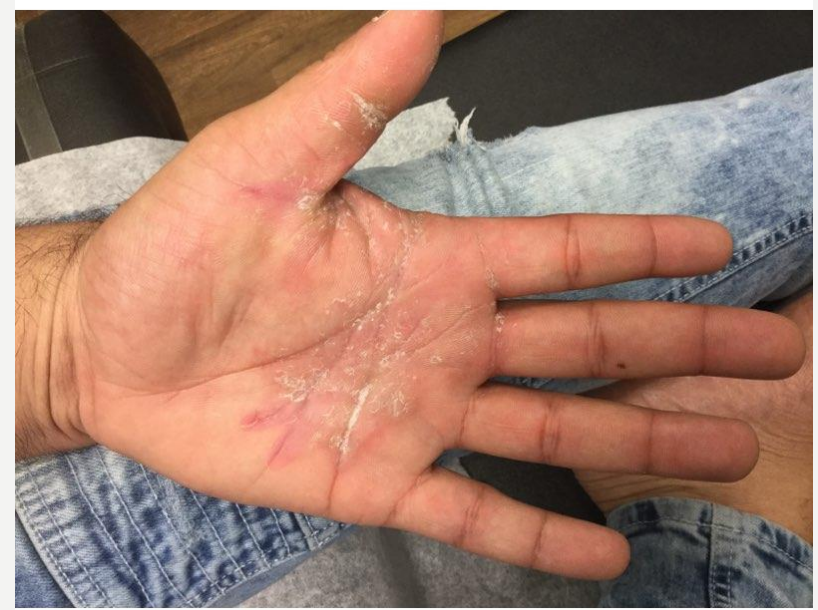

# 9. WHICH ONE IS TINEA?

**A**

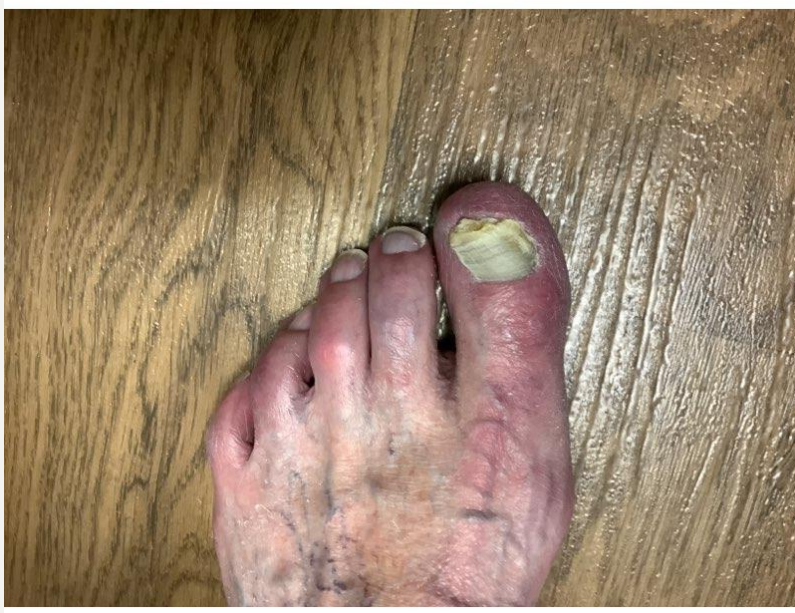

**B**

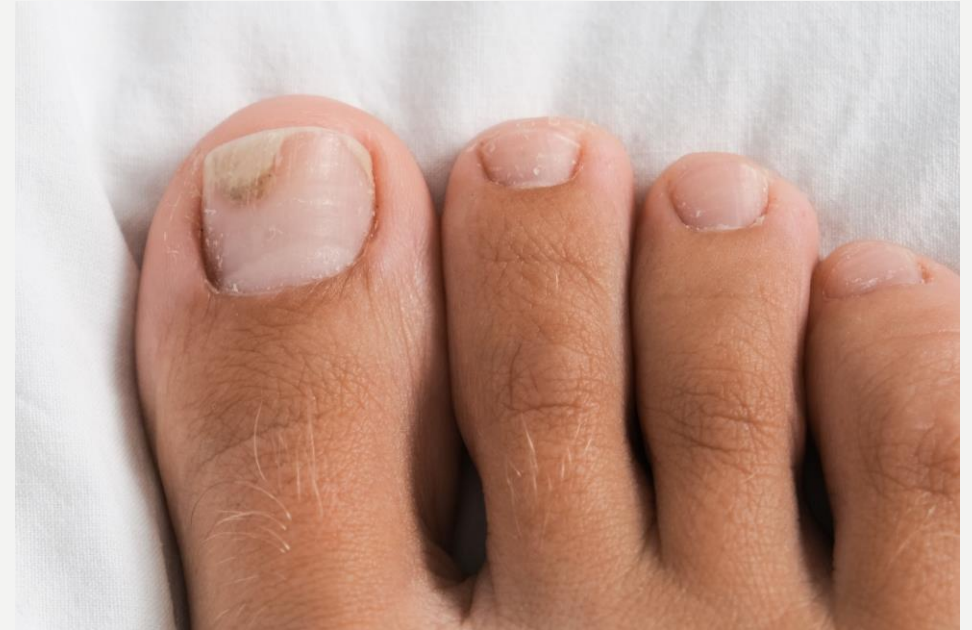

# 10. WHICH ONE IS TINEA?

A

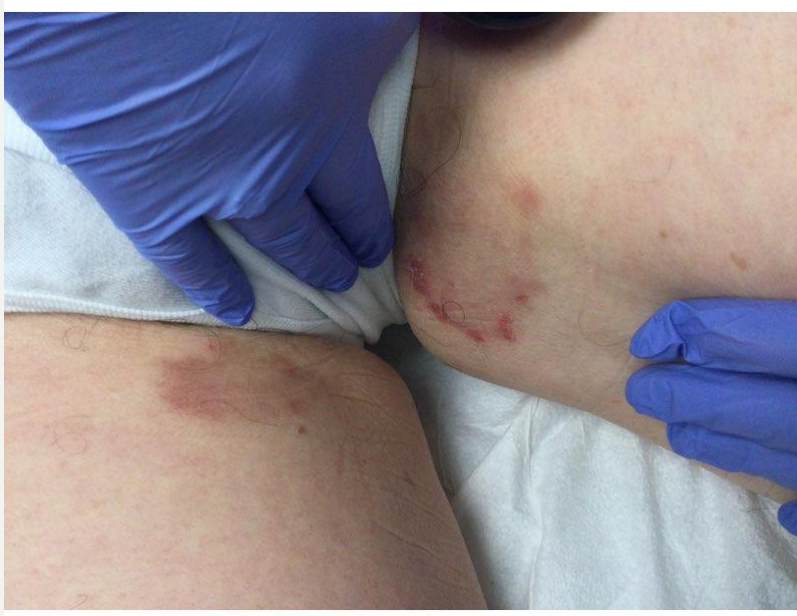

B

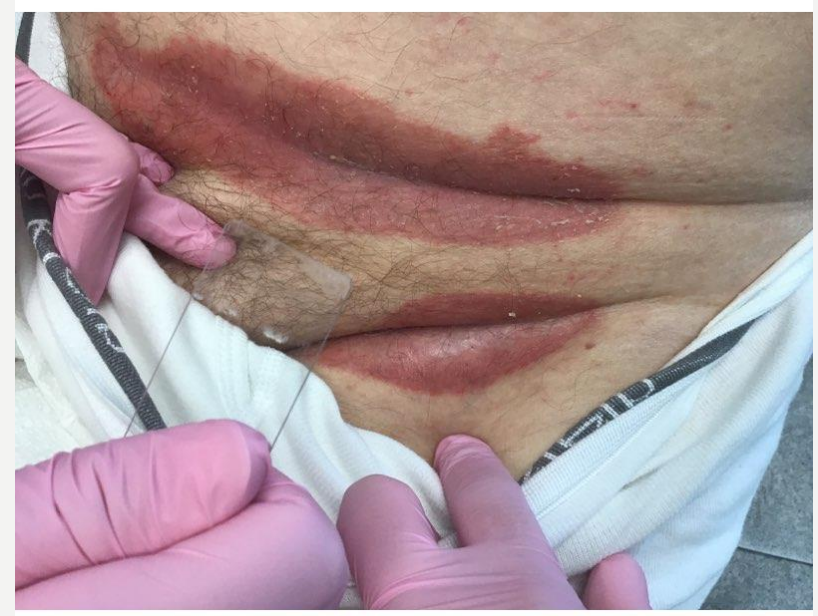

# 11. WHICH IS TINEA ?

**A**



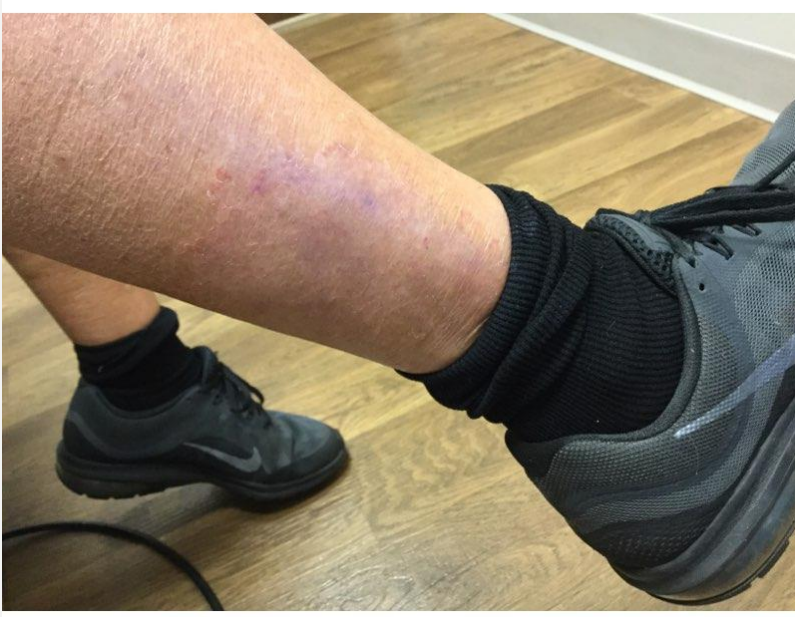**B**



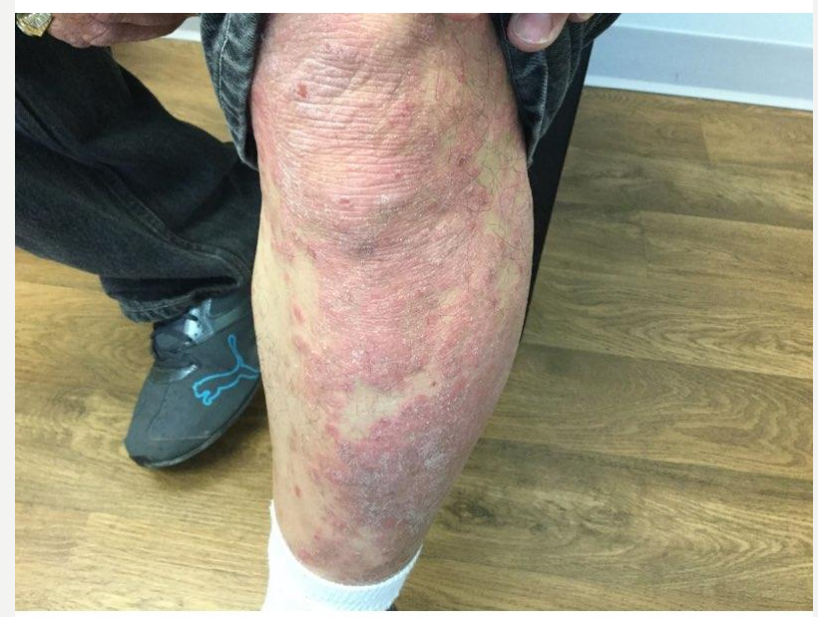

# 12. WHICH IS TINEA ?

A



B



# BODY AREAS

- Tinea Corporis- Body
- Tinea Capitis- Scalp
- Tinea Pedis- Foot
- Tinea Cruris- Groin/Jock Itch
- Tinea Manuum – Hand ( One hand two feet )
- Tinea Unguium- Nails ( onychomycosis)
- Tinea Faciei- Face
- Tinea Incognito/Majocchi's Granuloma
- Tinea Versicolor- pityriasis versicolor

# CAUSES

- Trichophyton
  - *T. Rubrum* ( *most common world wide*)
  - *T. Tonsurans* ( *most common in US*)
- Microsporum ( *most common North Africa and Europe*)
- Malassezia
  - Pityriasis Versicolor ( *Tinea versicolor*)

# RISKS

- Diabetes
- Immunocompromised
- Pets
  - Kittens
- House Crowding/close contact
  - Siblings sharing grooming tools
  - Wrestlers

# DDX

- Erythema Annulare Centrifugum (EAC)
- Granuloma Annulare (GA)
- Eczema/Irritant Dermatitis
- Psoriasis
- Macular Amyloidosis
- Pityriasis Alba
- Pityriasis Rosacea
- Alopecia Areata
- Erythrasma
- Squamous Cell carcinoma

# TOOLS TO MAKE THE DX

- KOH ( Potassium Hydroxide 20%) Prep
- DTM ( Dermatophyte Test media) /Fungal Culture
- Punch Biopsy /Periodic acid-Schiff (PAS) Stain
- Woods Lamp

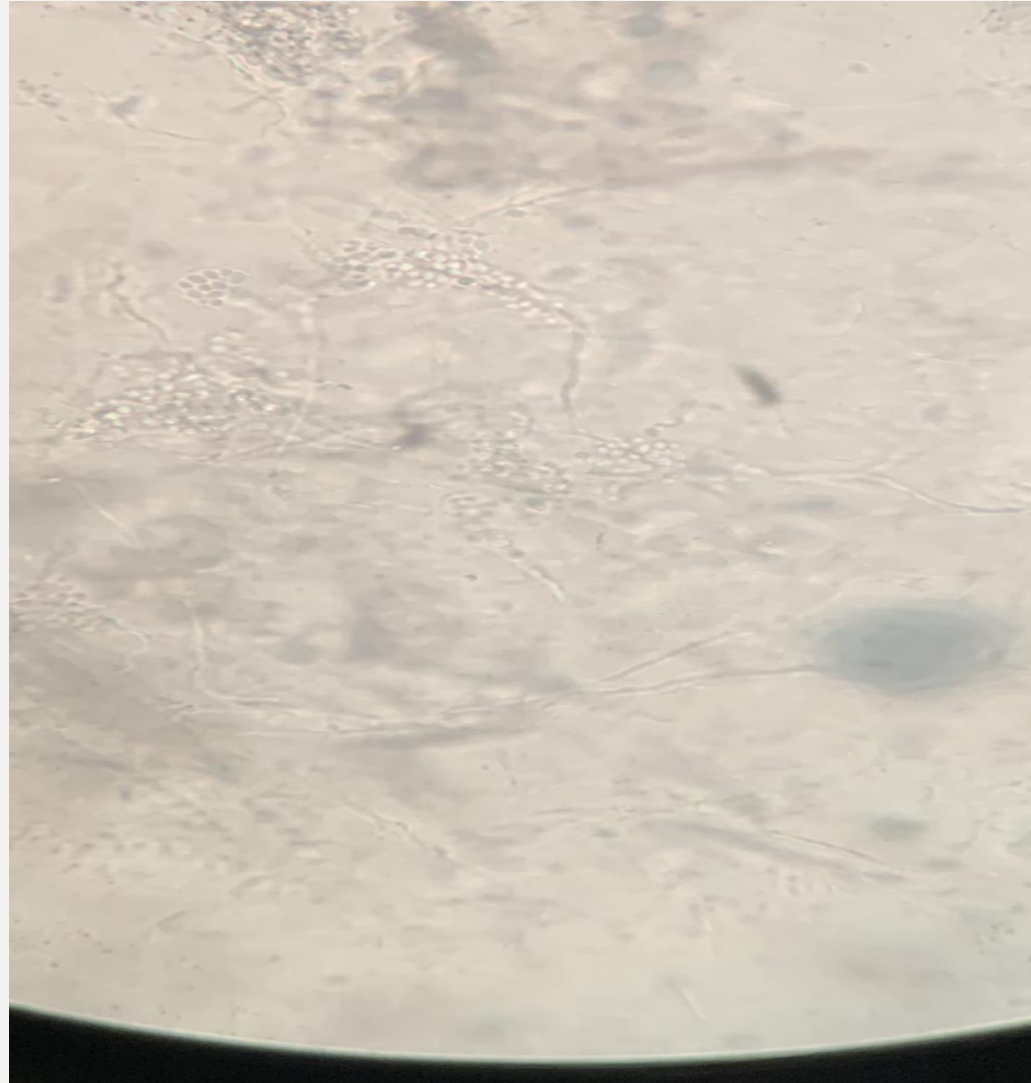


# DTM



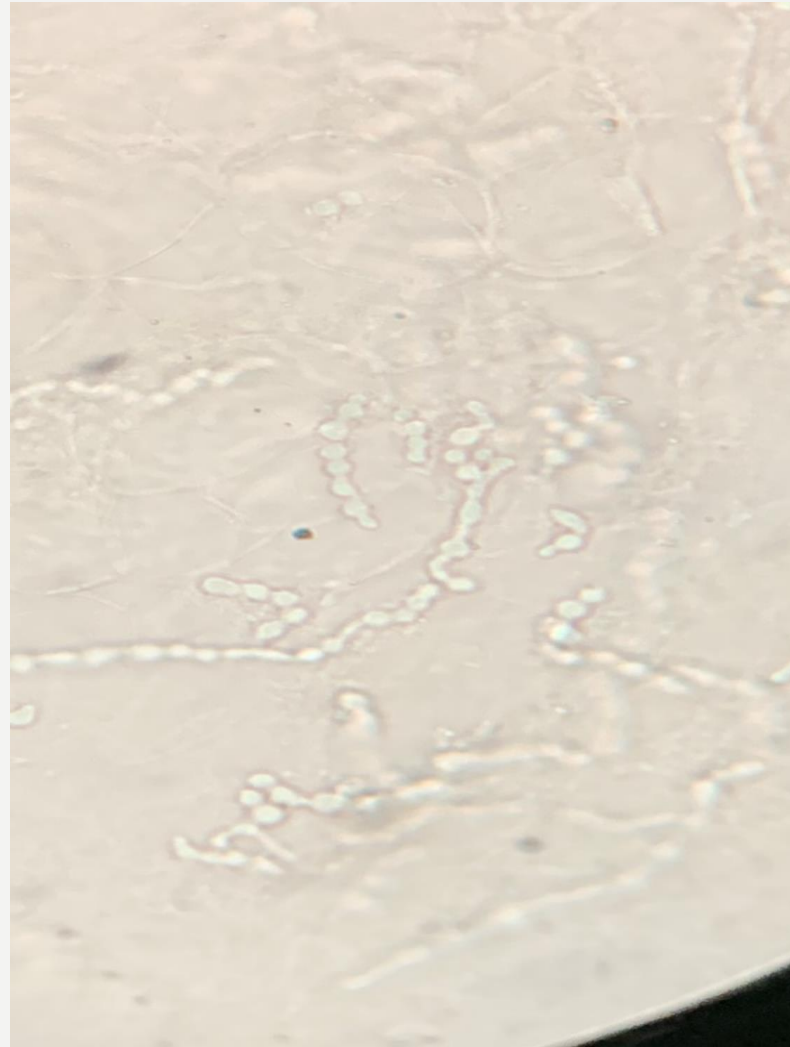
# **POSITIVE KOH**

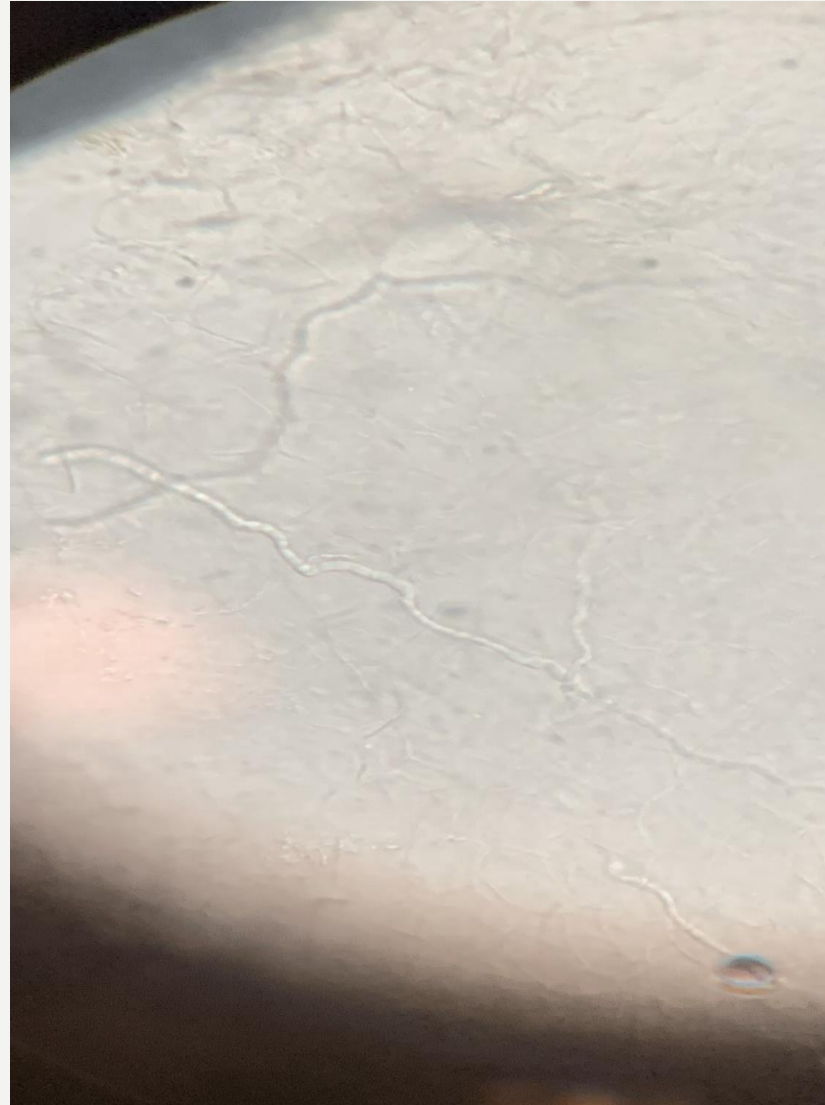
## **BUDDING YEAST AND BRANCHING HYPHAE**



# POSITIVE KOH

## BRANCHING HYPHAE





# TREATMENTS

## SUPERFICIAL :TOPICALS

- Imidazoles- Mostly Fungistatic
  - Ketoconazole
  - Clotrimazole
  - Econazole
- Allylamines- Fungicidal
  - Naftifine
  - Terbinafine
- Benzylamine- Fungistatic
  - Butenafine

4;(8):CD009992.

Cochrane Database Syst Rev. 2014 Aug

Adv Skin Wound Care. 2019 Aug;32(8):350-357.

# **ORAL TREATMENTS**

## **HAIR, NAILS, EXTENSIVE SKIN**

- Terbinafine
- Itraconazole
- Griseofulvin

Cochrane Database Syst Rev. 2014 Aug 4;(8):CD009992.  
Adv Skin Wound Care. 2019 Aug;32(8):350-357.



Apple ChromeFile Edit View History Bookmarks Profiles Tab Window Help






Liver injury associated with ket


FDA Drug Safety Podcast: FDA


+


← → ↺


fda.gov/drugs/fda-drug-safety-podcasts/fda-drug-safety-podcast-fda-warns-prescribing-nizoral-ketoconazole-oral-tablets-unapproved-uses#:~:text=In%20a%2...



 An official website of the United States government [Here's how you know](#)

 **U.S. FOOD & DRUG**  
ADMINISTRATION


 Search


 Menu


[← Home](#) / [Drugs](#) / [Drug Safety and Availability](#) / [FDA Drug Safety Podcasts](#)


[/ FDA Drug Safety Podcast: FDA warns that prescribing of Nizoral \(ketoconazole\) oral tablets for unapproved uses including skin and nail infections continues; linked to patient death](#)


# FDA Drug Safety Podcast: FDA warns that prescribing of Nizoral (ketoconazole) oral tablets for unapproved uses including skin and nail infections continues; linked to patient death

 Share

 Tweet

 LinkedIn

 Email

 Print

FDA Drug Safety Podcasts

Listen

Content current as of:

01/20/2022

Welcome to FDA Drug Safety Podcasts for health care professionals. This is Karla Waters, Consumer Safety Officer from the Division of Drug Information.

On May 19, 2016, FDA announced it is warning health care professionals to avoid prescribing the antifungal medicine ketoconazole oral tablets to treat skin and nail fungal infections. Use of this medication carries the risk of serious liver damage, adrenal gland problems, and harmful interactions with other medicines that outweigh its benefit in

DEC

6

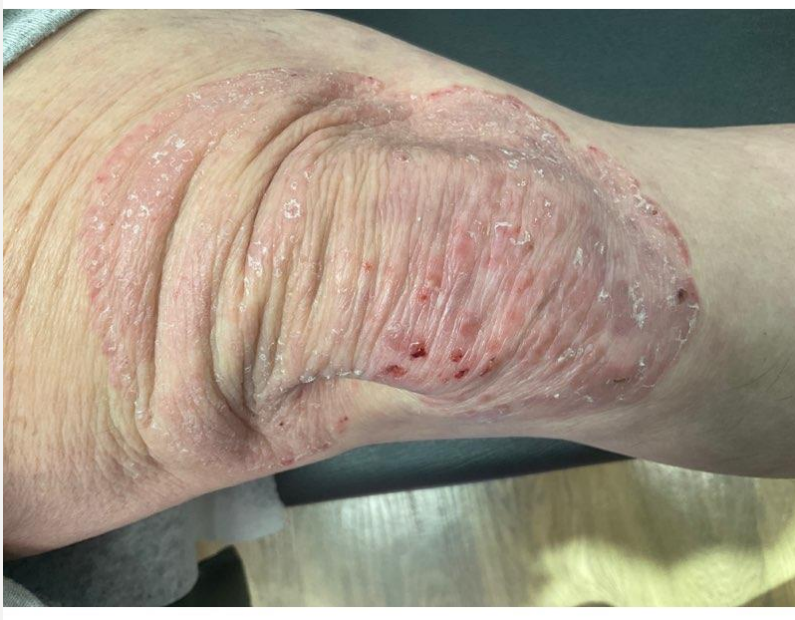6

1

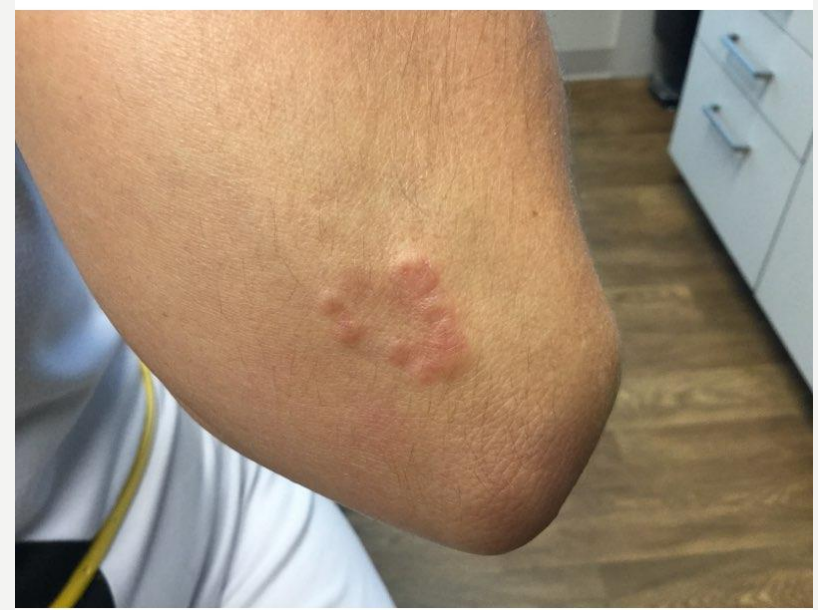2022-10-12 2:20 PM

# 1. WHICH ONE IS TINEA?

**A**



**B**



A

## TINEA CORPORIS

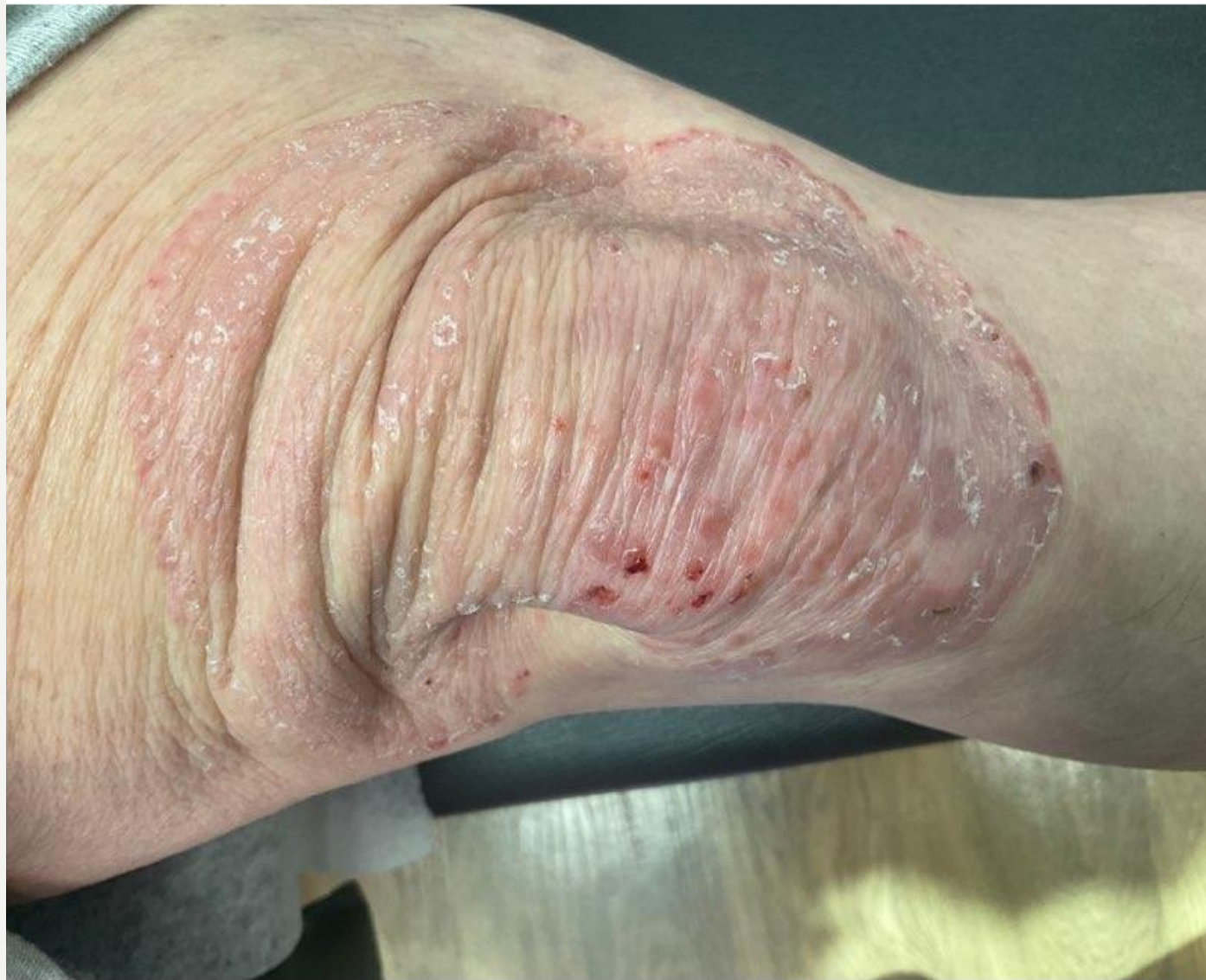45 y/o female presented with a rash for 4-5 months

Applying OTC hydrocortisone with some improvement

Taking oral prednisone for arthritis

Area is mildly itchy

KOH +, treated with oral terbinafine and topical ketoconazole



# TINEA CORPORIS

- Erythematous circular Sharply Circumscribed Plaques or Patches
- Scaling
- Raised edge with CENTRAL CLEARING
  - Spreads centrifugally

# TINEA CORPORIS

## Localized:Topicals

Terbinafine 1% daily for 6 weeks

Natifidine 1%

Butenafine 1%

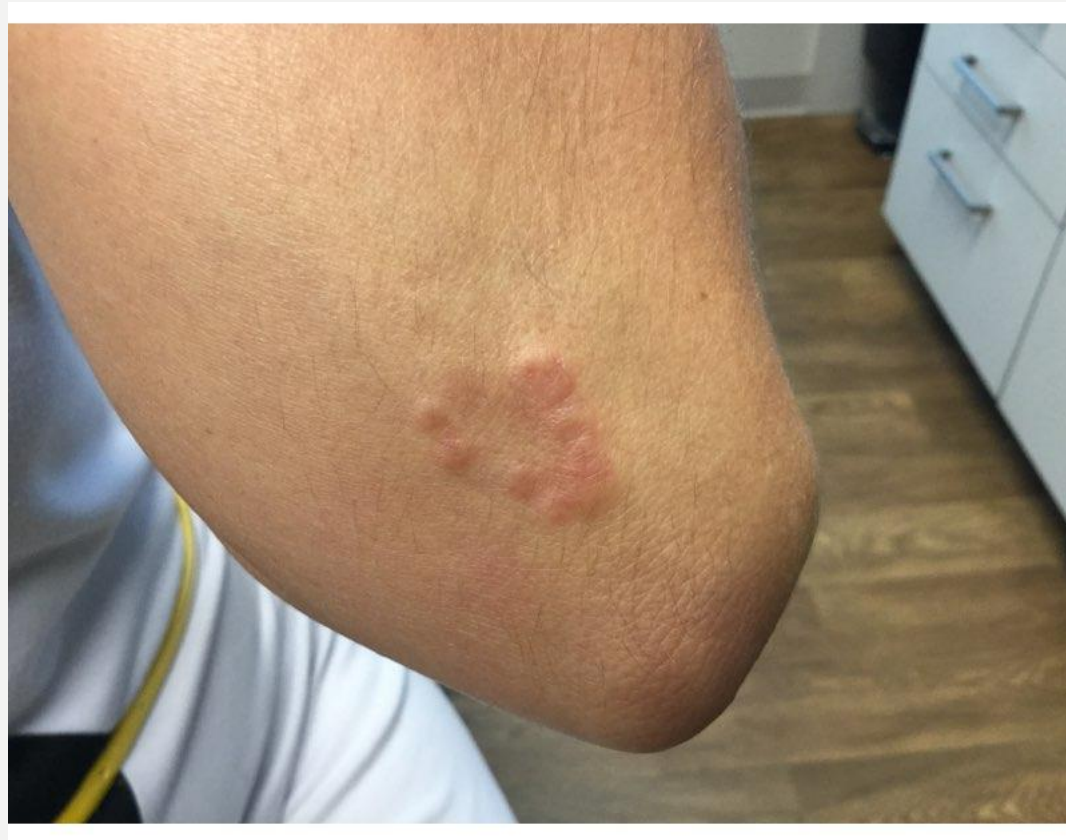Ketoconazole 2%

Miconazole

Clotrimazole

\*\*\*Avoid Clotrimazole/Betamethasone- can cause fungal folliculitis/tinea incognito





## GRANULOMA ANNULARE

40 y/o female presents with a 5  
month history of rash

NOT ITCHY

Treated by her PCP with  
Ketoconazole AND Terbinafine  
with NO improvement



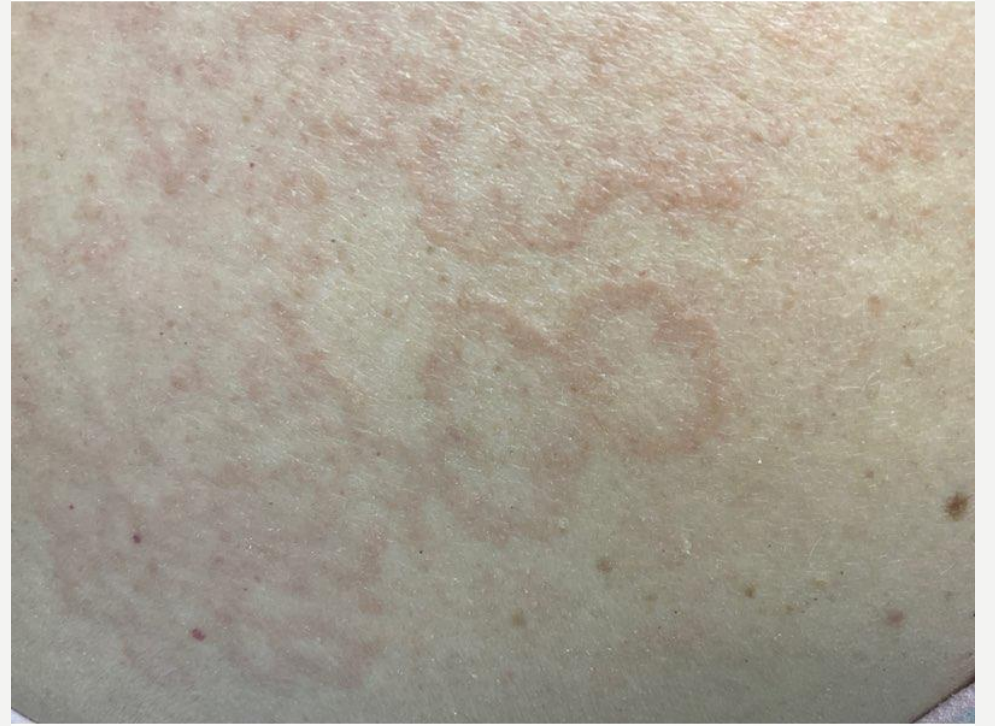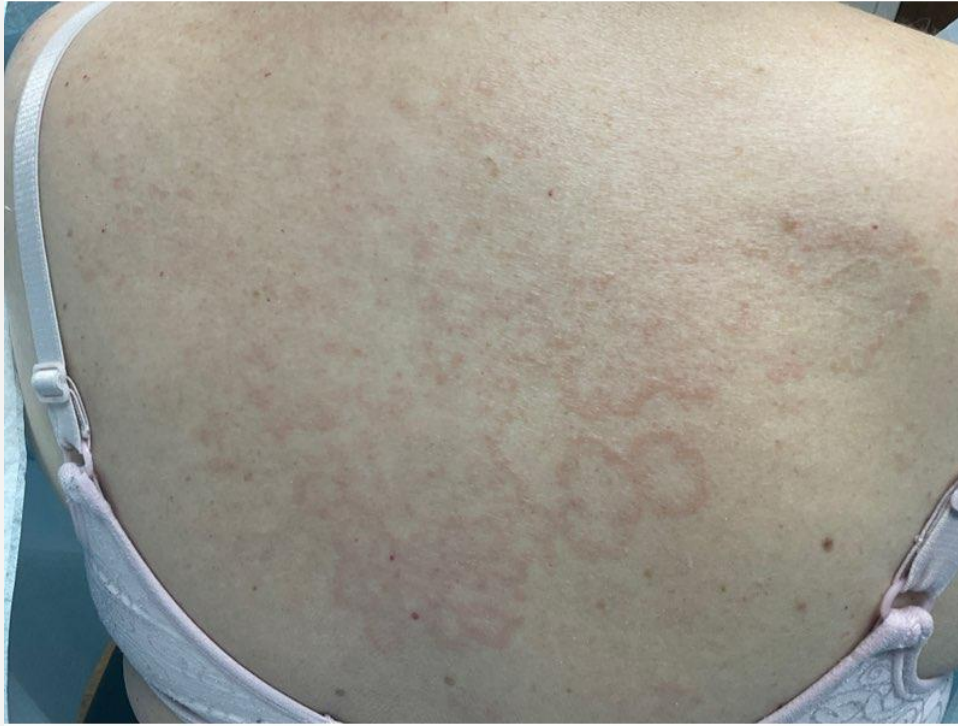# GRANULOMA ANNULARE

- Delayed hypersensitivity reaction in the dermis
- Localized (hands, elbows) or Disseminated ( back, chest, legs)
- Plaque with raised borders and NO SCALING
- More common in Females 2:1
- Treatments
  - Topical Steroids- Mid to High Potency ( Triamcinolone or Clobetasol)
  - IL steroid injections
  - MTX, Hydroxychloroquine, Dapsone-Disseminated

Am J Clin Dermatol. 2018 Jun;19(3):333-344.

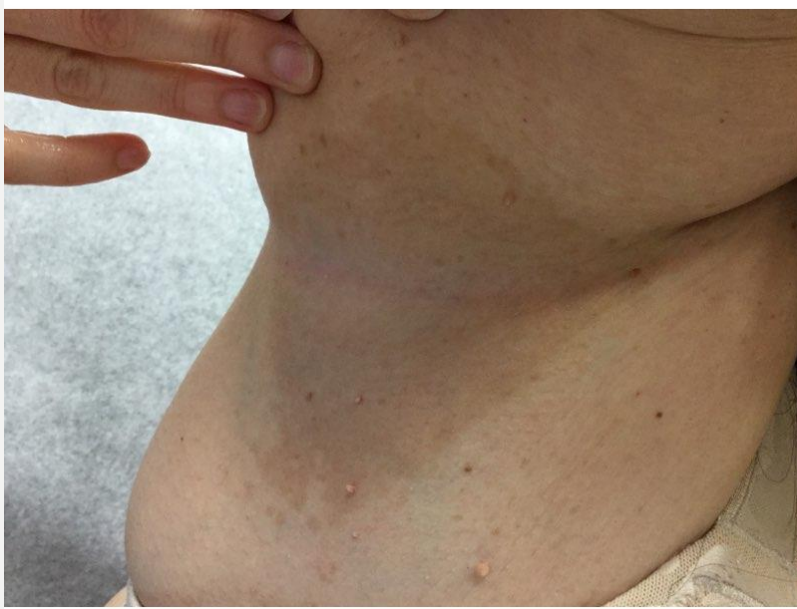**J Am Acad Dermatol.** 2016 Sep;75(3):467-479.

# DISSEMINATED GA

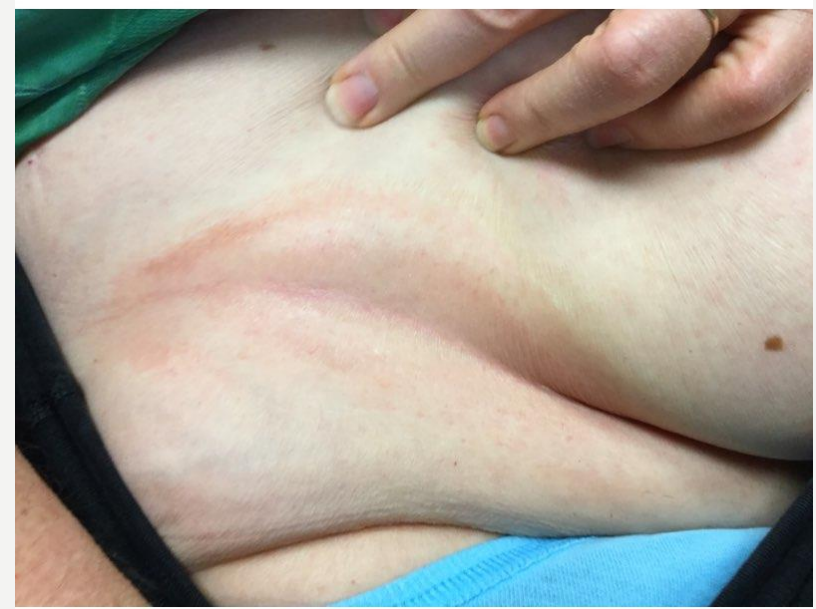

## 2. WHICH ONE IS TINEA ?

A



B



B

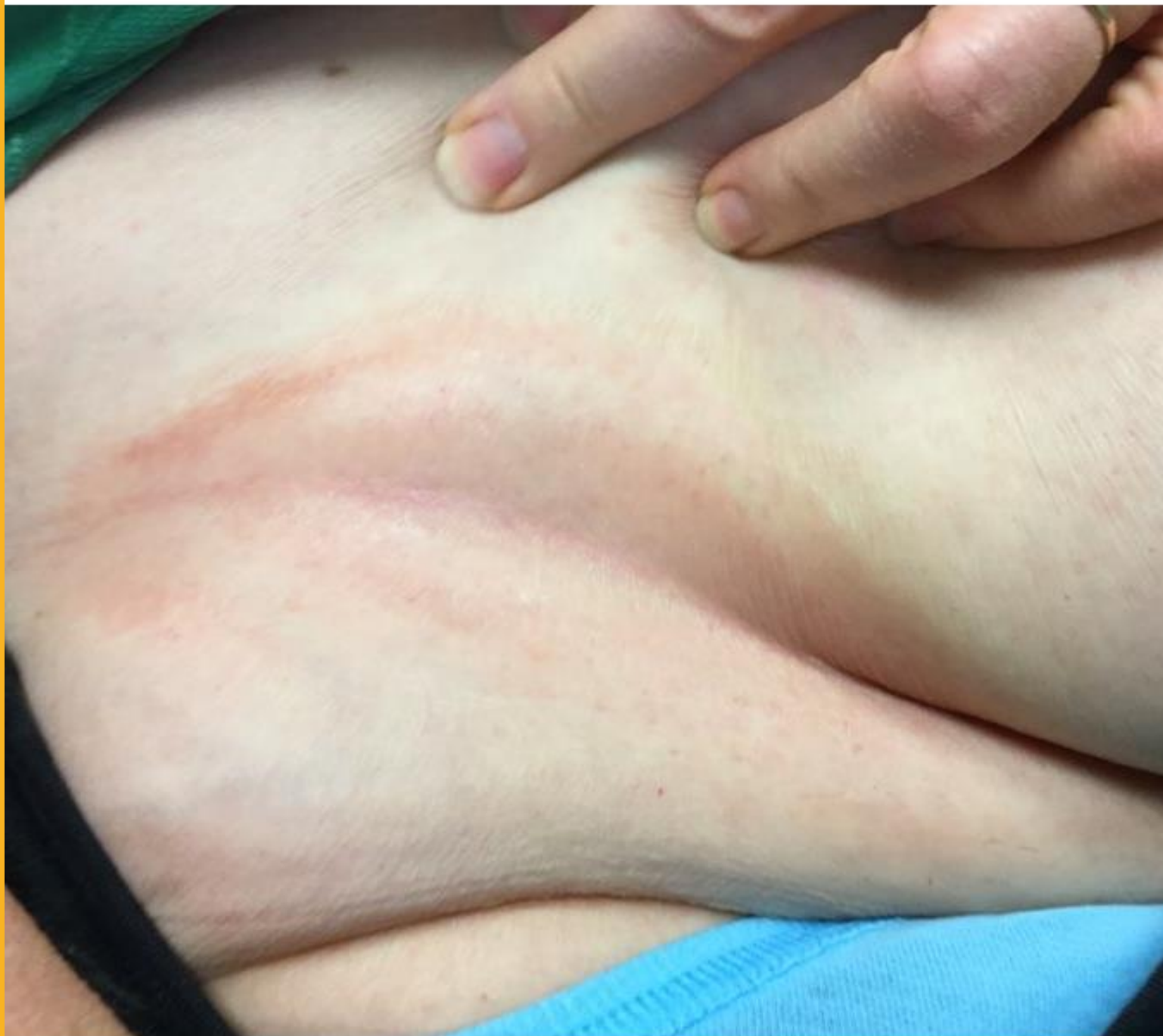## INTERTRIGO

40 y/o female with a rash for two weeks

Mildly itchy

History of Diabetes and mild obesity

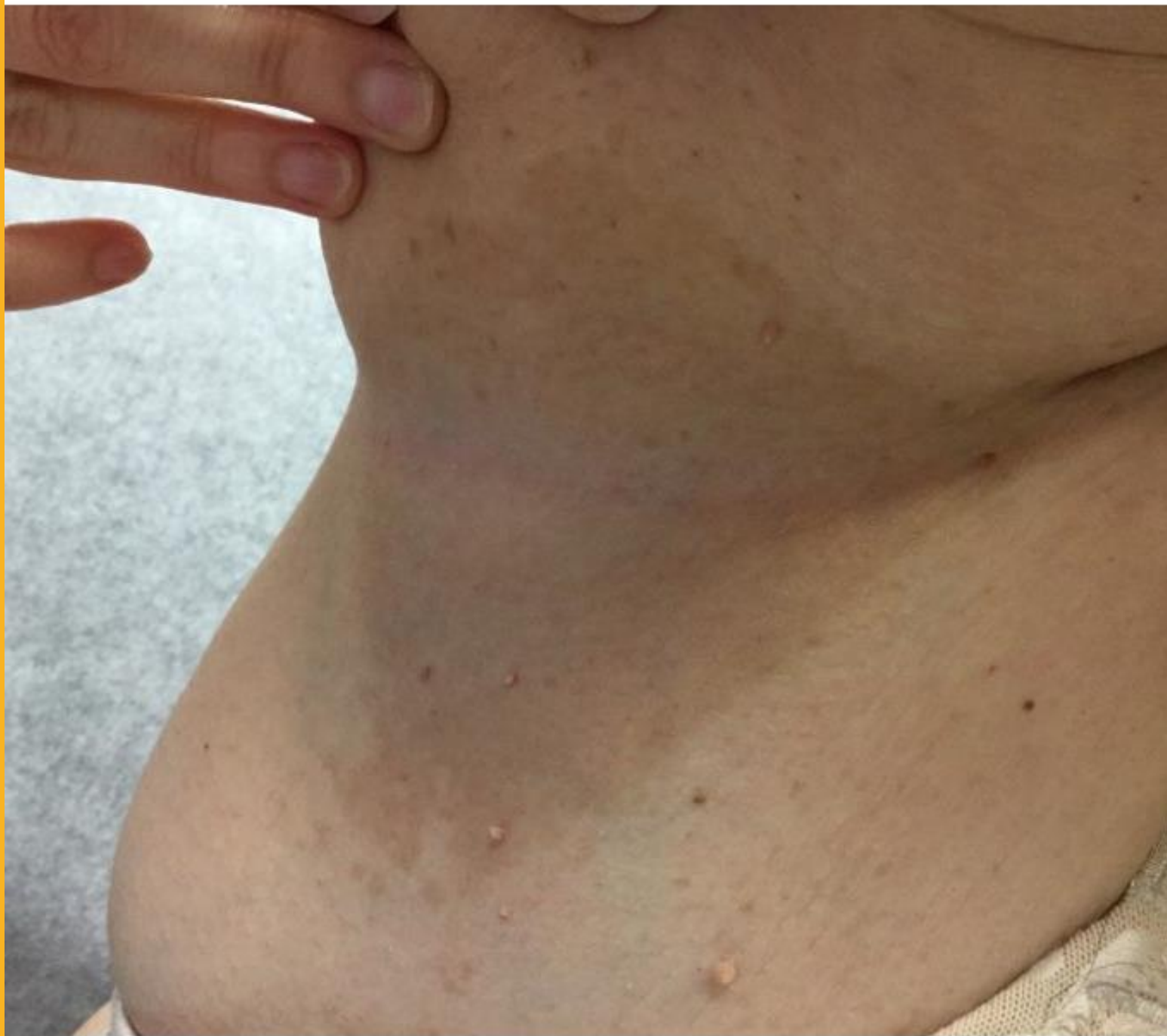Has been applying baby powder on area



# INTERTRIGO

- Larger skin folds causing friction, maceration
- *Candida albicans*: 80 - 90%
- axillary, gluteal cleft, infra-mammary, inguinal folds
- Tight fitting clothing, humid/hot weather, poor hygiene
- Diabetes & Obesity leading predisposing factors
- DX: clinical, culture, KOH, biopsy
- Tx: nystatin, ketoconazole, miconazole, clotrimazole daily for 2-4 weeks
  - Keep areas dry: Powders
  - Vinegar soaks
  - Oral Fluconazole 50-100mg daily or Itraconazole 200mg daily for 2-6 weeks: Recalcitrant



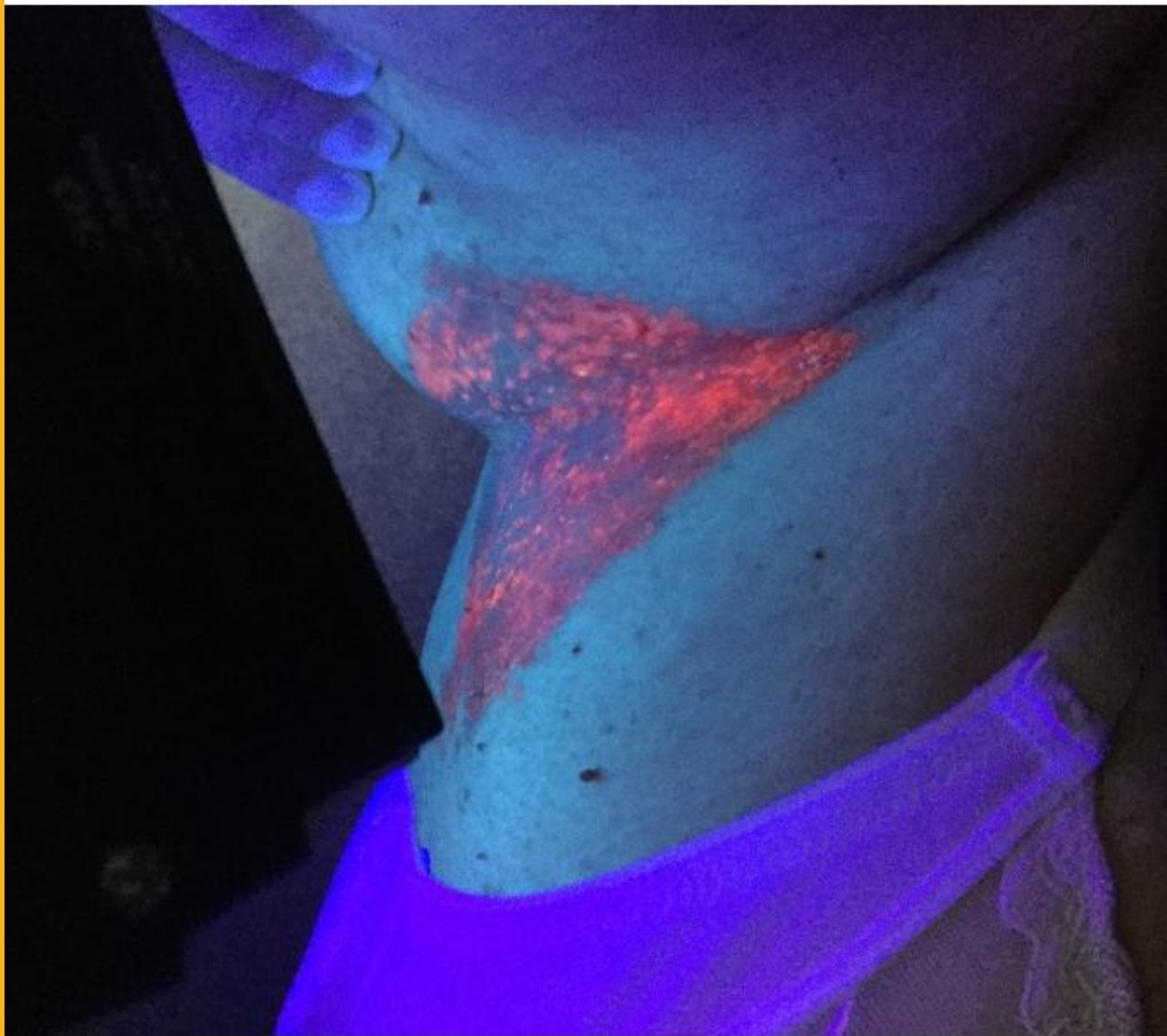

## ERYTHRASMA

54 y/o female with rash for 2-3 years

Treated with topical steroids and antifungals by many providers

Rash is not itchy



**WOODS LAMP:**

**CORAL-RED  
FLUORESCENCE**

Diagnostic for Erythrasma

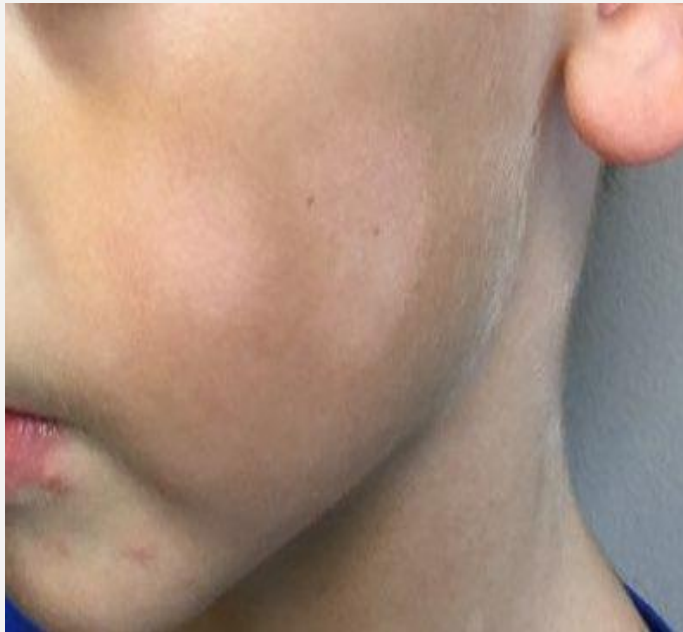# ERYTHRASMA

- Sharply delineated brown patches with scant scale
- Superficial localized infection
  - *Corynebacterium Minutissimum*
- Intertriginous or Interdigital
- Tx: Topical Clindamycin or Erythromycin

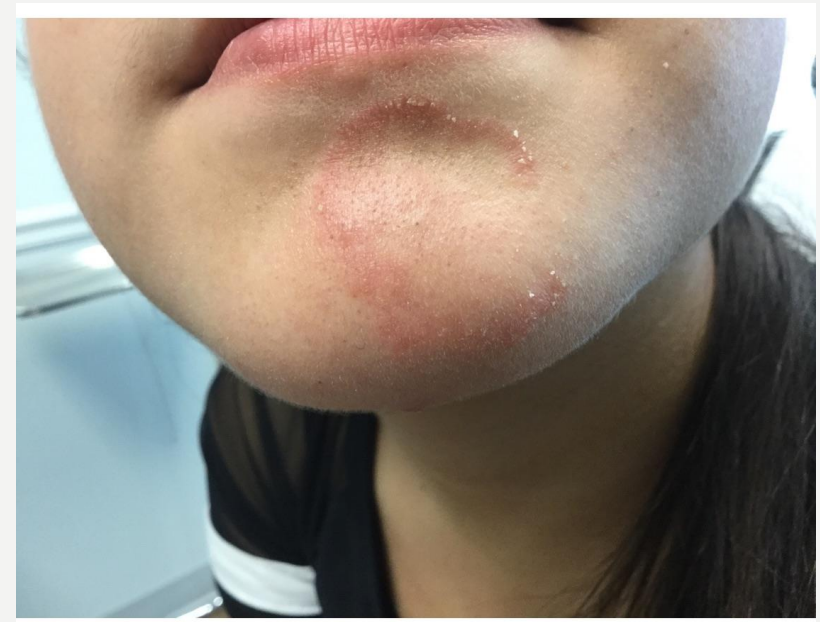

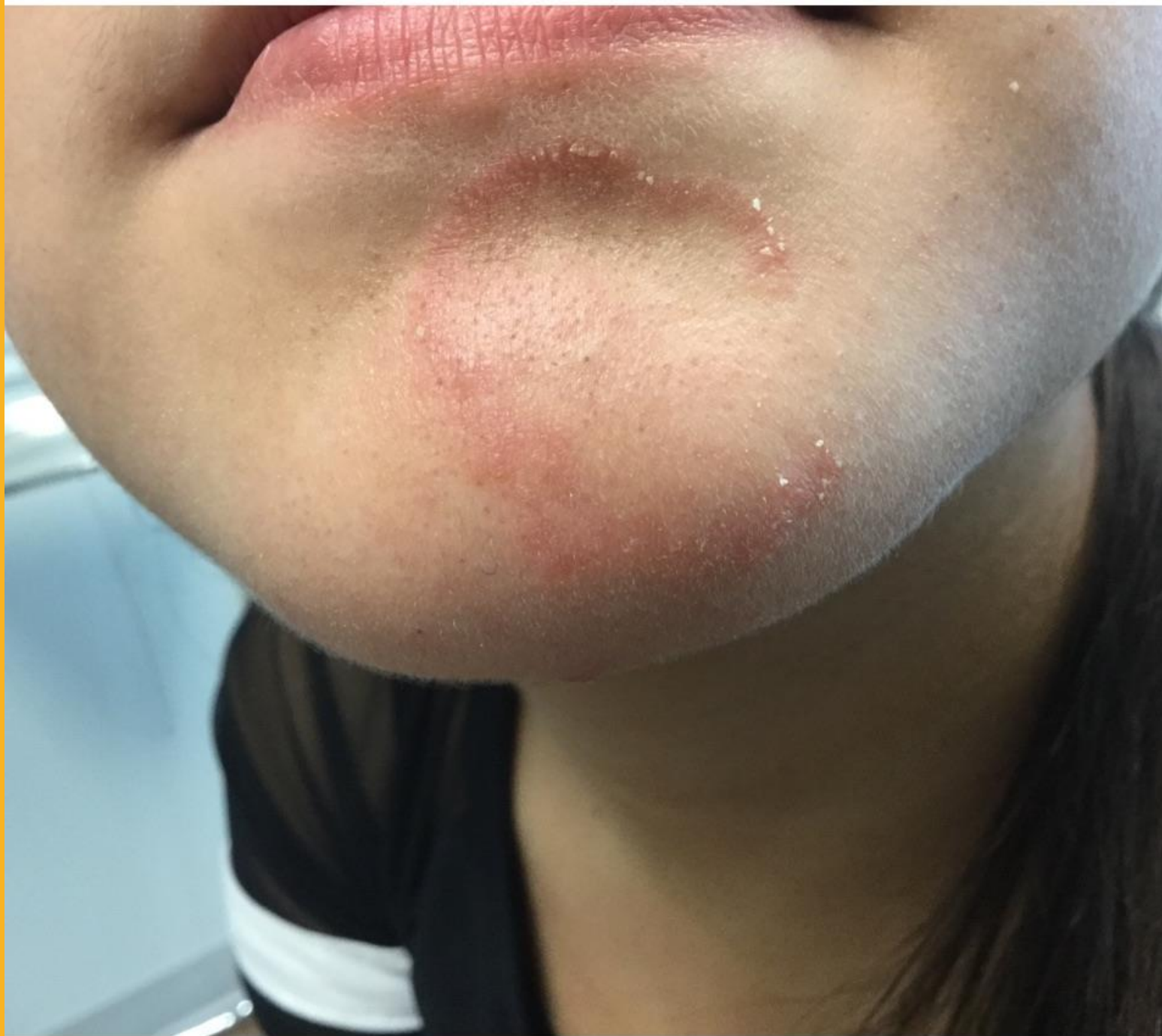### 3. WHICH ONE IS TINEA ?

A



B





B

## **TINEA FACIEI**

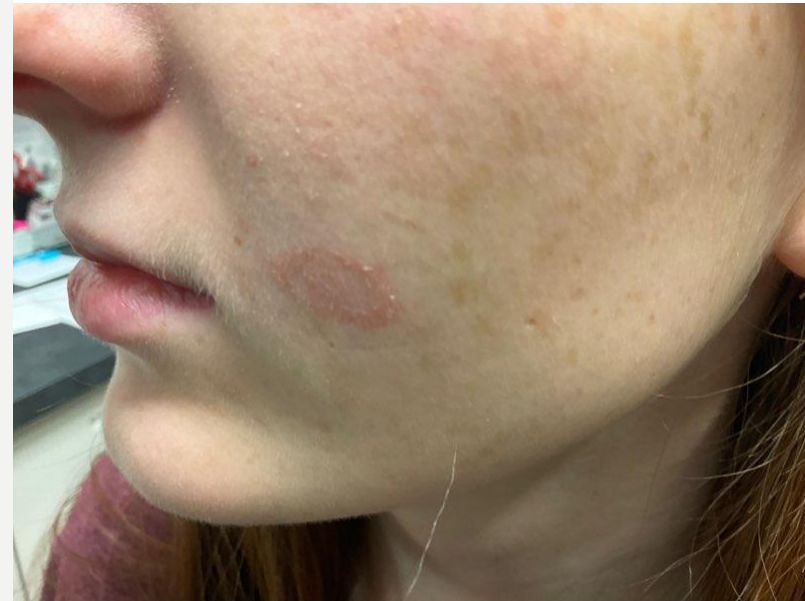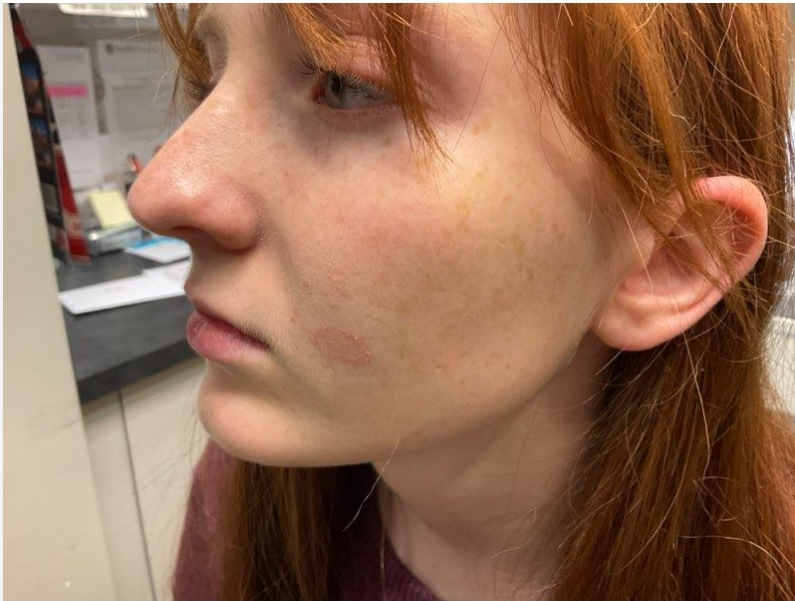10 year old with rash for 8 weeks

Just got a new kitten

Itchy-no improvement with  
Benadryl

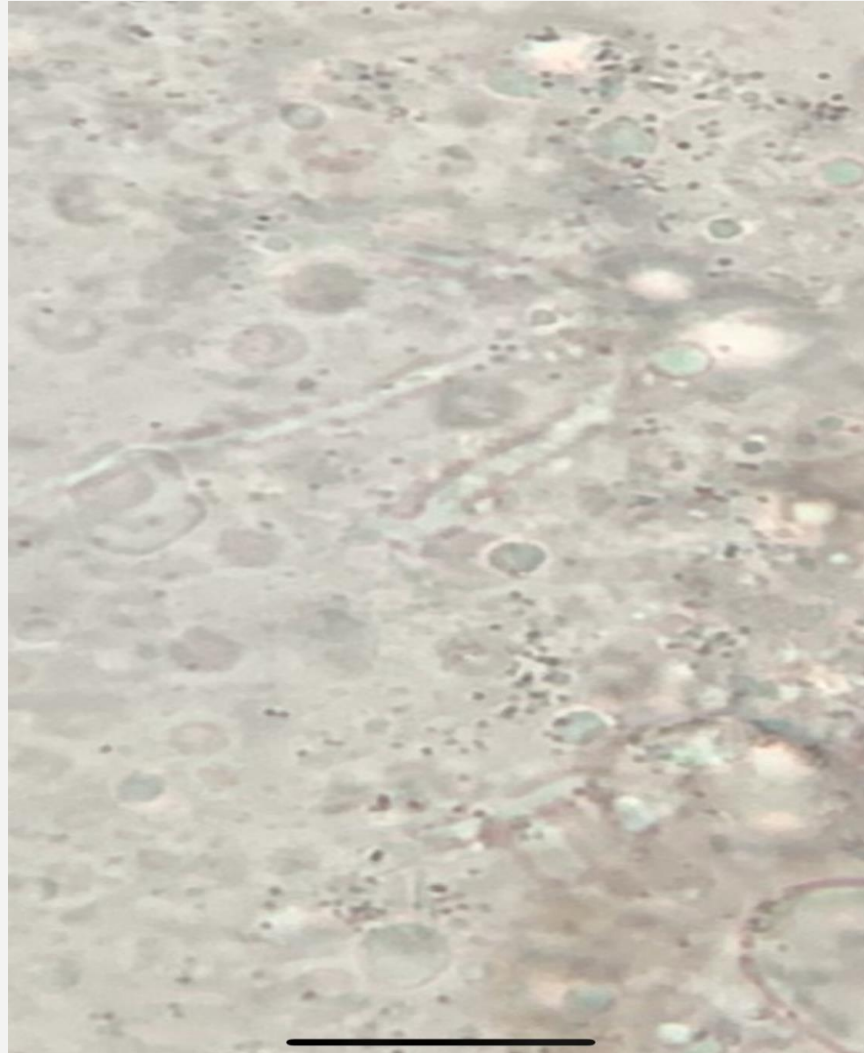
Tx: topical ketoconazole bid for 2-  
3 weeks

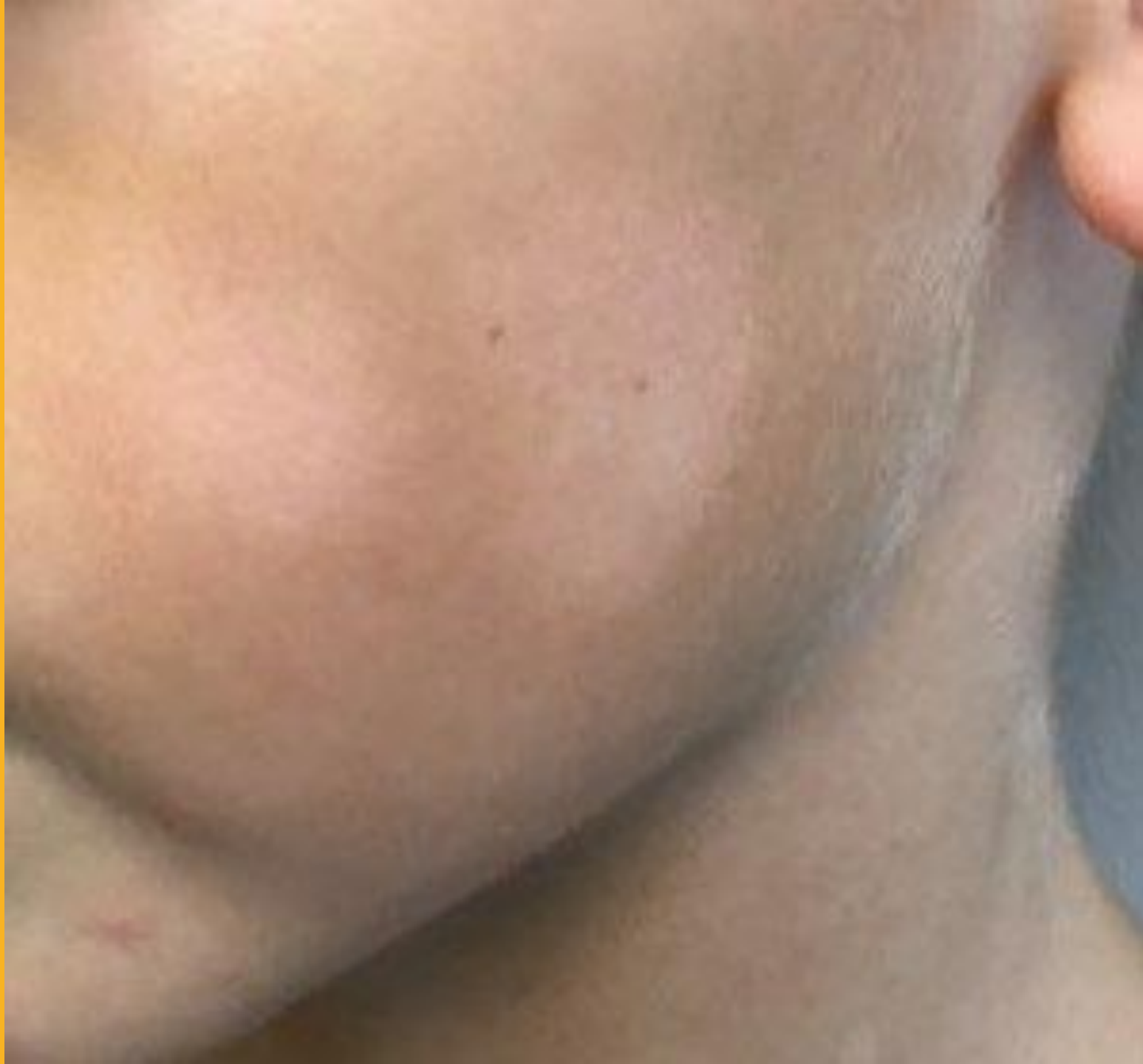# TINEA FACIEI











## **PITYRIASIS ALBA**

7 y/o male treated for tinea by pediatrician for 4 weeks

Given topical ketoconazole and rash is spreading

Mom worried this is Ring Worm and other family members will get this rash



# PITYRIASIS ALBA

- Hypopigmented macules
- Children and adolescents
- Common in Skin of color pts
- Can be associated with Atopic Dermatitis
- Upper body areas ( face most common)
- Tx: Moisturizers and/or topical steroids

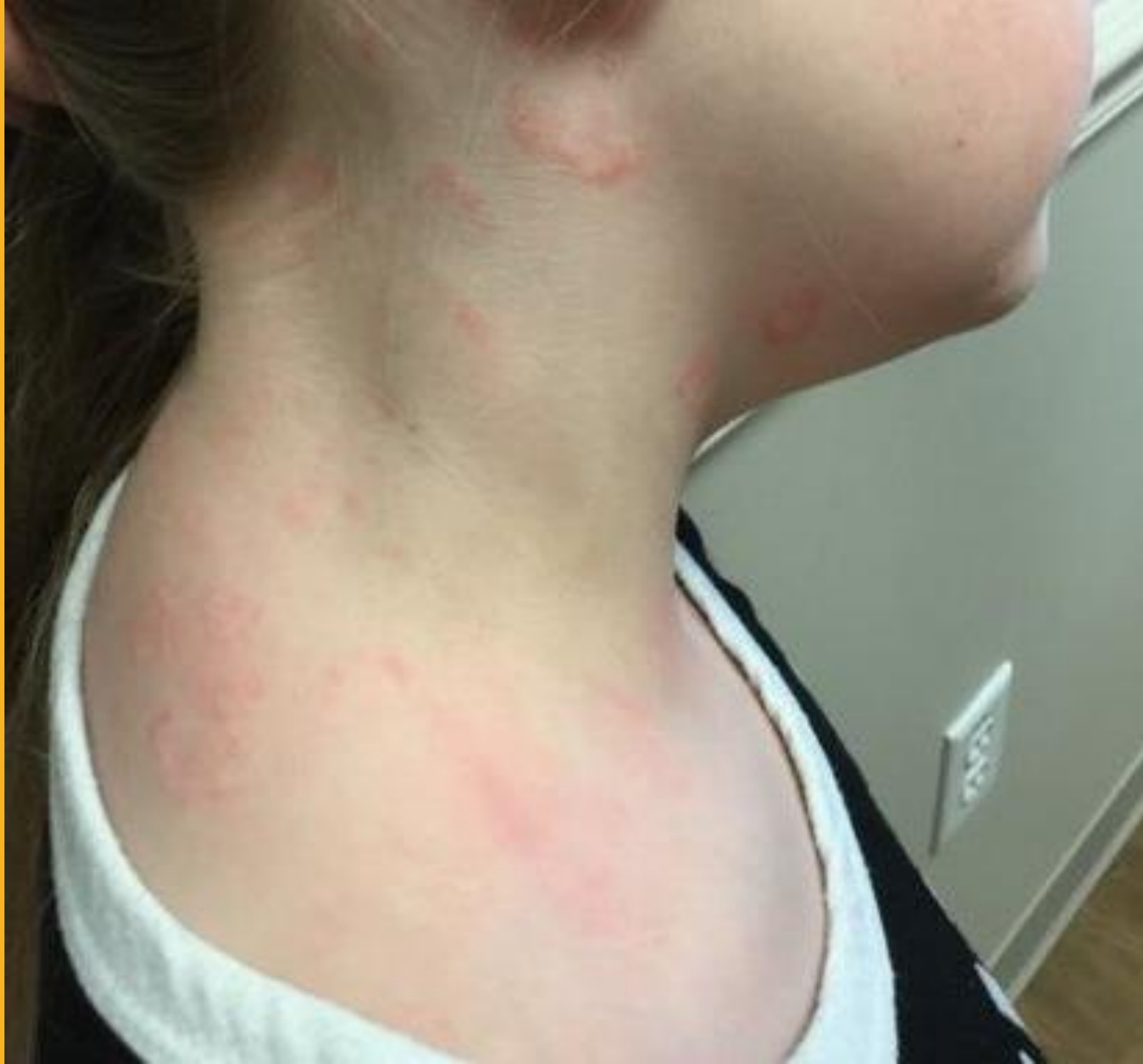## 4. WHICH IS TINEA ?

**A**



**B**





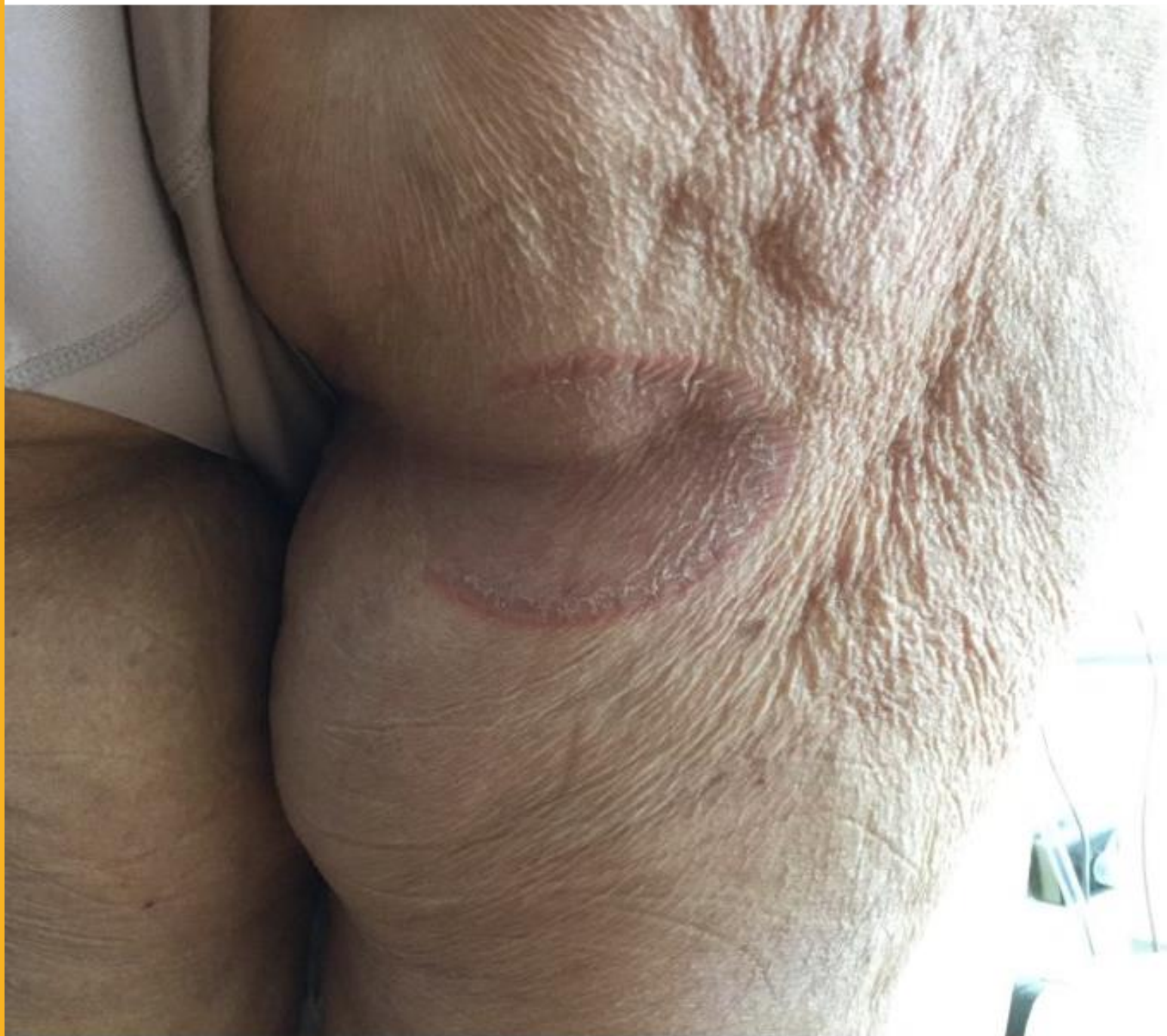B

## TINEA CORPORIS

10/yo female rash for 12 weeks

Treated by urgent care with  
hydrocortisone

Rash is very itchy



## ERYTHEMA ANNULARE CENTRIFUGUM

65 y/o female with rash for 8 weeks

Not itchy

Treated with Ketoconazole cream for 4-6 weeks , no improvement

In Office for routine skin check

# ERYTHEMA ANNULARE CENTRIFUGUM

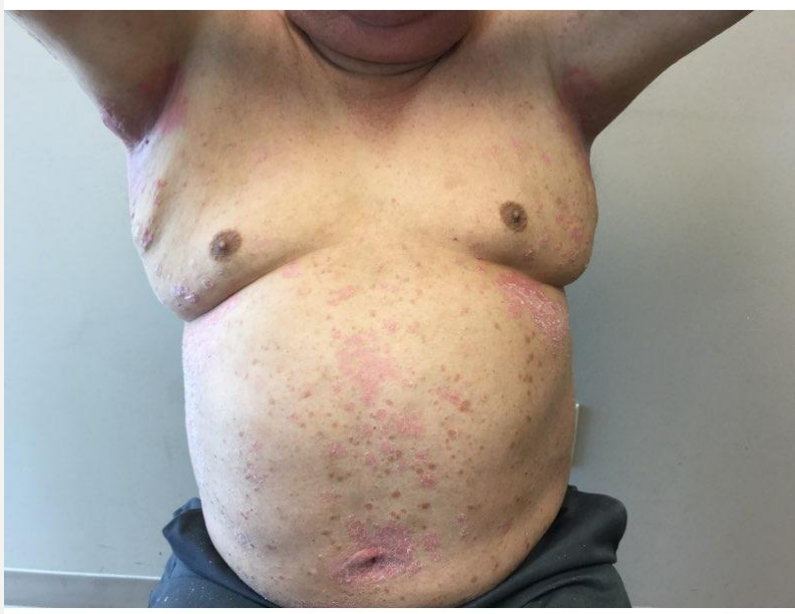## “EAC”

- Gyrate Erythema
- Annulare plaques: migrate centrifugally
- “trailing scale”
- Idiopathic
  - Sometimes medications
  - Malignancies
  - infections
- TX: topical steroids

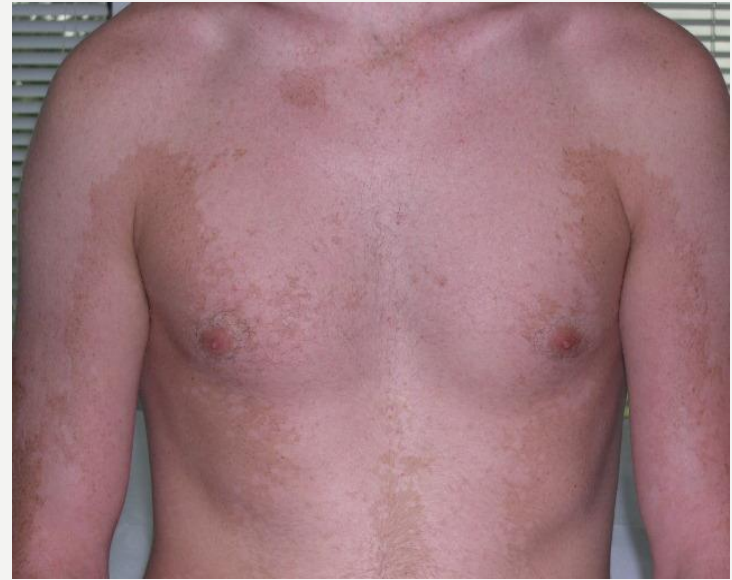

# 5. WHICH IS TINEA?

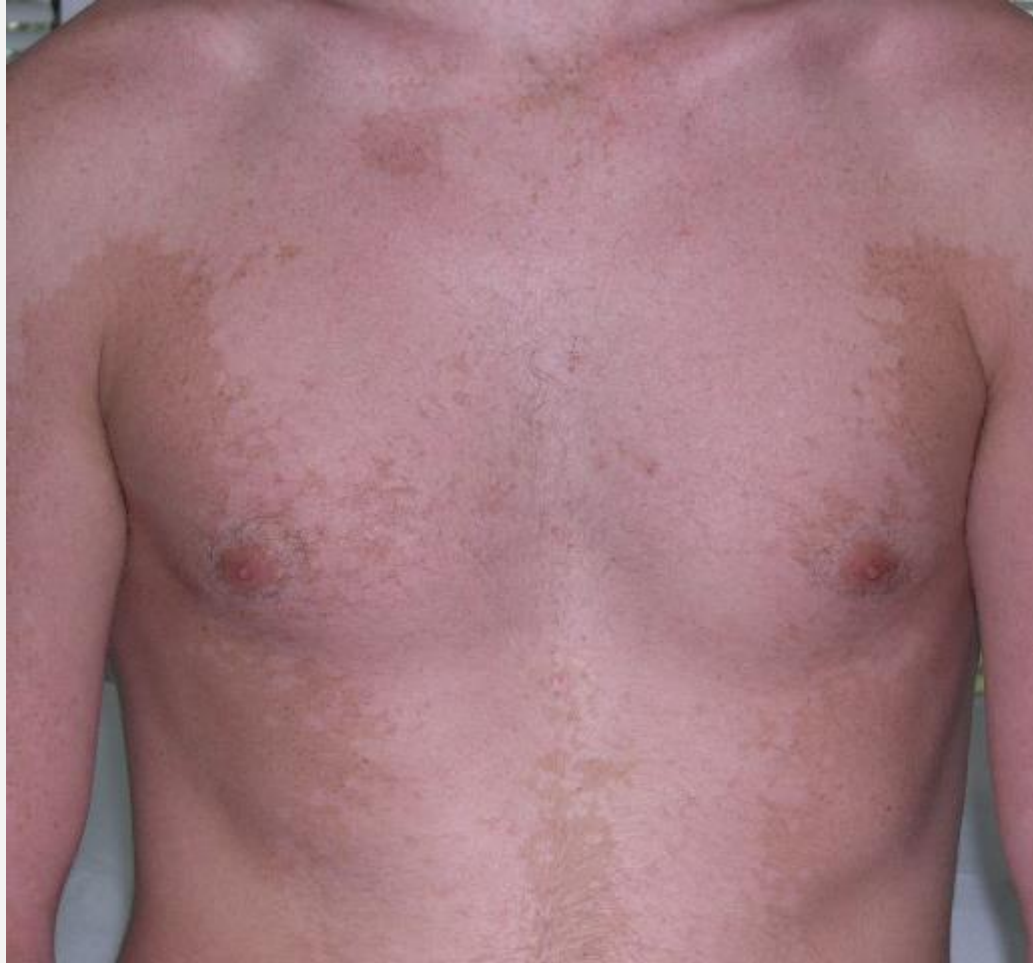**A**



**B**







B

## TINEA VERSICOLOR

18 y/o male presents with rash for 4 weeks

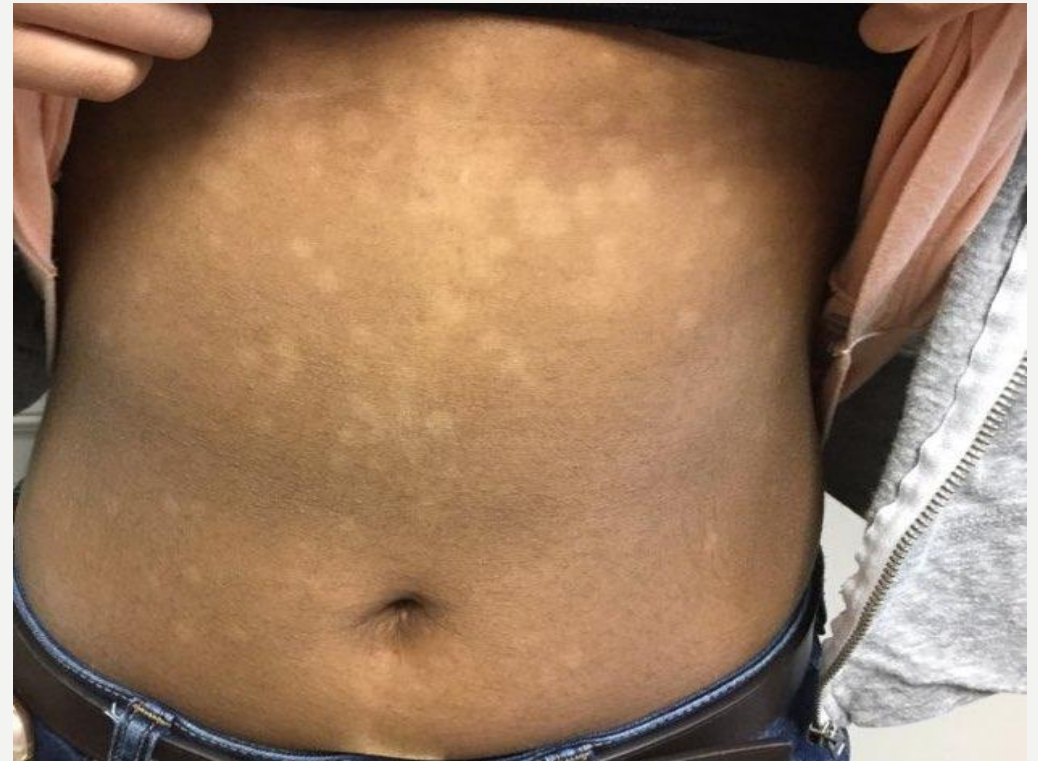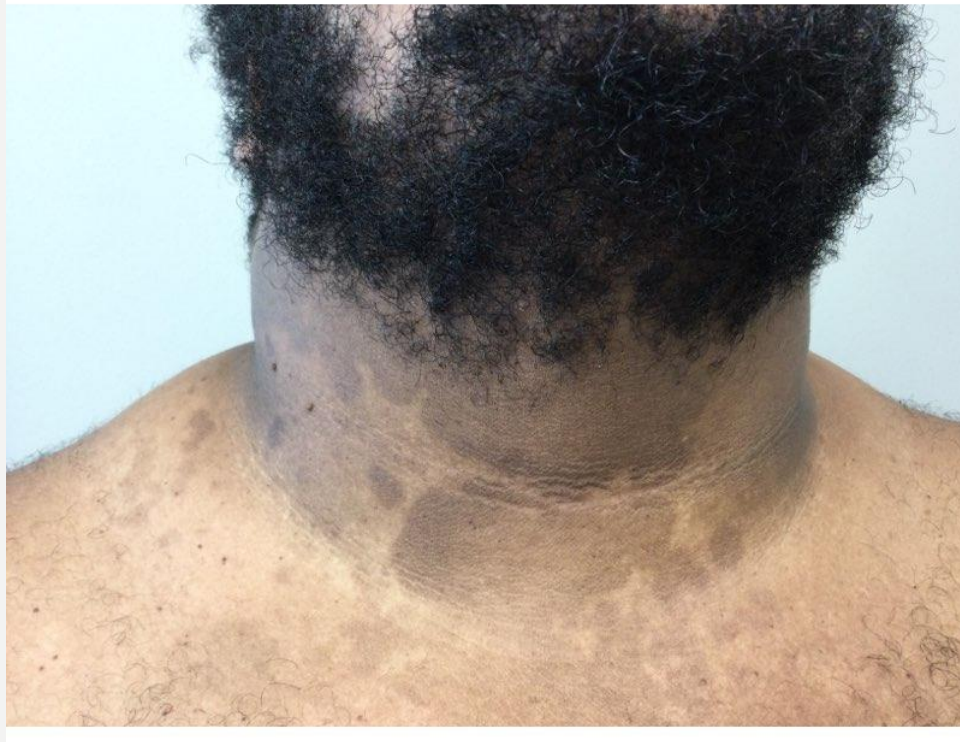Started after he went to the beach

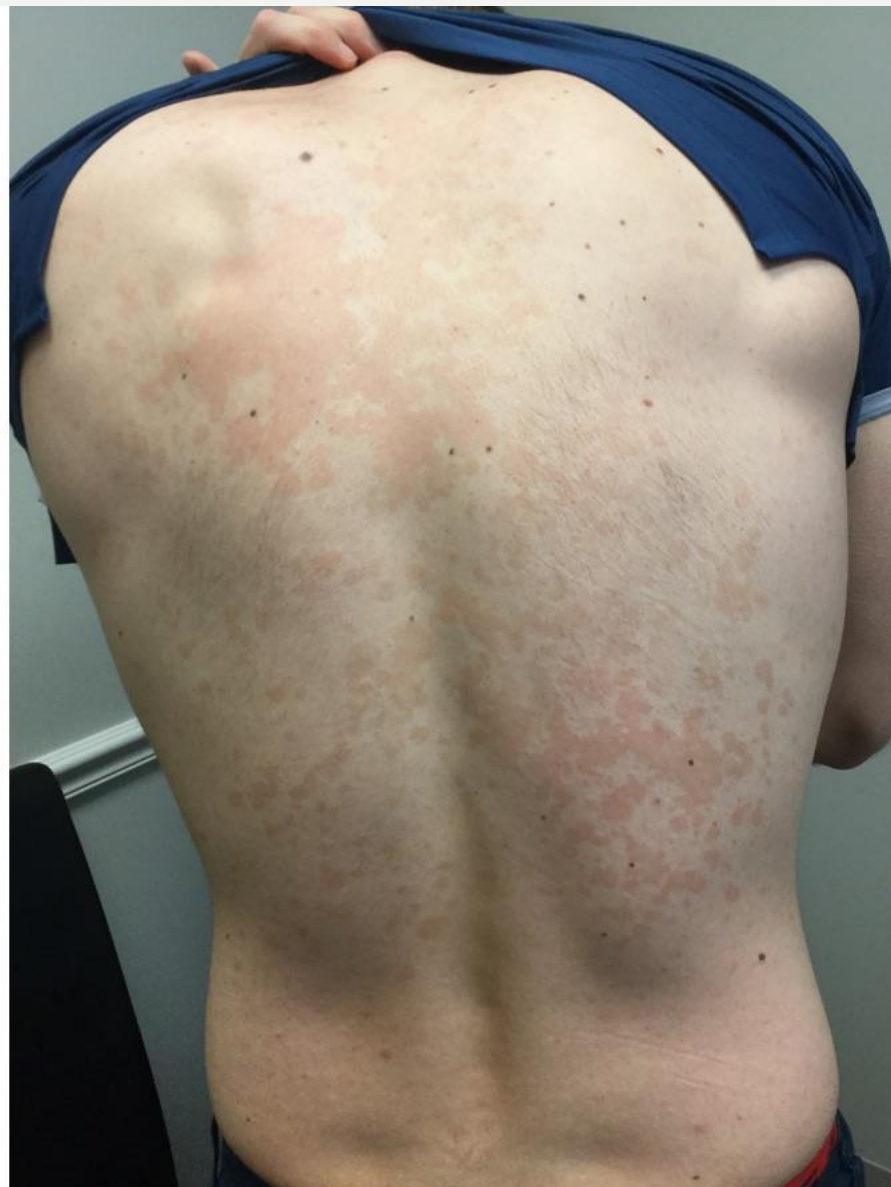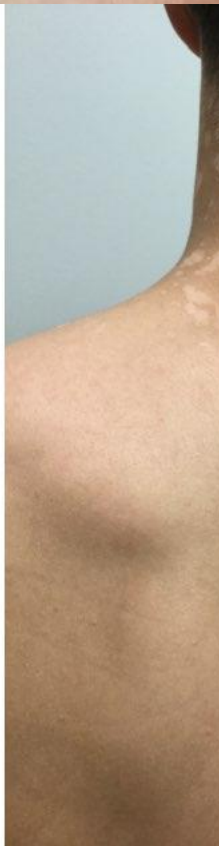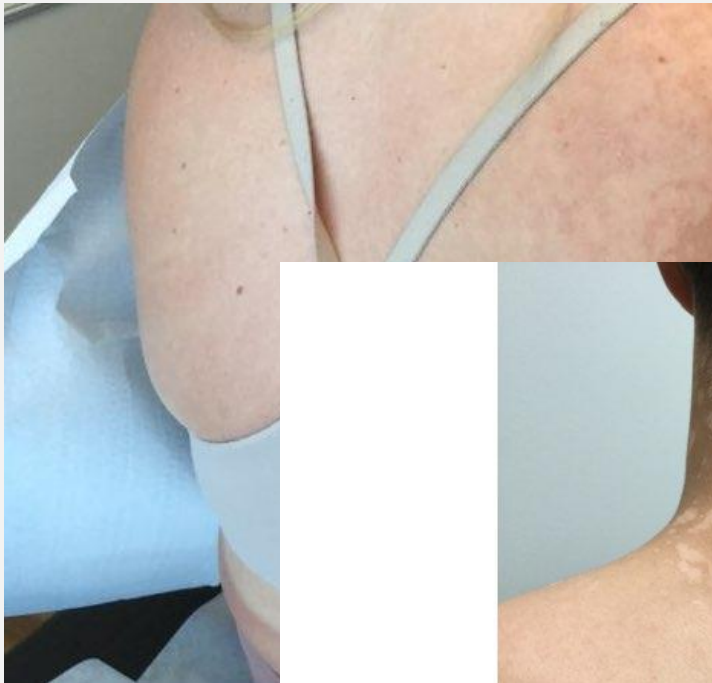No treatment

KOH+ for budding yeast and branching hyphae

Treated with Itraconazole and Ketoconazole Shampoo

# TINEA VERSICOLOR SOC





# TINEA VERSICOLOR (PITYRIASIS VERSICOLOR)

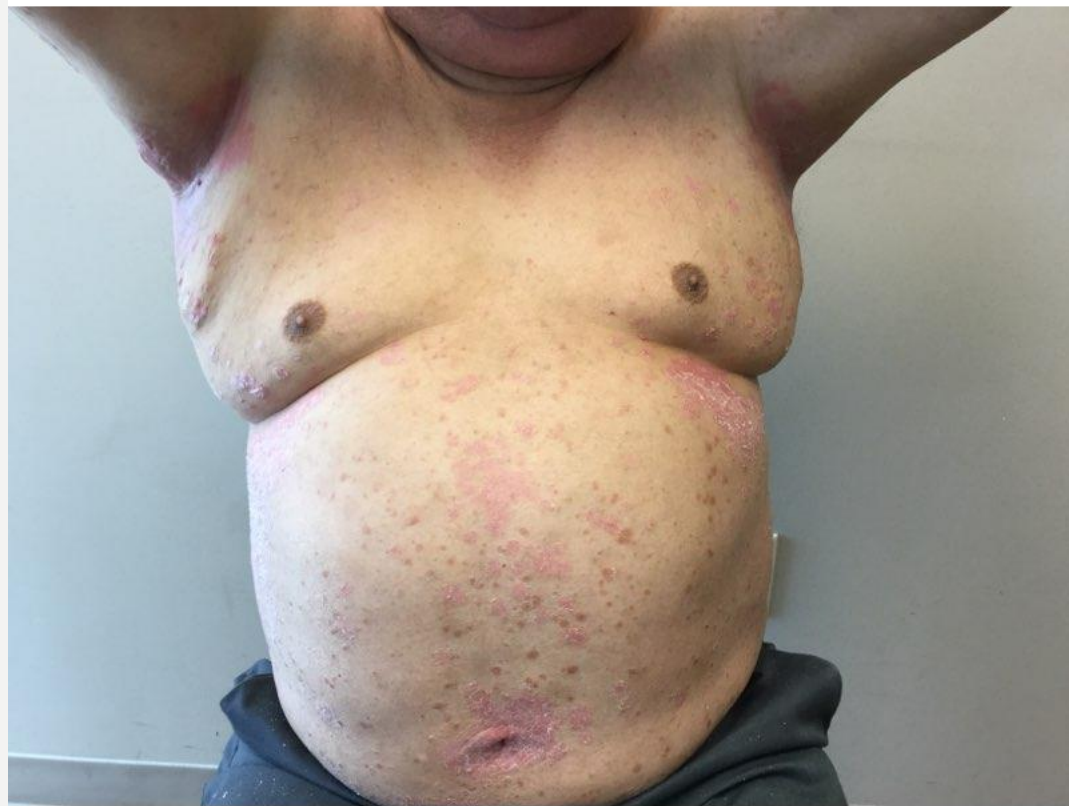- Presents as hyper or hypopigmented scaling patches on chest , back, neck
- Slightly more common in men and young adults
- Common in warm humid areas
- Caused by Malassezia ( yeast)
- KOH- budding yeasts and branching Hyphae “spaghetti and meatballs”
- Wood’s Lamp-yellow green fluorescence
- Treatment: Azole Cream or Shampoo ( Ketoconazole)
  - Itraconazole 200 mg daily for 5 days or Fluconazole 150 mg orally and repeat in one week
  - NO ORAL KETOCONAZOLE
  - Terbinafine orally not effective



# BUDDING YEAST AND BRANCHING HYPHAE



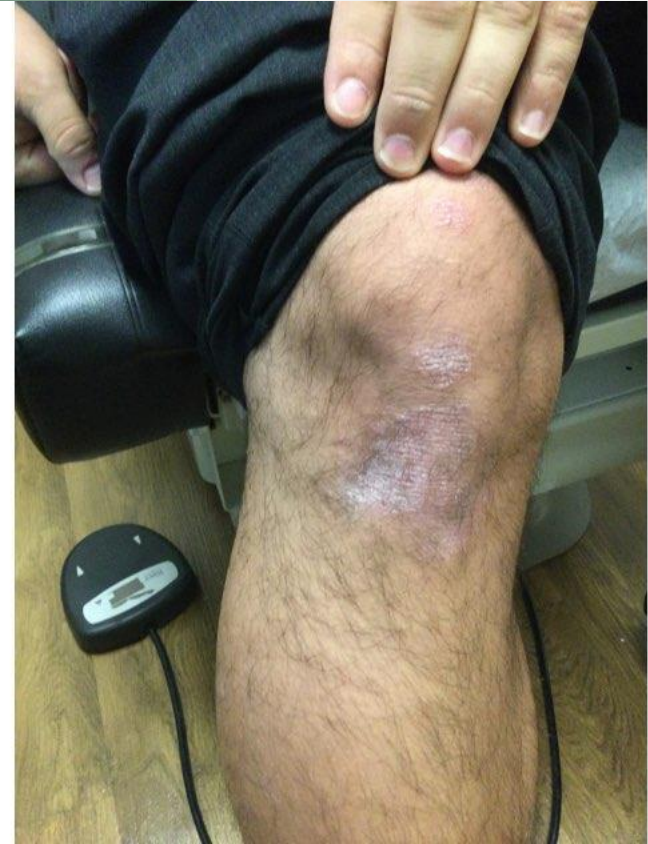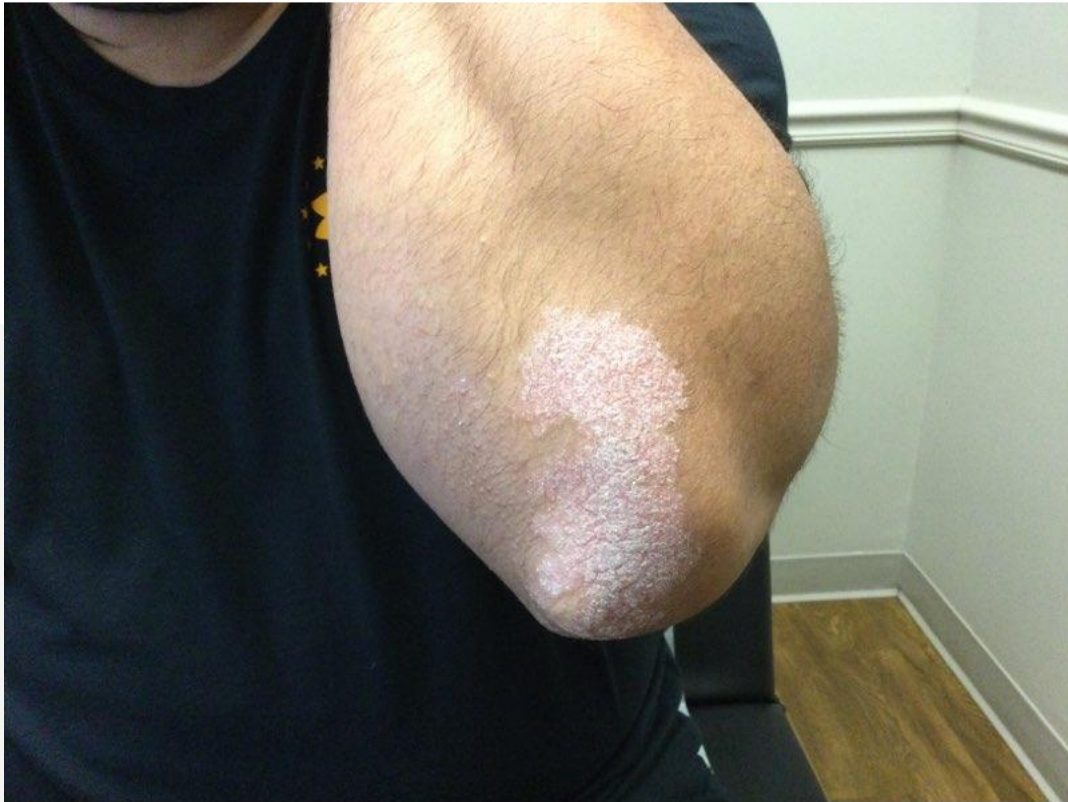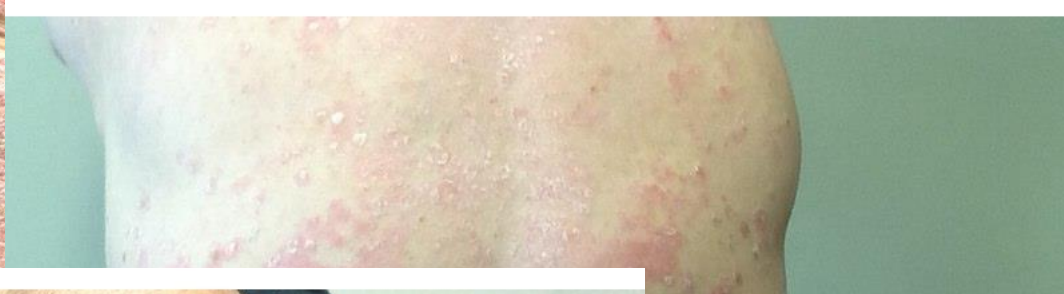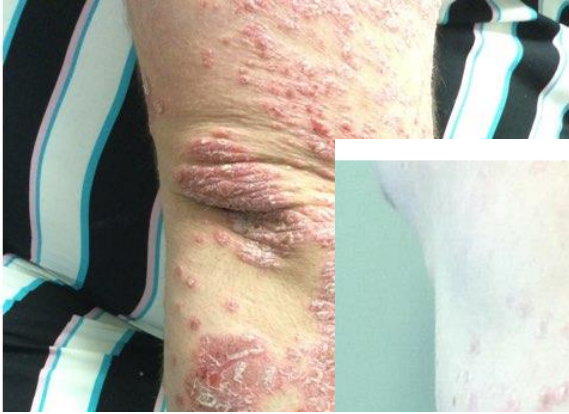




## PSORIASIS

65y/o male with rash for years

Treated with topical triamcinolone



# PSORIASIS

- Plaque, Guttate, pustular
- Immune Mediated Dz- speeds up skin cell growth
- Scaly plaques on elbows, knees , scalp, gluteal cleft
- Treatments
  - Topical steroids, Topical Tapinarof, and Topical Roflumilast
  - NBUVB
  - Oral Methotrexate, Oral cyclosporine, Oral Apremilast, Oral Deucravacitinib (JAK)
  - Biologics: TNF, IL-17, IL-12/23, IL-23



## 6. WHICH IS TINEA?

**A**



**B**

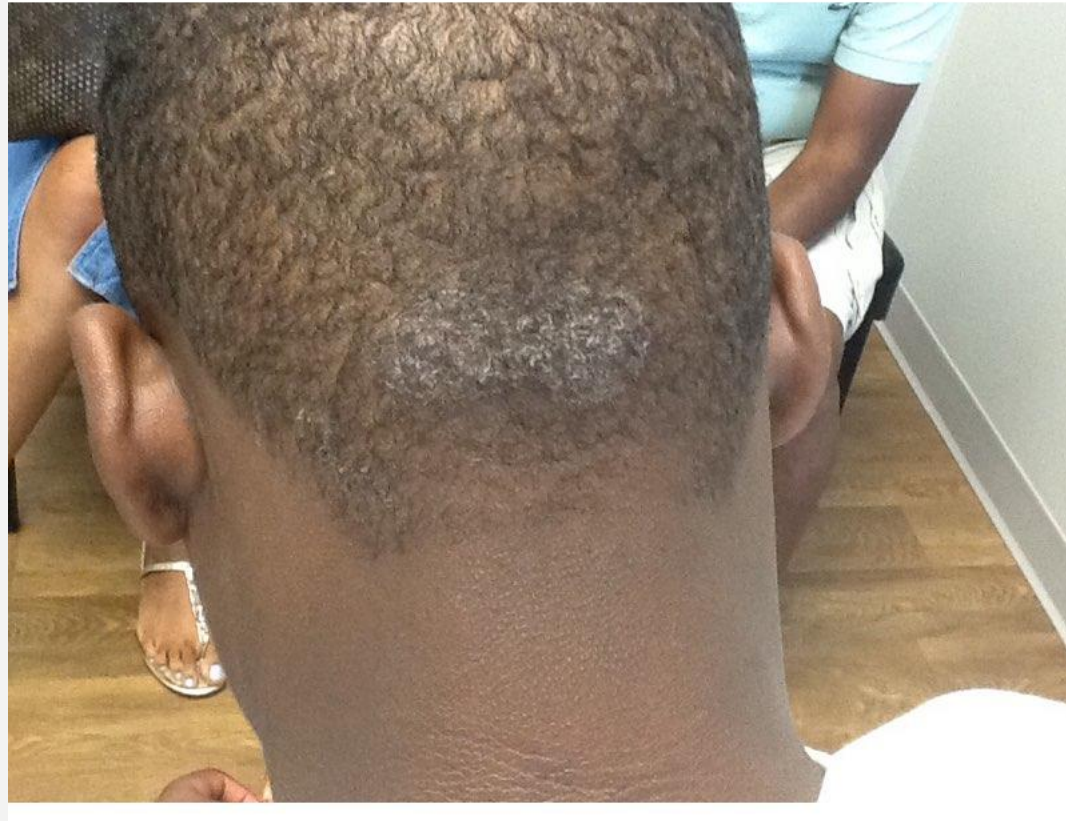

B

## TINEA CAPITIS

13 y/o male with itchy patch on scalp for 3 months

Treated by PCP with Ketoconazole Shampoo and topical Ketoconazole, for 4 weeks





# TINEA CAPITIS

- Scaly patches, hair breakage, hair loss, crusting, pustules (Kerion)
- *Trichophyton tonsurans* ( in US)
- More common in children
- Cervical and auricular lymphadenopathy
- Can spread with close contact- sharing beds, combs, brushes
- Hair sample for culture: Brush, tooth brush, comb, hair plucking
- \*\*Woods Lamp NOT Effective: *T. tonsurans* does not fluoresce

J Eur Acad Dermatol Venereol. 2018 Dec;32(12):2264-2274.

Adv Skin Wound Care. 2019 Aug;32(8):350-357.

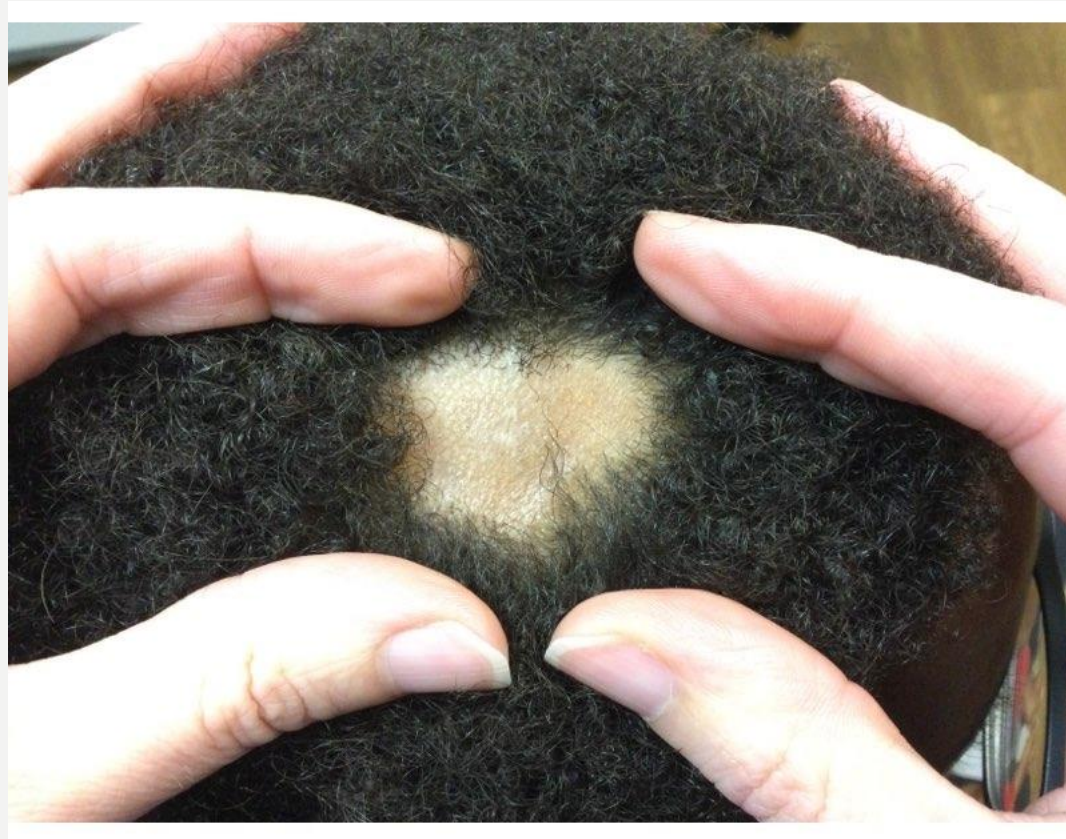# TINEA CAPITIS TX

- **\*\*oral treatment needed: topical tx does not penetrate the hair follicle**
- Griseofulvin 20-25mg/kg/day for 6-12 weeks until clinically clear
  - Co administer with fatty food (ice cream)
  - Most cost effective
- Terbinafine 5mg/kg for 4-6 wks
  - Check baseline transaminase

2274.

J Eur Acad Dermatol Venereol. 2018 Dec;32(12):2264-

Adv Skin Wound Care. 2019 Aug;32(8):350-357.



## ALOPECIA AREATA

10 y/o male with patch of hair loss  
for two months

No itching or scaling present

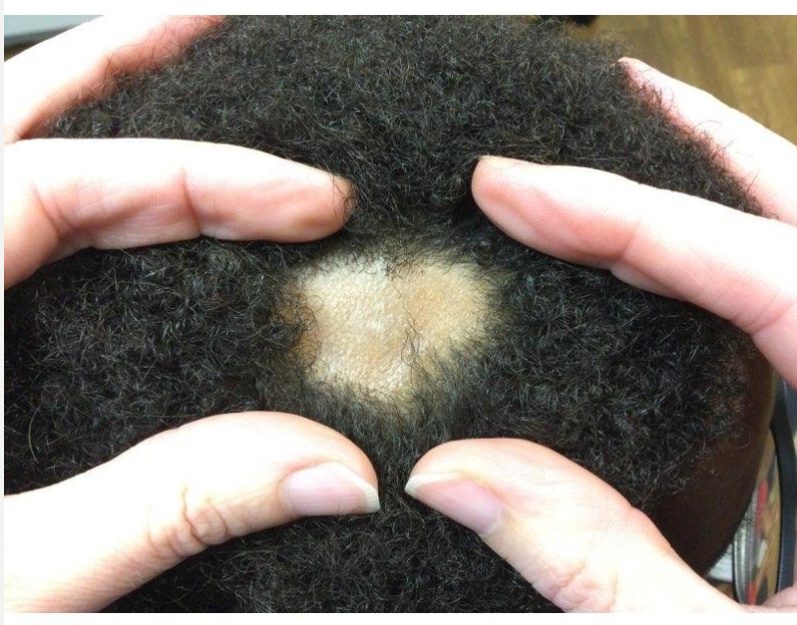Tx with an “oral” medication and  
solution for one month

No other household contacts with  
hair loss

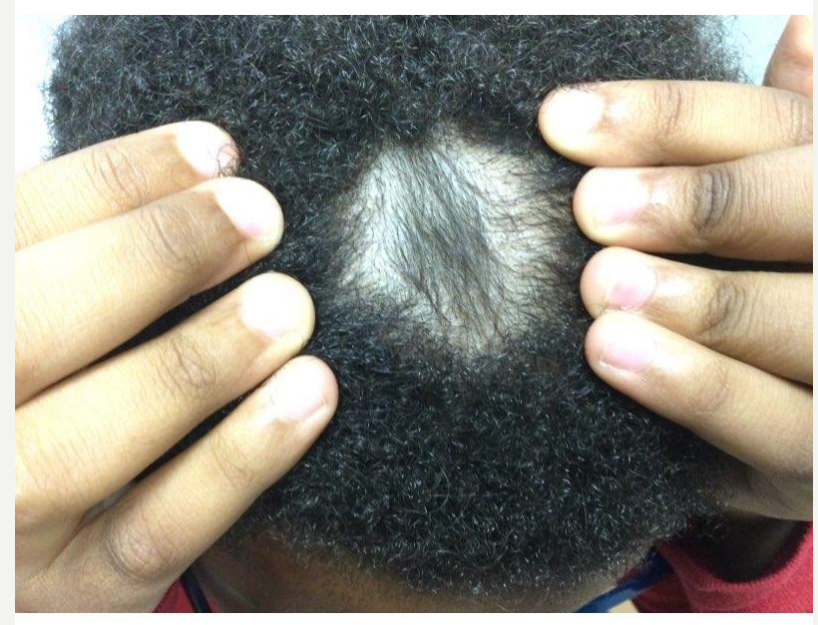# ALOPECIA AREATA

- Non scarring hair loss
- Smooth oval patches of hair loss- no inflammation or scaling
- Scalp, bearded areas, eyebrows
- Can be associated with other autoimmune disorders
- 50% begins in childhood
- Totalis-Entire scalp    Universalis- Entire Body
- TX: topical and IL steroids, minoxidil, MTX, squaric acid, Dupilumab, Baricitinib, Ritlecitnib
  - 30% -50% recover spontaneously

**BEFORE IL KENALOG**



**AFTER IL KENALOG**



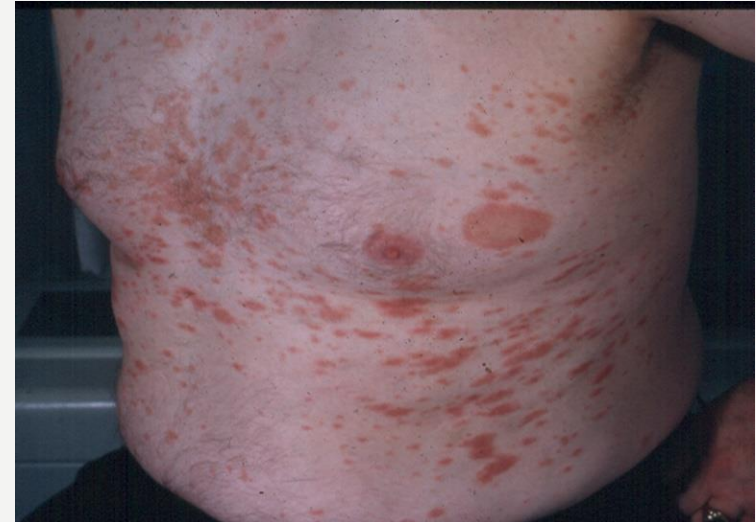

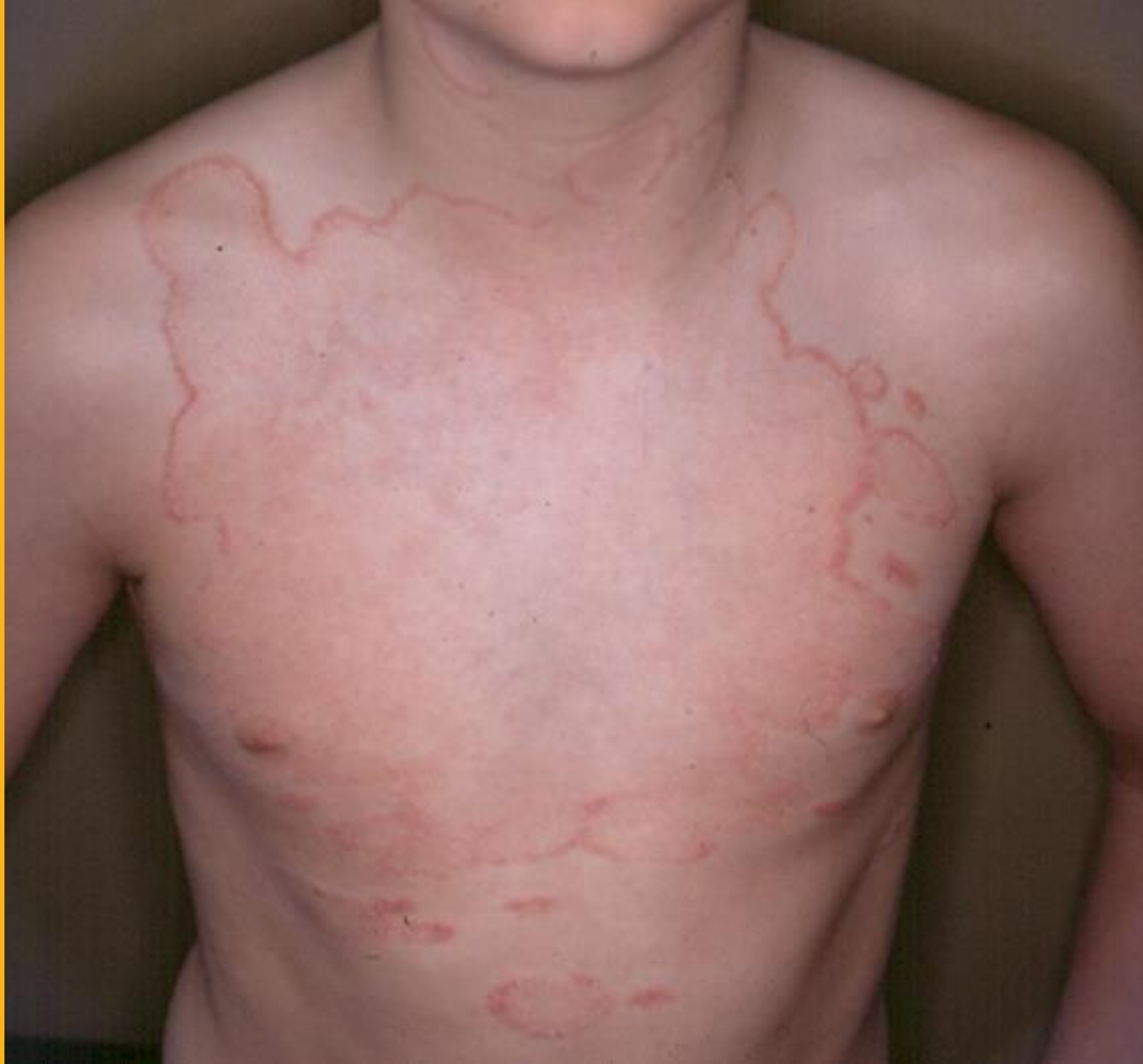# 7. WHICH IS TINEA?

**A**



**B**





A

## TINEA CORPORIS

Pt had rash for 6months

Wrestler


Applying OTC hydrocortisone

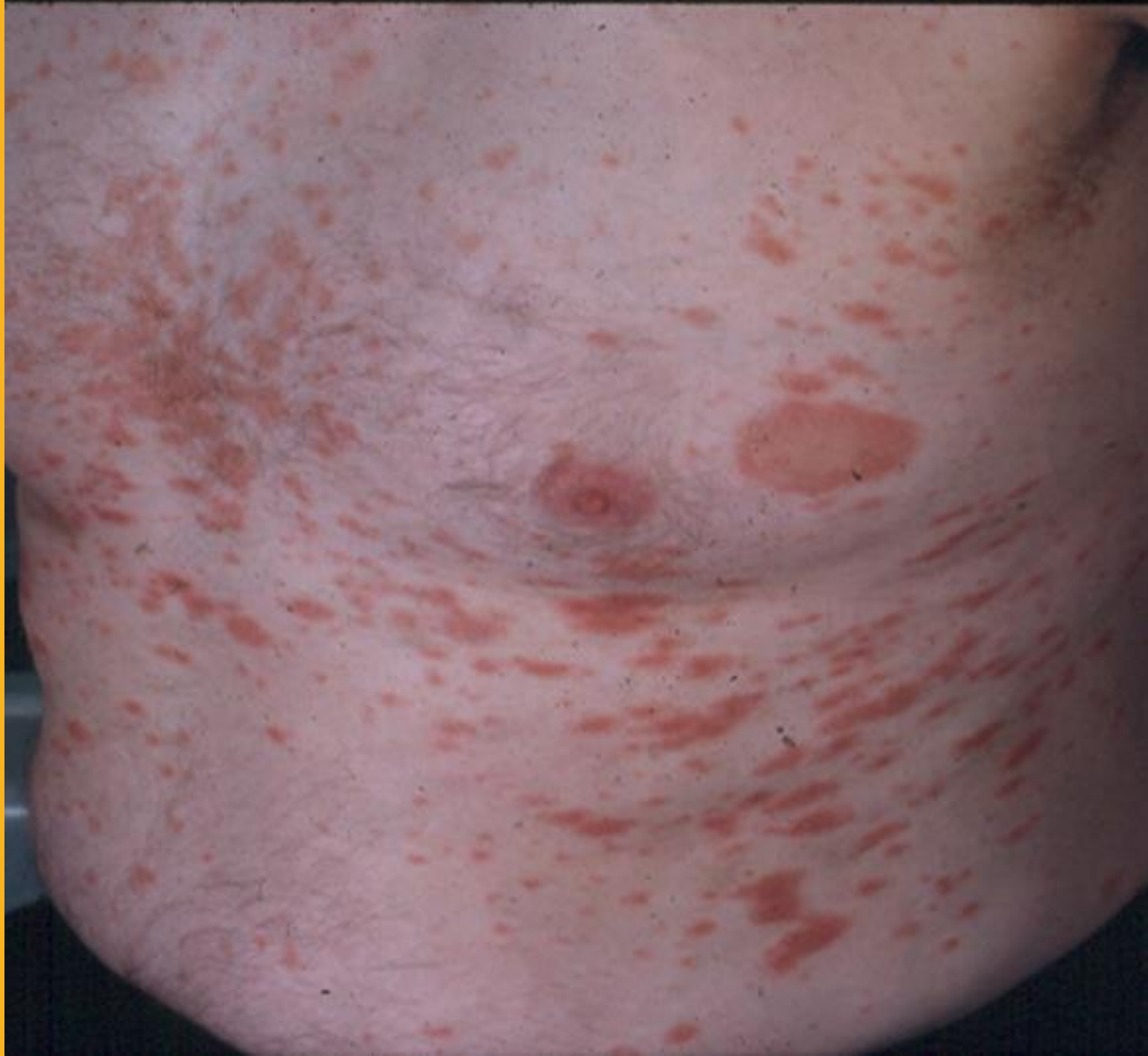Itchy

POSITIVE KOH: BRANCHING  
HYPHAE

TX: ketoconazole cream or oral  
terbinafine/itraconazole

# **POSITIVE KOH BRANCHING HYPHAE**





## PITYRIASIS ROSEA

20y/o with rash for two weeks

Started with one area on chest  
then spread

Not itchy

No treatment to date

# PITYRIASIS ROSEA

- May be caused by a Virus
- Salmon colored scaly macular and papular rash
- Common in teenagers and young adults
- Not itchy
- Herald patch then spreads within one week to two weeks
  - “Christmas Tree” distribution
- Last 6-12 weeks
- Tx: palliative, usually none needed
  - Topical steroids, NBUVB

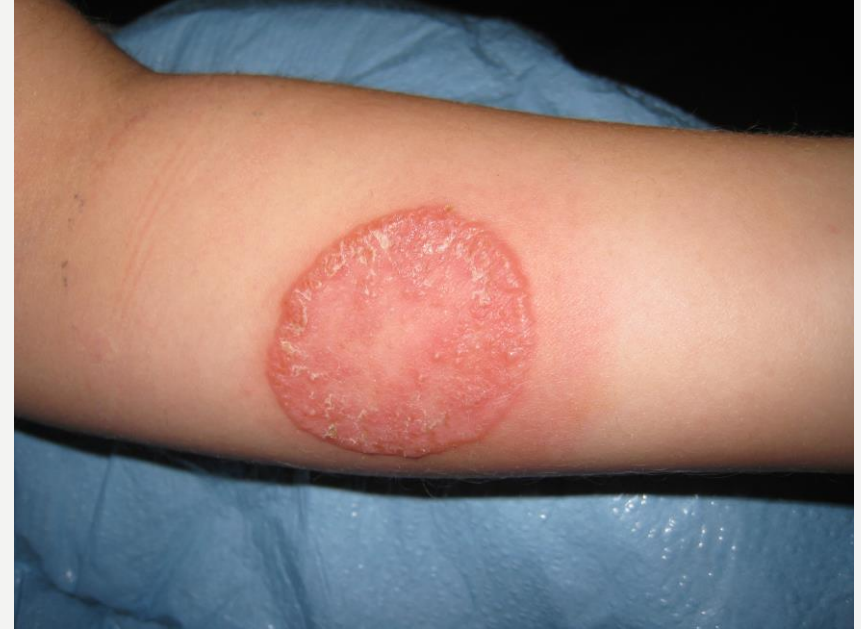

## 8. WHICH IS TINEA?

A



B



B

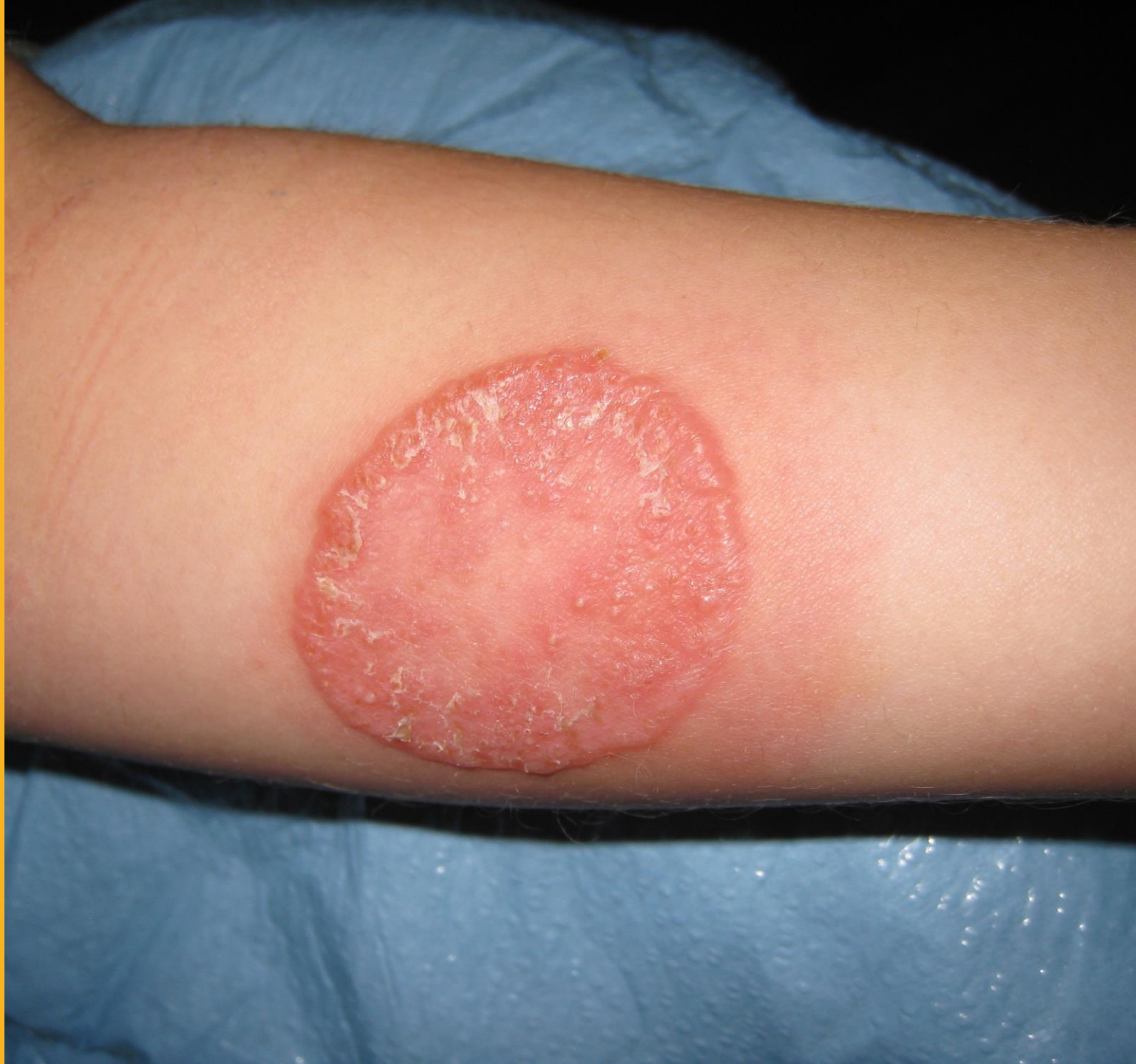## TINEA CORPORIS

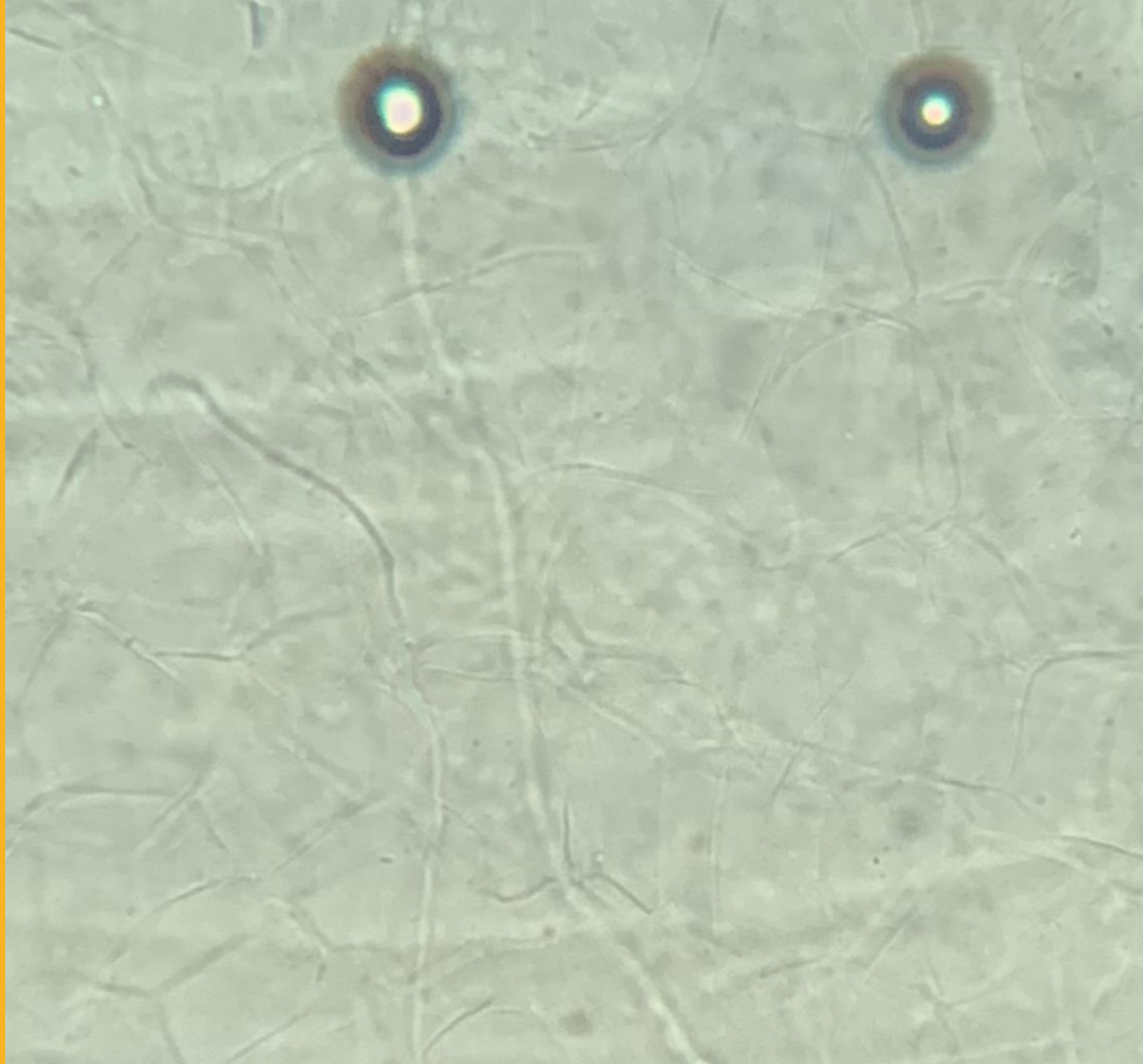
Pt with rash for 3 months

Started with small patch, very itchy  
has been applying Neosporin and  
hydrocortisone

Positive KOH

TX: Ketoconazole and or Oral  
terbinafine/itraconazole

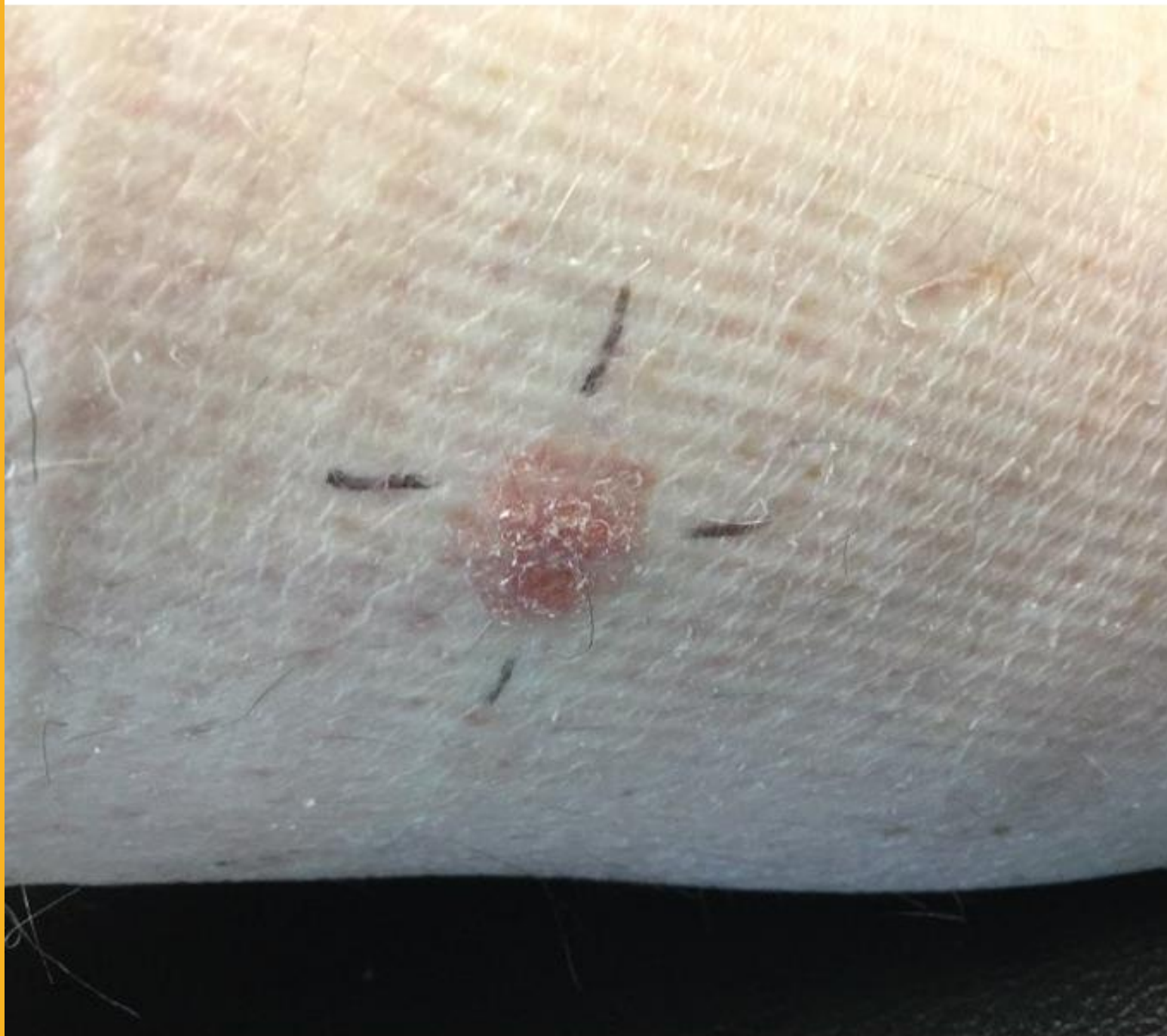



## POSITIVE KOH

Branching Hyphae





## SCC IN-SITU

50 y/o female with scaly patch on forearm for 8 weeks

Pt thought it was a bug bite, applied OTC anti-itch cream with no improvement

Shave Biopsy done

# SQUAMOUS CELL IN SITU

- Superficial
- Scaly erythematous plaque
- Usually on sun exposed areas: face, ears, arms, hands, chest
- TX; 5% fluorouracil , ED&C, excision, MOHS (only on "H zone")



# 9. WHICH ONE IS TINEA?

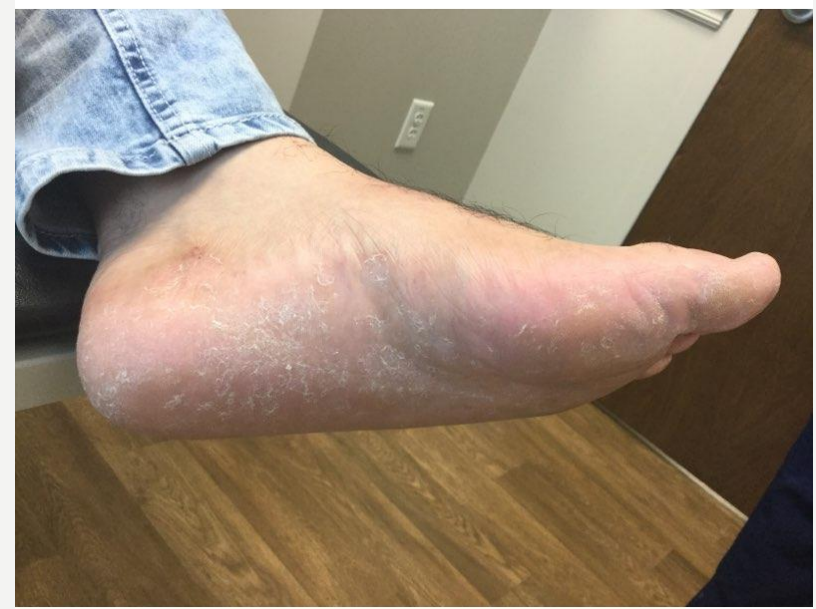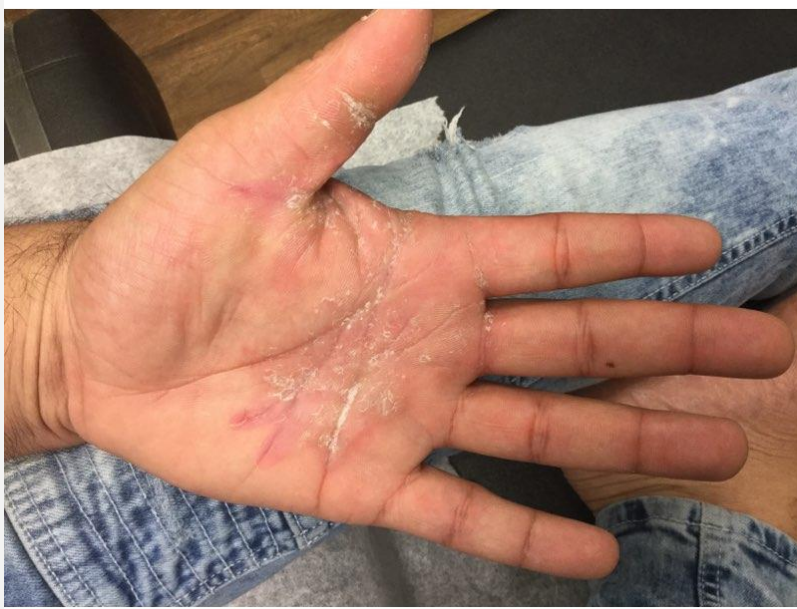**A**



**B**



# ONE HAND TWO FOOT



B

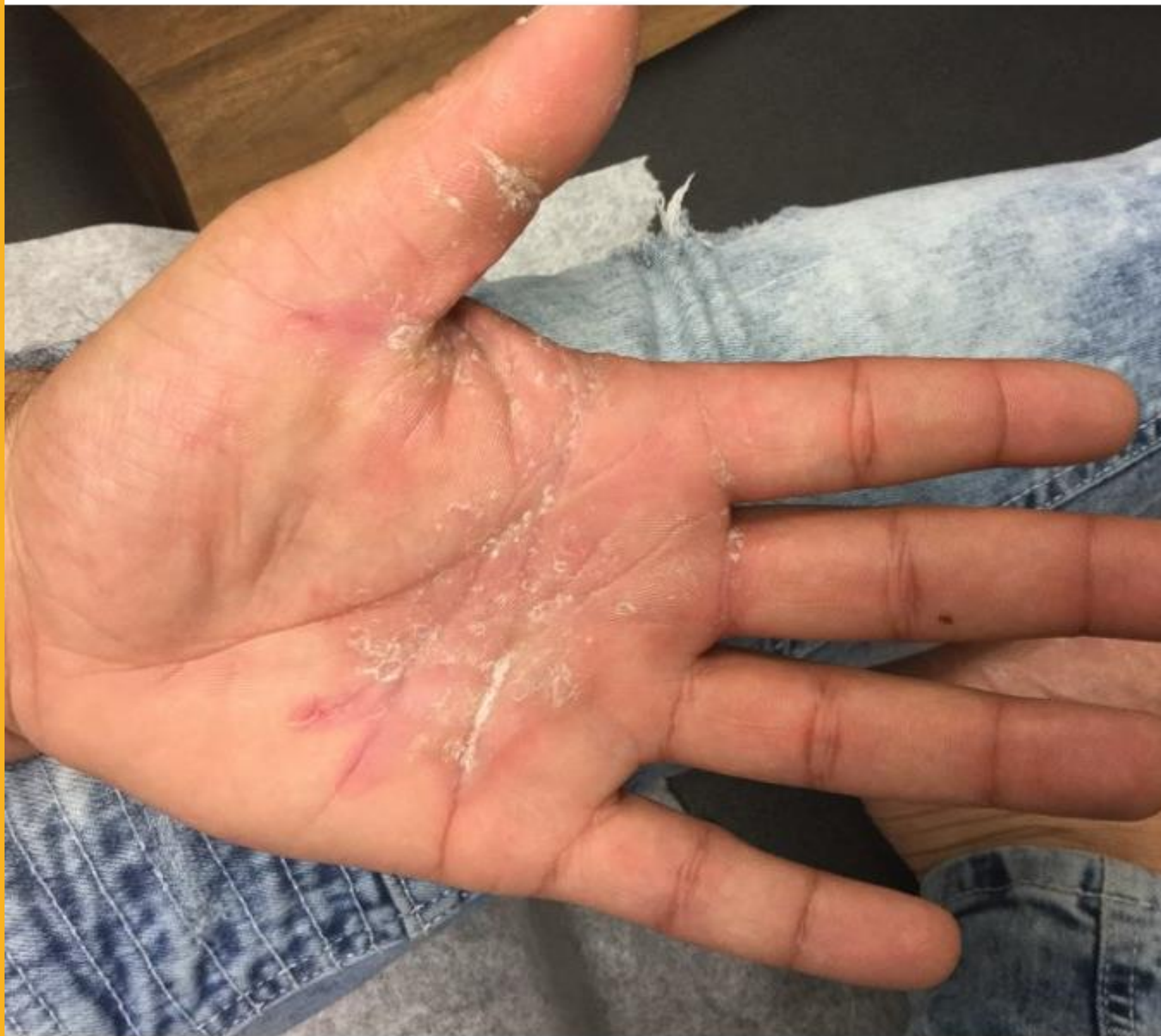## ONE HAND TWO FOOT

30y/o male with rash on ONE  
hand for three months

Area is itchy

He has been applying OTC  
hydrocortisone for two months  
and OTC moisturizers

KOH: Positive for branching  
hyphae

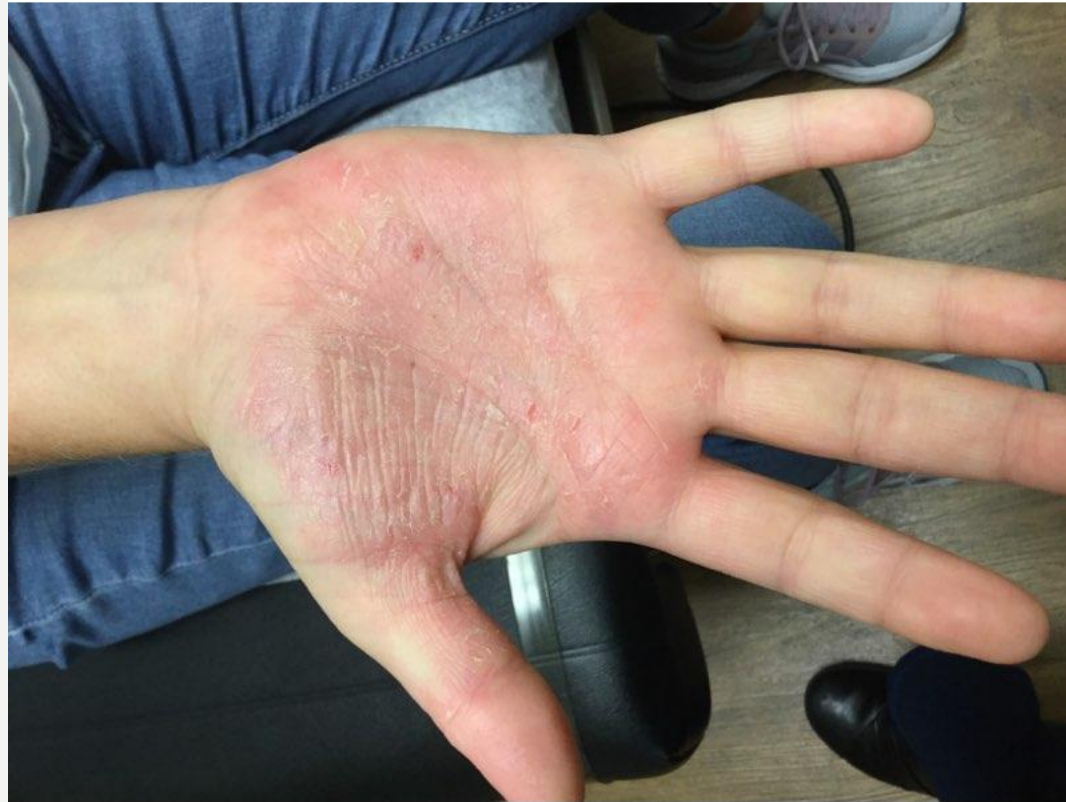



# **TINEA MANUM**

## **ONE HAND TWO FOOT**

- Usually on the palmar aspect
- Risk factor hyperhidrosis
- Feet: moccasin distribution
- TX: oral antifungal Terbinafine 250 mg 4-6 weeks
  - Antifungal powders, etc.



## HAND ECZEMA

30y/o female present with rash on bilateral hands

Very itchy

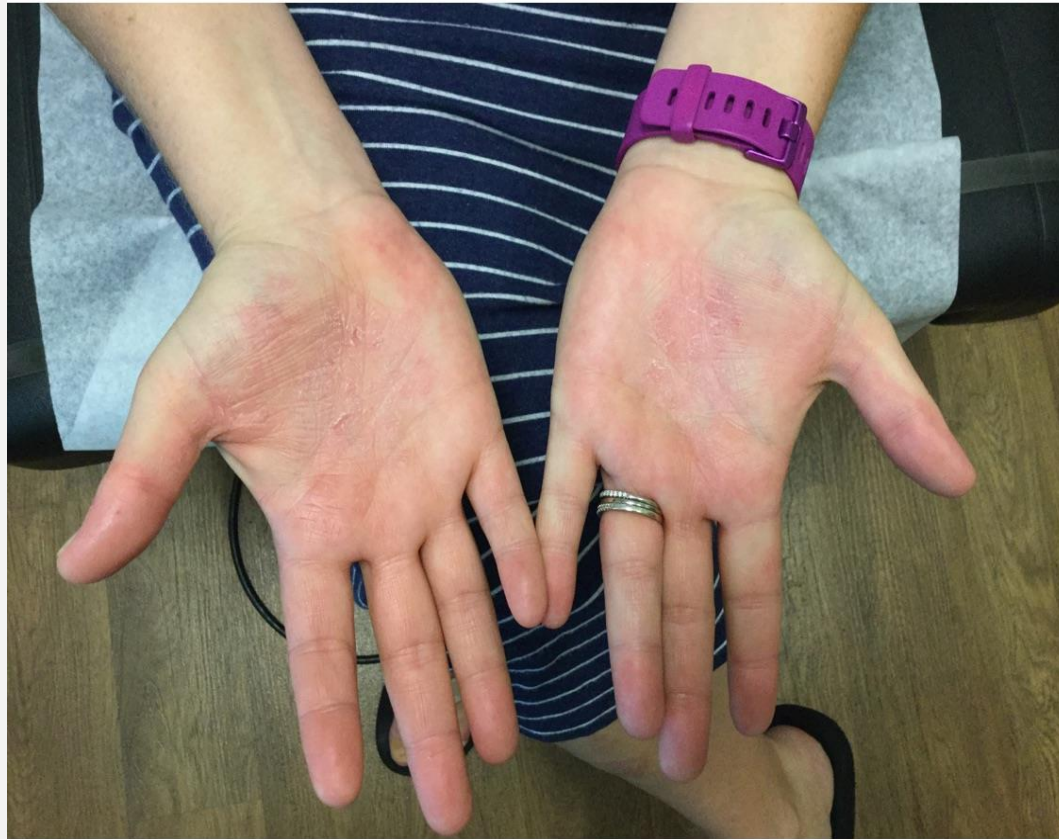Has been washing her hands a lot and also been cleaning a lot in the house

Rash only on hands

KOH negative



# **HAND DERMATITIS/ECZEMA BOTH HANDS**

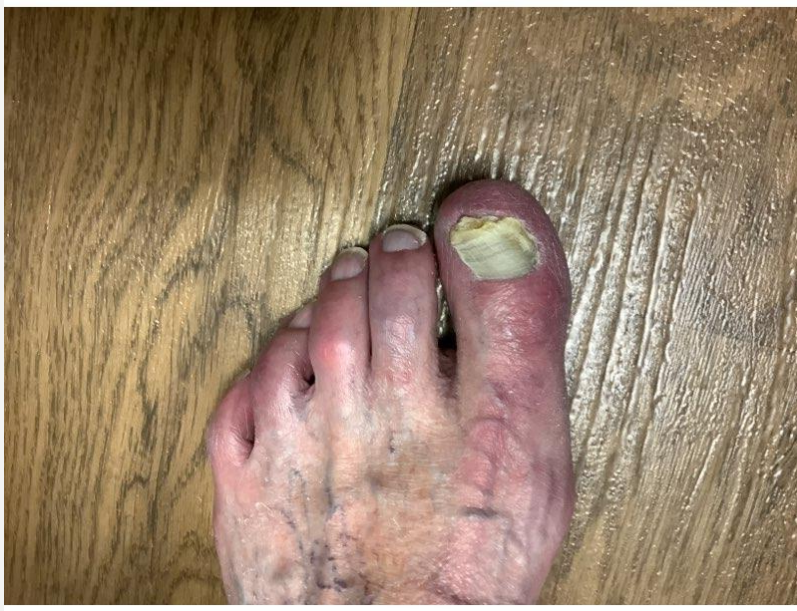

# HAND ECZEMA

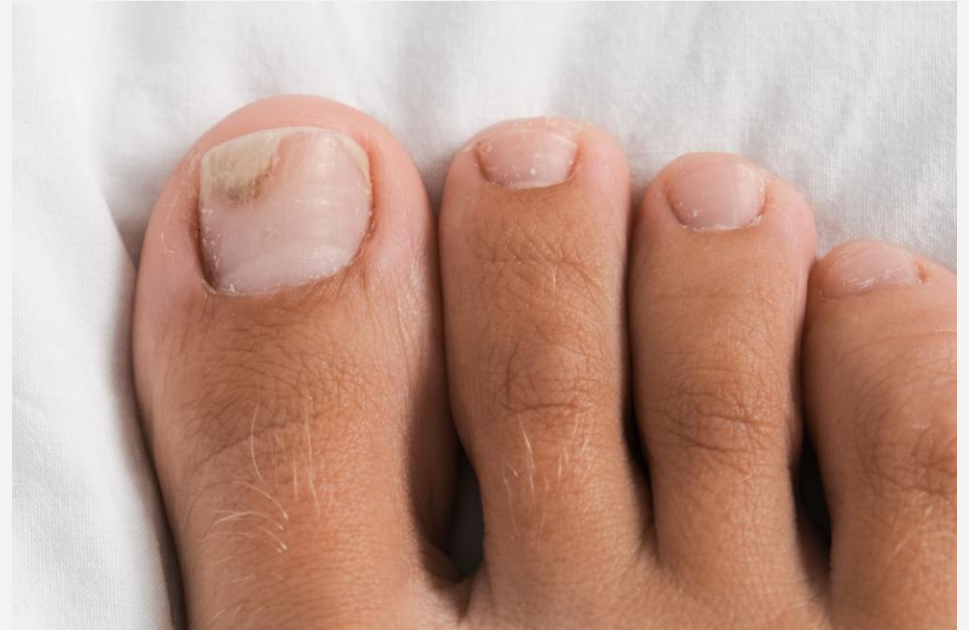- May involve Palms and Dorsal Hands
- Dyshidrotic: vesicles on sides of fingers
- Tx: topical Steroid for 3-4 weeks, severe cases Dupilumab
  - Wash with cold water
  - Moisturize daily and after all hand washing

# 10. WHICH ONE IS TINEA?

A



B





A

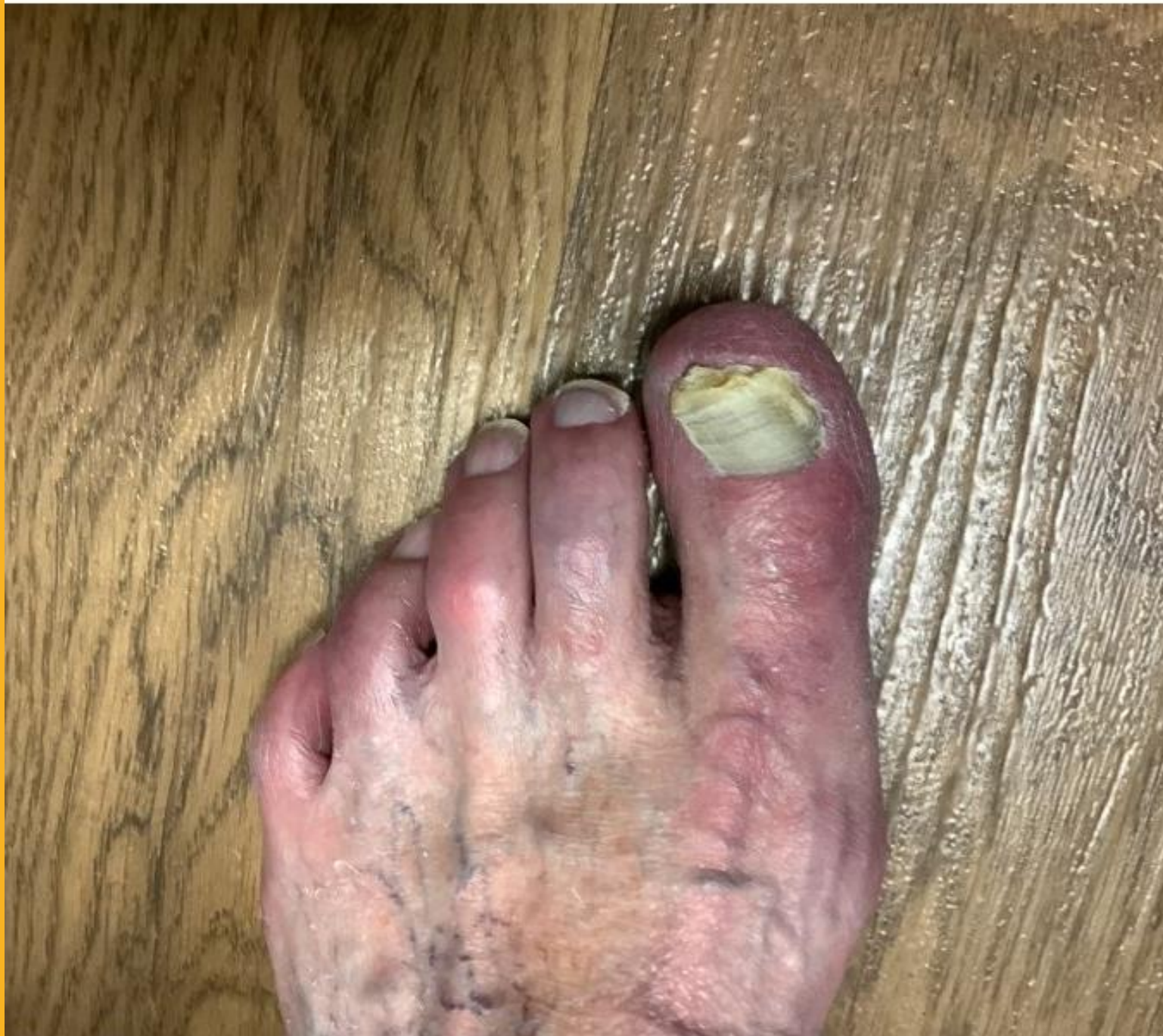## ONYCHOMYCOSIS

65y/o male with discolored and thickened great toenail for 8 months

History of Diabetes

Tried OTC fungal creams with no improvement

Nail clipping done



# ONYCHOMYCOSIS

- Yellowing discoloration of nail, onycholysis, and subungual hyperkeratosis
- *Trichophyton rubrum* (50%) *Trichophyton mentagrophytes* (20%)
- Distal Lateral Onychomycosis most common
- Proximal Subungual Onychomycosis: associated with immunosuppression/HIV
- Diagnosis before TX
  - KOH
  - Fungal Culture
  - Histology ( PAS) 92% sensitivity 72% specificity
  - PCR 95% sensitivity 100% specificity- newest not all insurance cover



# ONYCHOMYCOSIS TX

- Nails grow 1-2 mm/month or .5-.75mm/day
  - Mycological Cure: negative KOH and negative Culture
  - Clinical cure: normal nail clinically
  - Complete Cure: negative KOH or negative Culture PLUS Clinically normal nail
- 
- Terbinafine and Itraconazole are FDA approved
  - Topicals **Creams** Limited: Do NOT Penetrate Nails
  - Topical Lacquers Long Duration Needed ( 48 weeks)

**J Am Acad Dermatol.** 2019 Apr;80(4):835-851.

**J Am Acad Dermatol.** 2019 Apr;80(4):853-867.

# ONYCHOMYCOSIS TX

## TERBINAFINE

- Terbinafine 250 mg daily 6 weeks Fingernails, 12 weeks toenails
  - Fungicidal
  - Mycological cure 70%-79%
  - Complete Cure 38%- 59%
- SE: Headaches, GI, Rash (SCLE), taste change, Liver enzymes abnormalities
  - FDA recommends check serum transaminases before initiating treatment
  - Recommendations on lab monitoring and frequency lacking
- Cat B in pregnancy: avoid until after delivery or breast feeding

# ONYCHOMYCOSIS TX

## ITRACONAZOLE

- 200mg daily 12 weeks toenails
  - Mycological cure: 61%
  - Complete Cure: 47%
- Pulse dose Fingernails X2: 200mg twice daily for one week repeat in 3 weeks
- SE: HA, URI, diarrhea, abdominal pain, elevated transaminases
- Many Drug Interactions: Simvastatin, Cisapride, Felodipine, methadone, quinidine, diazepam, verapamil, glyburide, glipizide
- Contraindicated: Ventricular Disturbance and CHF
- Pregnancy Cat C: avoid

# ONYCHOMYCOSIS TX OFF LABEL

- Fluconazole 150mg per week until clear
- Terbinafine Pulse Dosing: 250 mg daily for 4 weeks on then 4 weeks off- 2 cycles
- Terbinafine Booster Dosing: additional 4 weeks after initiation of antifungal tx

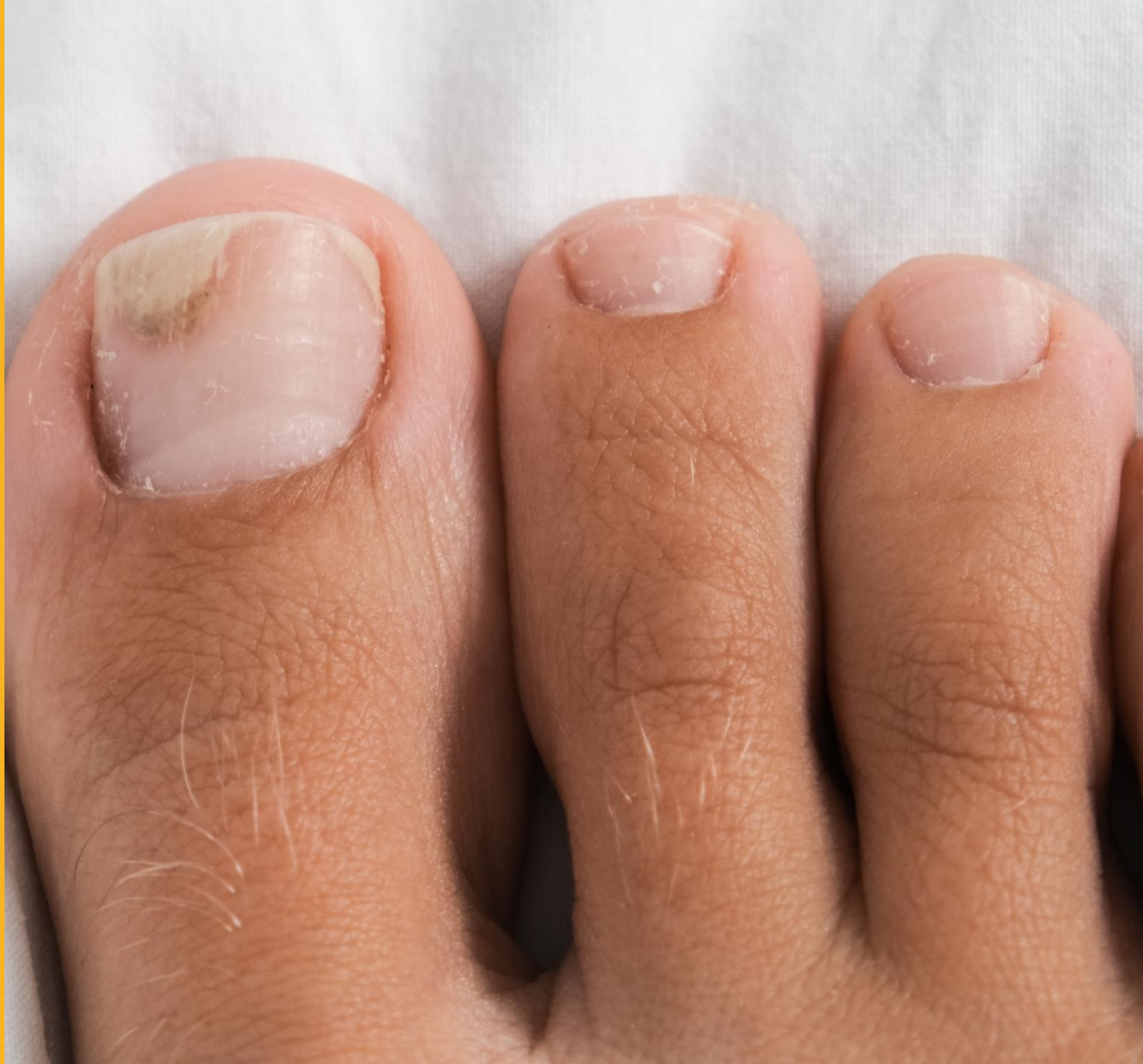**J Am Acad Dermatol.** 2019 Apr;80(4):835-851.

**J Am Acad Dermatol.** 2019 Apr;80(4):853-867.

# ONYCHOMYCOSIS: TOPICALS LACQUER & SOLUTION

- Ciclopirox 8% Lacquer : Daily for 24 weeks fingernails, daily for 48 weeks toenails
  - Mycological cure: 29-36%
  - Complete cure: 5.5- 8.5%
- Effinaconazole 10% Solution : daily for 48 weeks toenails
  - Mycological cure: 55-53%
  - Complete cure: 15-17%
- Tavaborole 5% Solution : daily for 48 weeks toenails (does not degrade nail polish)
  - Mycological cure: 31-35%
  - Complete cure: 6-9%





## ONYCHOLYSIS

30 y/o female presented with nail discoloration for two months

Pt has been training for the Disney Marathon and running more

# ONYCHOLYSIS

- Separation of nail plate
- More common in women
- Trauma, psoriasis, lichen planus, onychomycosis
- Medications/photo onycholysis
  - Doxycycline
  - Fluoroquinolones
  - psoralens

Tx: topical moisturizers: urea

# 11. WHICH ONE IS TINEA?

**A**



**B**



A

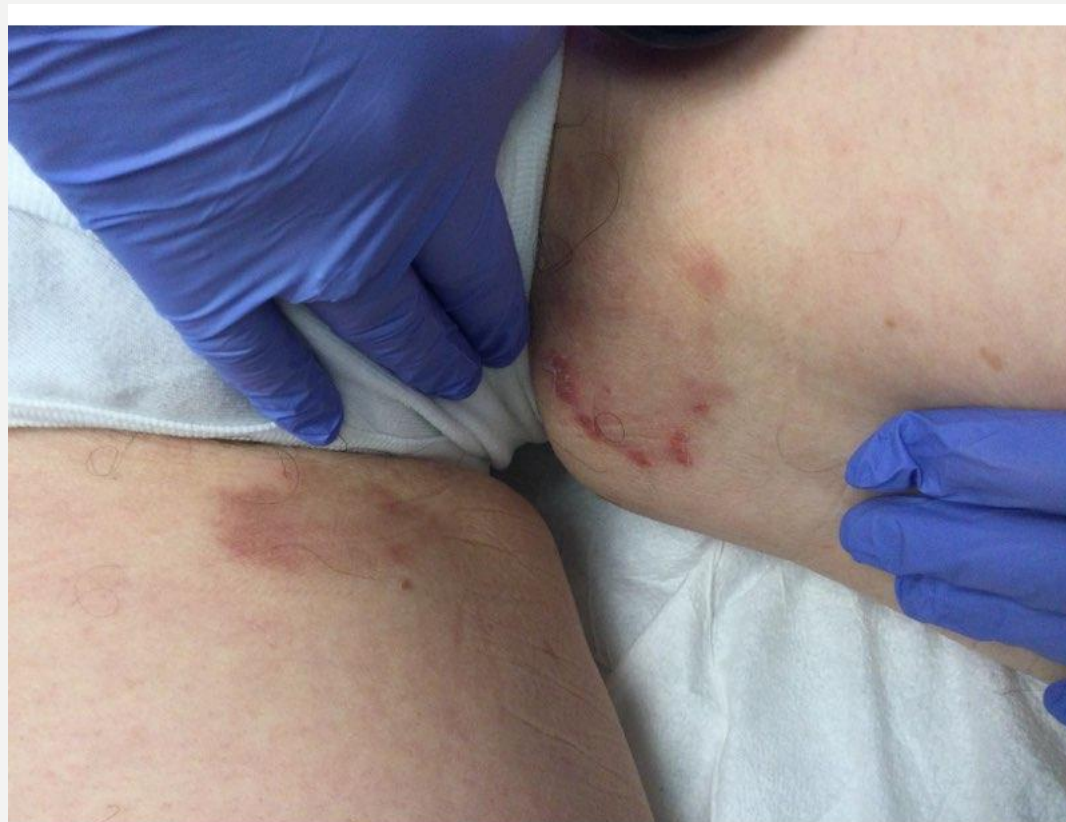## TINEA CRURIS

65 y/o male with rash for 4 months

Itchy

Has been applying OTC Lamisil

Also has a scaly rash on his  
Bilateral feet

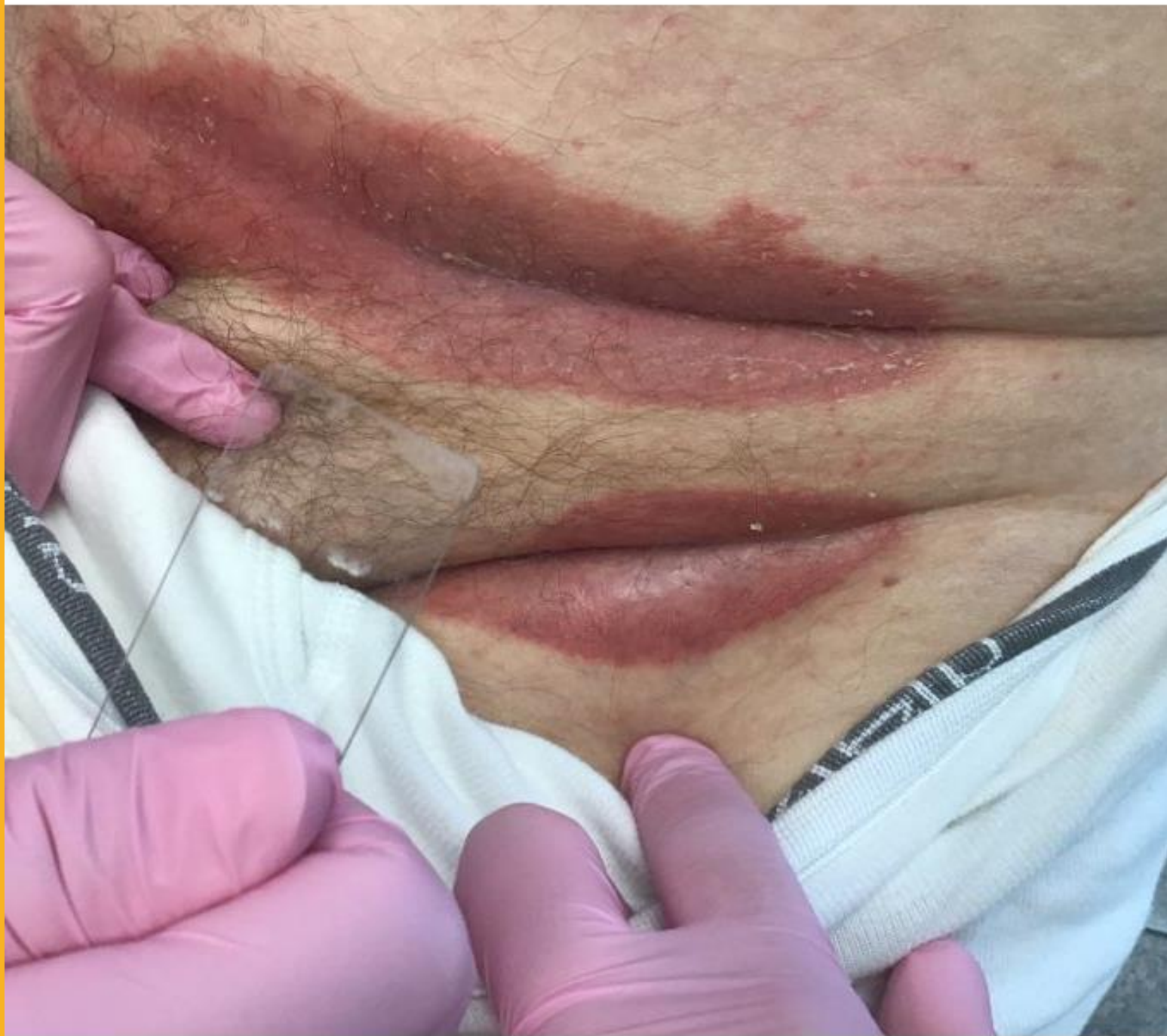

# **TINEA CRURIS**

## **“JOCK ITCH”**

- Favors upper Inner thighs, buttocks, and lower abdomen
  - Rarely involves Scrotum
- More common in Males
- Many times associated with Tinea Pedis and Onychomycosis
- TX: topical antifungal twice daily for 2-4 weeks +/- Oral Terbinafine 250mg daily for 4 weeks





## INVERSE PSORIASIS

60y/0 male with rash for 2 years.  
Has been occurring off and on

Mild itching

Treated with Ketoconazole cream  
and antifungal powder

Rash also present in axillary  
regions

KOH negative

# INVERSE PSORIASIS

- Psoriasis in interiginous areas
- Groin, axillary, pannus
- Erythematous beefy red macule with scant amount of scale
- Tx: topical steroids, Tars, light treatments, biologics, MTX, Apremilast, Tapinarof cream, Roflumilast cream, topical calcipotriene

# 12. WHICH IS TINEA ?

A



B





A

## TINEA INCOGNITO

50 y/o female with rash for one year

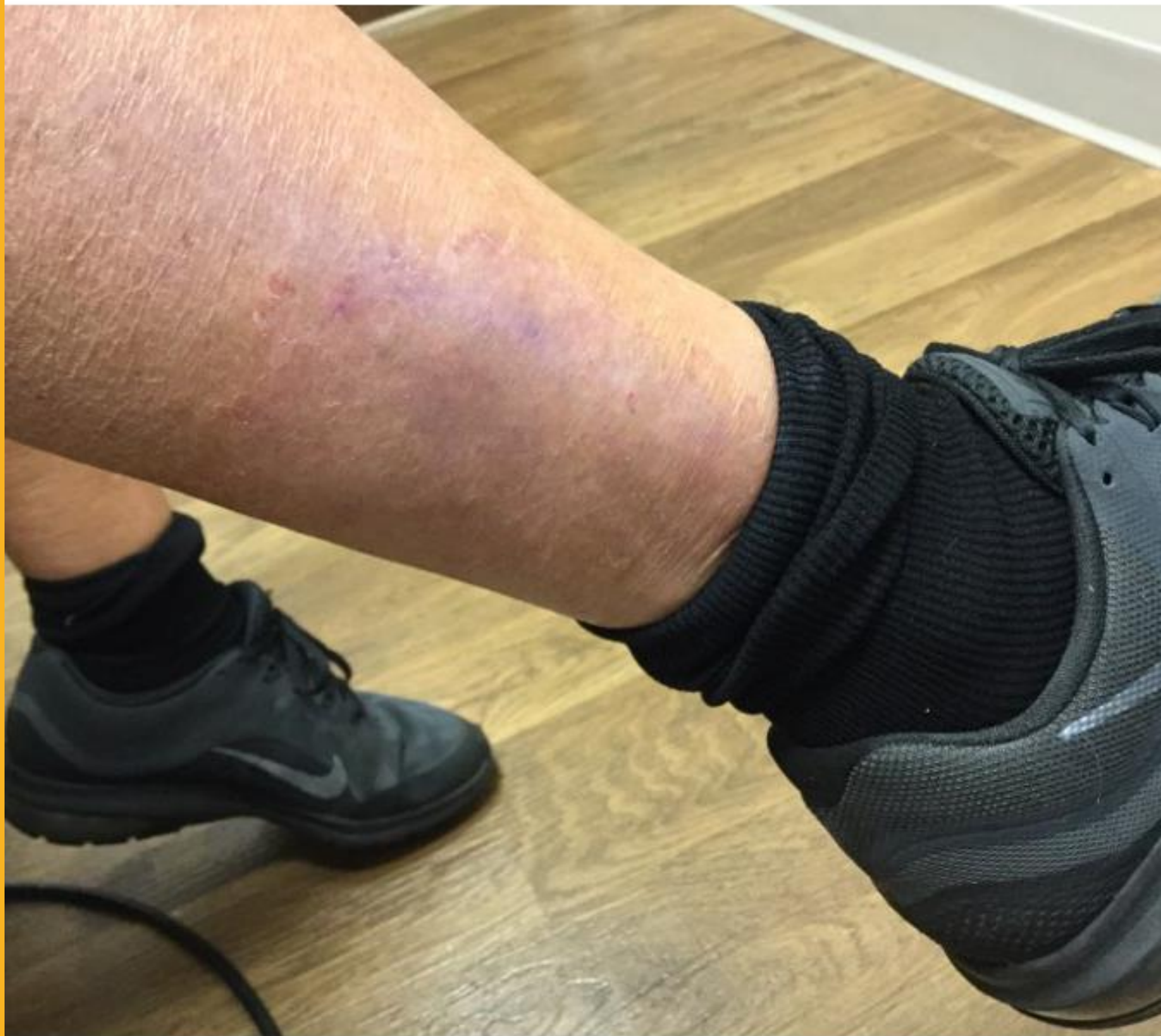Very Itchy

Initially tried OTC hydrocortisone but would only temporarily help itch

PCP prescribed triamcinolone, pt has used this off and off for months now

Rash has never gone away

Pustules present with scant scale

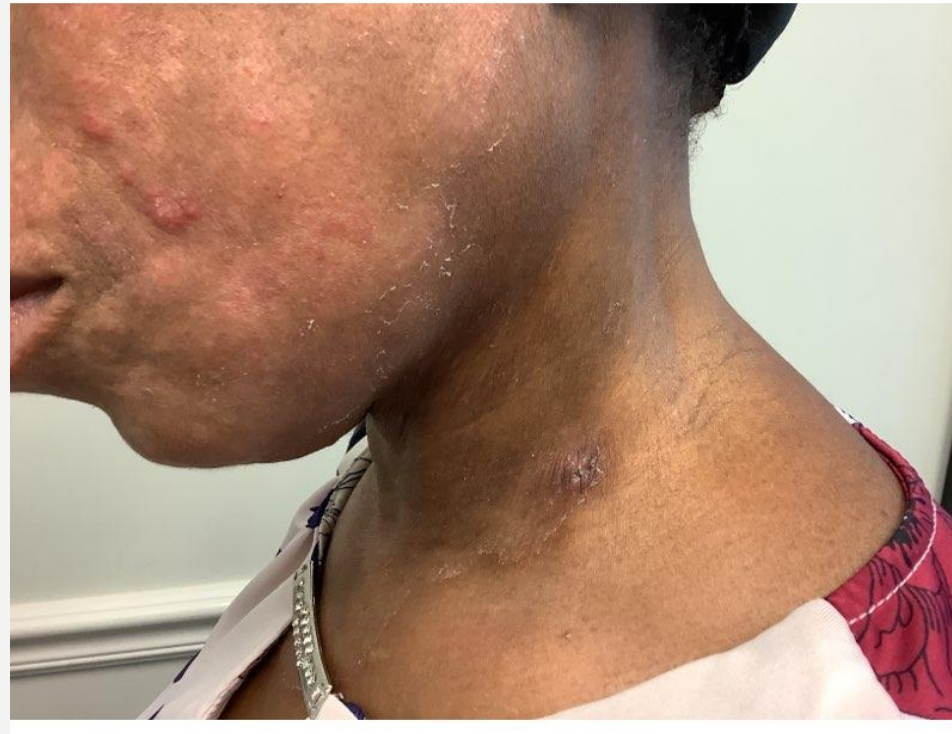

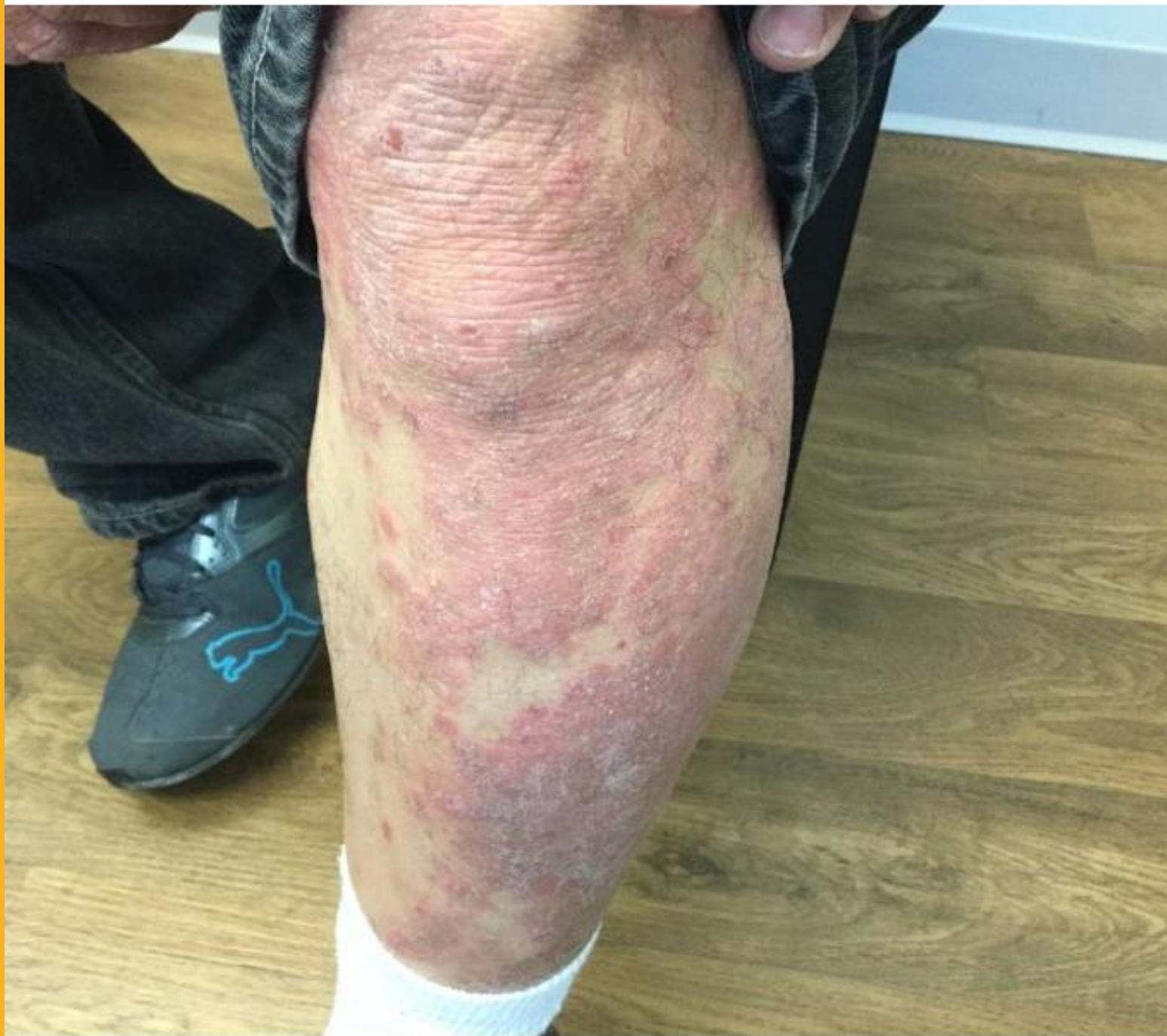# TINEA INCOGNITO

- Results from treating dermatophyte infection with steroids: Deep pustular/papular type of tinea
- Presents with pustules and lacks an advancing raised scaling border
- Many times KOH and culture negative
- Tx: Oral terbinafine 250mg for 4-6 weeks



# MAJOCCHI'S GRANULOMA





## PSORIASIS

45 y/o male with thick scaly rash for 5 years

Rash on his elbows, scalp, abdomen, knees, and gluteal cleft

Treated with topical triamcinolone with no resolution



# IT TRULY TAKES A TEAM





**THANK YOU!**

**QUESTIONS ?**

# REFERENCES

- Gupta AK, Mays RR, Versteeg SG, Piraccini BM, Shear NH, Piguet V, Tosti A, Friedlander SF. Tinea capitis in children: a systematic review of management. *J Eur Acad Dermatol Venereol*. 2018 Dec;32(12):2264-2274.
- El-Gohary M, van Zuuren EJ, Fedorowicz Z, Burgess H, Doney L, Stuart B, Moore M, Little P. Topical antifungal treatments for tinea cruris and tinea corporis. *Cochrane Database Syst Rev*. 2014 Aug 4;(8):CD009992.
- Miazek N, Michalek I, Pawlowska-Kisiel M, Olszewska M, Rudnicka L. Pityriasis Alba--Common Disease, Enigmatic Entity: Up-to-Date Review of the Literature. *Pediatr Dermatol*. 2015 Nov-Dec;32(6):786-91.



# REFERENCES

- Wang J, Khachemoune A. Granuloma Annulare: A Focused Review of Therapeutic Options. *Am J Clin Dermatol*. 2018 Jun;19(3):333-344.
- Piette EW, Rosenbach M. Granuloma annulare: Pathogenesis, disease associations and triggers, and therapeutic options. *J Am Acad Dermatol*. 2016 Sep;75(3):467-479.
- Zhou C, Li X, Wang C, Zhang J. Alopecia Areata: an Update on Etiopathogenesis, Diagnosis, and Management. *Clin Rev Allergy Immunol*. 2021 Dec;61(3):403-423.

# REFERENCES

- Schadt C. Pityriasis Rosea. JAMA Dermatol. 2018 Dec 1;154(12):1496.
- Metin A, Dilek N, Bilgili SG. Recurrent candidal intertrigo: challenges and solutions. Clin Cosmet Investig Dermatol. 2018 Apr 17;11:175-185.
- Drake LA, Dinehart SM, Farmer ER, Goltz RW, Graham GF, Hordinsky MK, Lewis CW, Pariser DM, Skouge JW, Webster SB, Whitaker DC, Butler B, Lowery BJ, Elewski BE, Elgart ML, Jacobs PH, Leshner JL Jr, Scher RK. Guidelines of care for superficial mycotic infections of the skin: tinea capitis and tinea barbae. Guidelines/Outcomes Committee. American Academy of Dermatology. J Am Acad Dermatol. 1996 Feb;34(2 Pt 1):290-4.

# REFERENCES

- Woo TE, Somayaji R, Haber RM, Parsons L. Diagnosis and Management of Cutaneous Tinea Infections. *Adv Skin Wound Care*. 2019 Aug;32(8):350-357.
- Frymus T, Gruffydd-Jones T, Pennisi MG, Addie D, Belák S, Boucraut-Baralon C, Egberink H, Hartmann K, Hosie MJ, Lloret A, Lutz H, Marsilio F, Möstl K, Radford AD, Thiry E, Truyen U, Horzinek MC. Dermatophytosis in cats: ABCD guidelines on prevention and management. *J Feline Med Surg*. 2013 Jul;15(7):598-604.
- Lipner SR, Scher RK. Onychomycosis: Treatment and prevention of recurrence. *J Am Acad Dermatol*. 2019 Apr;80(4):853-867.
- Lipner SR, Scher RK. Onychomycosis: Clinical overview and diagnosis. *J Am Acad Dermatol*. 2019 Apr;80(4):835-851.
- James W, Berger T, Elston D. 2011. *Andrews' Diseases of the Skin*. 11<sup>th</sup> Edition, London, Saunders Elsevier