
WHAT'S NORMAL ANYWAYS? **ABNORMAL UTERINE BLEEDING**

Aleece Fosnight, MSPAS, PA-C, CSCS, CSE, NCMP

Urology, Women's Health, Sexual Medicine

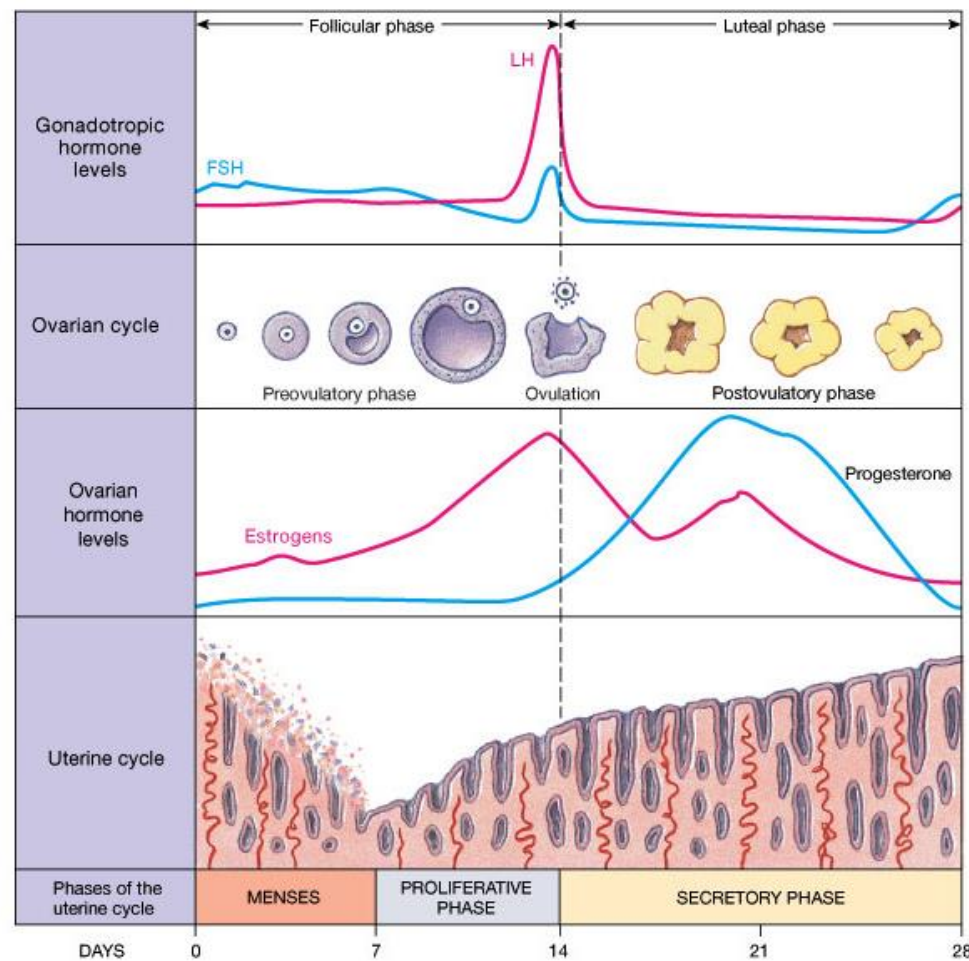
Skin, Bones, Hearts, and Private Parts 2021

aleece@fosnightcenter.com

OBJECTIVES

- Define the pathophysiology of abnormal uterine bleeding.
- Discuss the PALM-COEIN classification system for diagnostic work-up.
- Develop a treatment plan to include non-surgical and surgical options.
- Application with clinical presentations through diagnostic work-up and treatment strategies.

SO...WHAT'S NORMAL?



Normal Menstrual Cycle

Follicular Phase

AKA: Proliferative Phase (Uterine)

Early = Epithelium grows

Late = Endometrium is thick secondary to mitotic growth of tubular glands

Ends = Estradiol peak with LH surge and meiosis of dominant follicle

Luteal Phase

AKA: Secretory Phase (Uterine)

Endometrial stromal height fixed, stroma edematous, glands tortuous, arteries spiral
Progesterone from corpus luteum
If no hCG, follicular atresia begins

Menstrual Phase

Triggered by the fall in progesterone

Vasospasm and ischemic necrosis of the endometrium

New follicles = rise in estrogen = endometrial healing

SO... WHAT'S NORMAL?

Frequency of menses	Duration of bleeding	Volume of Blood Loss
Infrequent = >38 days	Shortened = <3 days	Light = <5mL
Normal = 21-28 days	Normal = 5-7 days	Normal = 5-80mL
Frequent = <21 days	Prolonged = >8 days	Heavy = >80mL

1 Normal soaked “regular” product = 5mL of blood

1 “super” or “maxi” product = 10mL of blood

DEFINITIONS

Heavy Menstrual Bleeding

Previously known as menorrhagia – regular but excessively heavy bleeding

Metrorrhagia

Intermittent intermenstrual bleeding

Menometrorrhagia

Irregular, frequent, heavy and light bleeding

Amenorrhea

No menses for 3 cycles (primary or secondary)

Polymenorrhea

Frequent menses <21 days but not heavy in duration

Oligomenorrhea

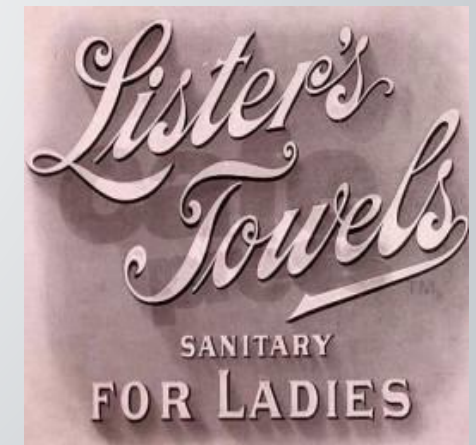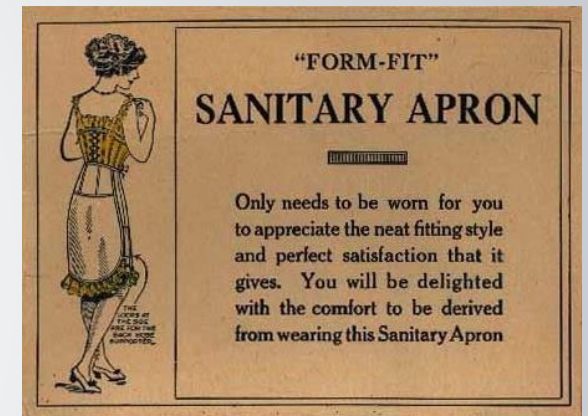
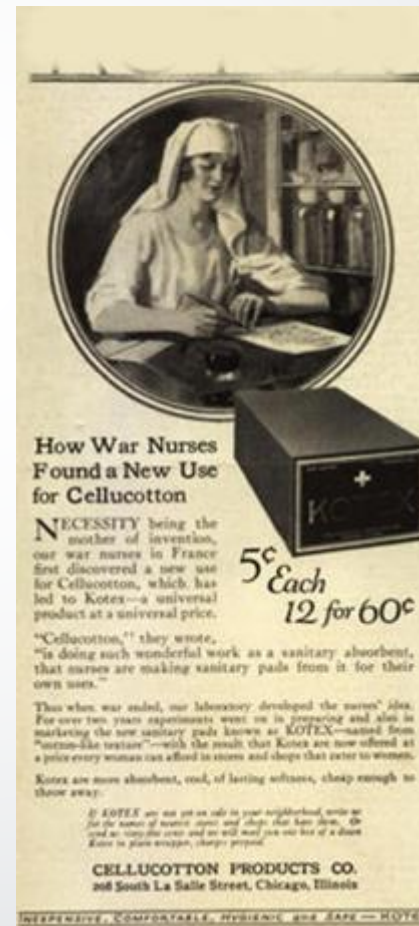Regular menses with short duration/quality

Hypomenorrhea

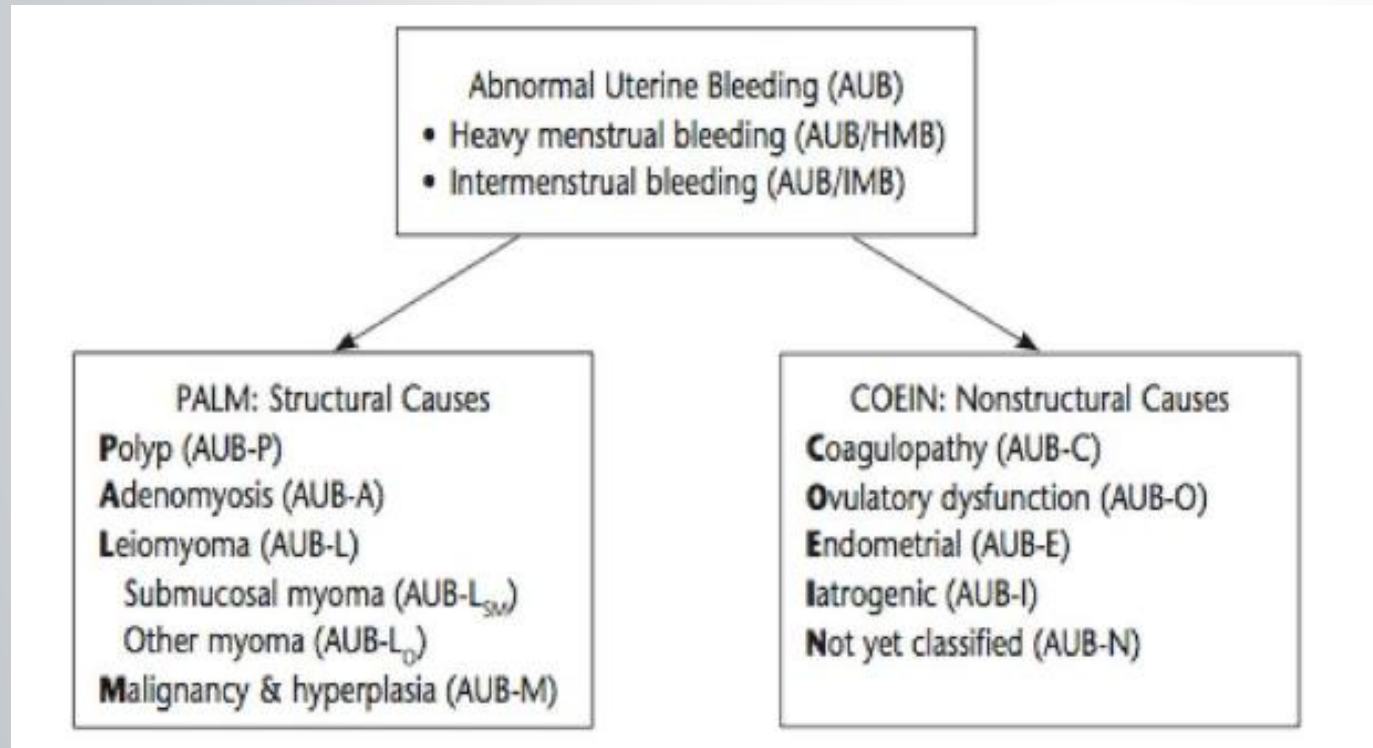
Regular menses with light bleeding

HISTORY, HISTORY, HISTORY

- Menstrual history (This is the BIGGIE!)
 - Acute vs. Chronic
 - Menarche, cramping
- Bleeding history
 - Qualify and quantify the bleeding – type of products used, frequency of change saturation, clotting
- Sexual history
 - Postcoital bleeding, dyspareunia
- Prior surgeries, including GYN
- Hormone usage
 - COC pills – compliancy and what is “normal” OFF any hormonal contraceptives
- Medications
 - Anticoagulants, OTC herbal supplements



PALM-COEIN CLASSIFICATION



Heavy Menstrual Bleeding

- Leiomyoma
- Adenomyosis
- Coagulopathies
- Malignancies or hyperplasia
- Iatrogenic
- Polyps
- Endometrial abnormalities

Ovulatory Dysfunction

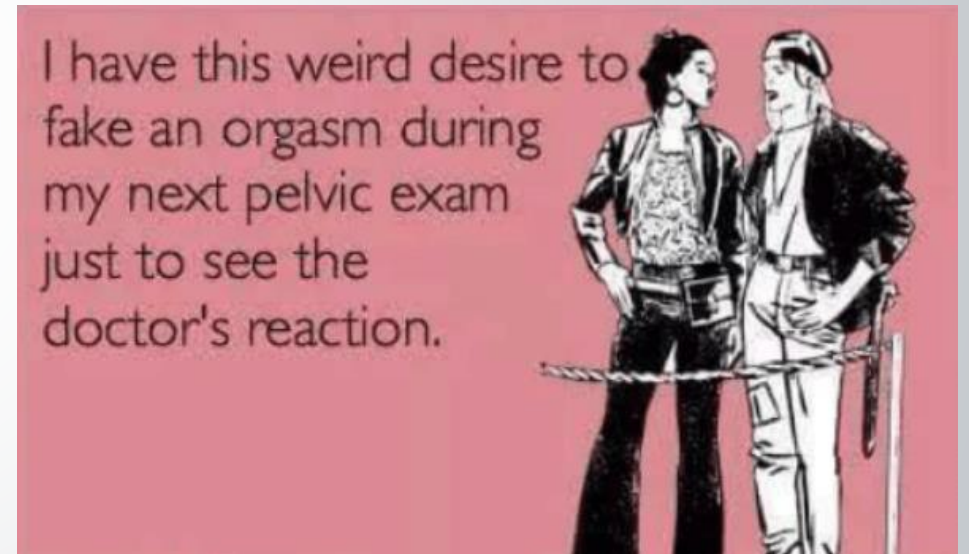
- Polycystic ovarian syndrome
- Thyroid disease
- Hyperprolactinemia
- Anovulation
- Menopausal transition
- Endometrial abnormalities



Physical
Exam

PHYSICAL EXAM

- General examination
 - Head-to-Toe
 - Fever, ecchymoses, petechiae, thyroid gland, evidence of hyperandrogenism, acanthosis nigricans, galactorrhea
- Pelvic Exam with/without PAP
 - Should be done on ALL patients complaining of AUB
 - Potential sites of bleeding: vulva, vagina, cervix, urethra, anus, perineum
 - Size and contour of uterus, uterine mobility
 - Pelvic masses
 - Current active bleeding – assess location of bleeding, presence of blood clots
 - Patients who are hemodynamically unstable – consider OR for further investigation and cauterization

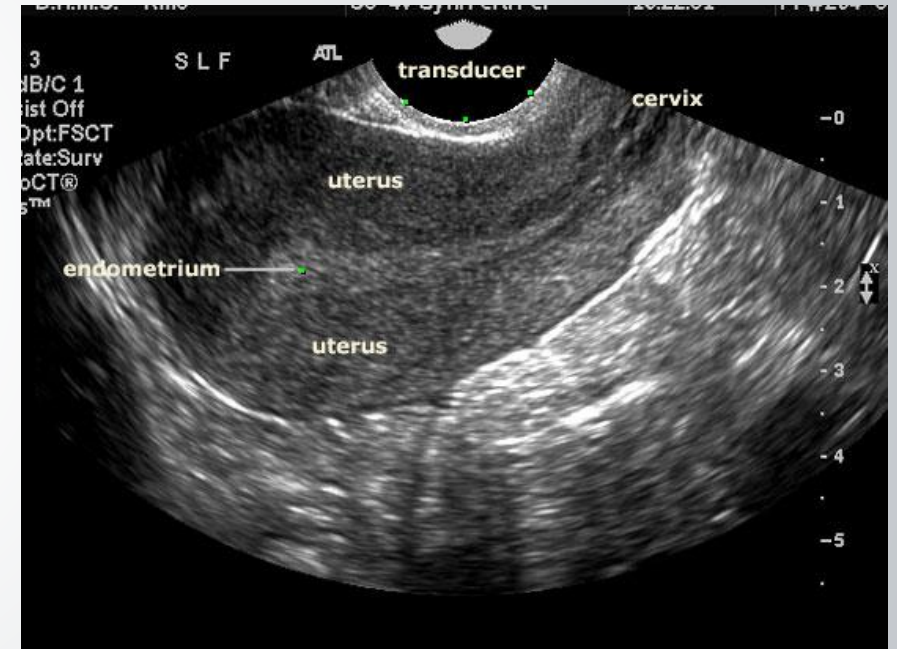


WORK-UP: LABS

- Labs should be history and physical dependent
- Pregnancy test should be performed on ALL patients
- CBC or Hgb/Hct with Ferritin level
- PAP smear
- Cultures for infection
- Other possible labs to consider
 - Thyroid studies
 - Prolactin
 - Estrogens
 - Androgens
 - FSH/LH
 - Coagulation studies (bleeding disorder)

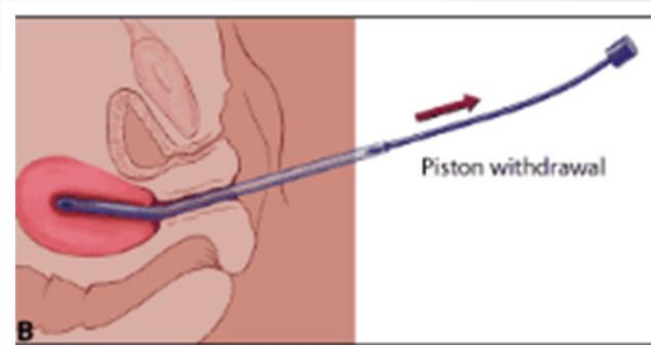
WORK-UP: DIAGNOSTIC IMAGING

- Transvaginal US (TVUS) – First choice
 - Caution with evaluation of endometrial stripe in premenopausal women
- Intracavitary Pathology – Advanced Imaging
 - Saline infusion sonography (SIS)
 - Ultrasound with instillation of sterile saline into the uterine cavity
 - Helps to delineate polyps and myomas
 - Hysteroscopy
 - Direct visualization of the uterine cavity
 - Diagnostic AND therapeutic
 - Targeted biopsy/excision
 - D+C may be performed at the same time
- MRI and CT – only to evaluate the pelvis for metastatic disease or other pelvic abnormalities

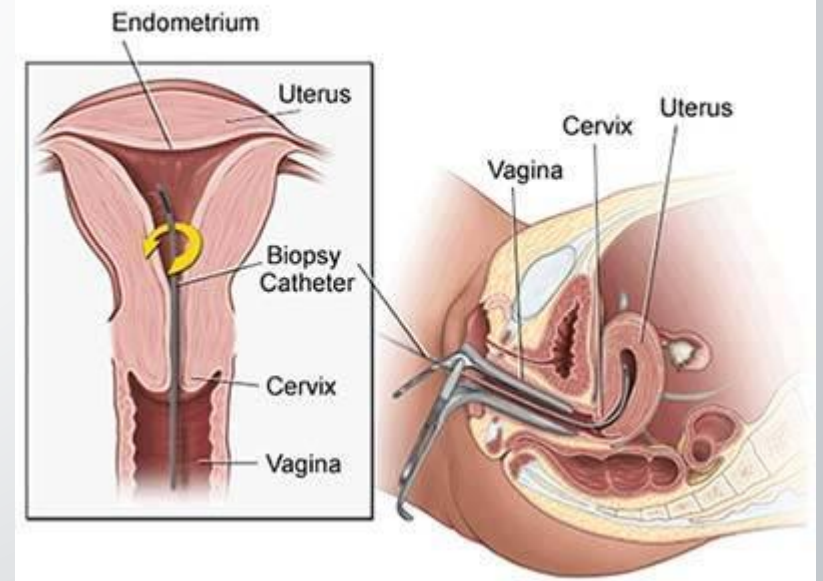


WORK-UP: ENDOMETRIAL BIOPSY

- Pregnancy needs to be excluded first
- Women 45 years or older should be evaluated
 - Should be considered first line test
- Women younger than 45 years, only if...
 - Unresponsive to medical management
 - History of unopposed estrogen exposure (obese or PCOS)
 - High risk of endometrial cancer (Tamoxifen, Lynch/Cowden Syndrome, and/or family history of endometrial cancer)
- Contraindications: active vagina/pelvic infection, bleeding diathesis, pregnancy



Endometrial Biopsy



ENDOMETRIAL BIOPSY RESULTS

- Updated 2015 WHO
 - Endometrial hyperplasia with atypia
 - Higher risk of endometrial cancer
 - Hysterectomy is first line treatment
 - May discuss progestins if fertility is desired or poor surgical candidate
 - Endometrial hyperplasia without atypia
 - Simple – treat with progestins (oral progesterone or LNG-IUS) or OCPs
 - Complex – treat with progestin

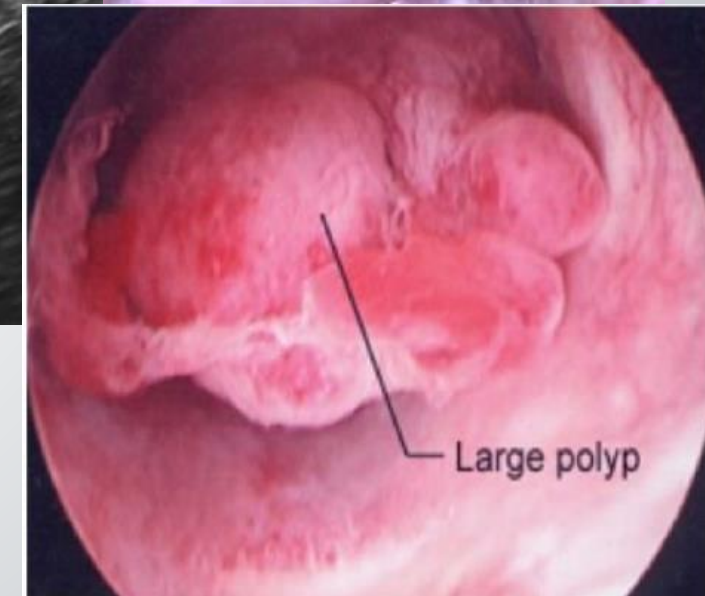
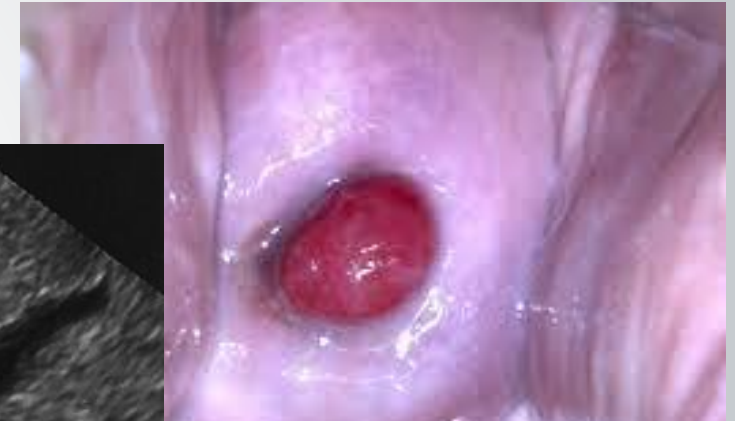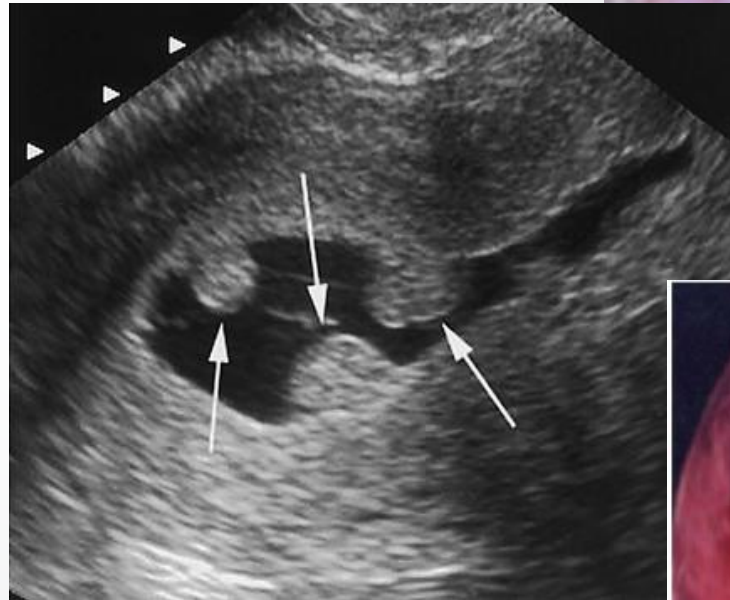
Endometrial hyperplasia is estrogen-dependent – progestins induce regression through decreasing glandular cellularity by triggering apoptosis.

A LOOK AT YOUR... PALM

- P – Polyps
- A – Adenomyosis
- L – Leiomyomas
- M – Malignancy or hyperplasia (see endometrial biopsy)

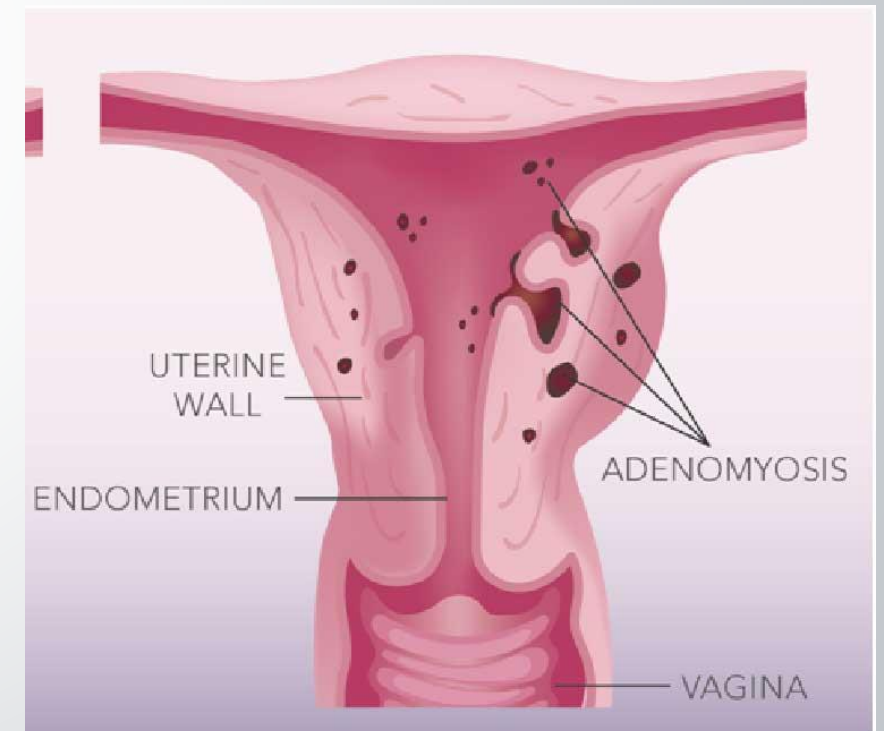
POLYPS (AUB-P)

- Cervical vs endometrial
- Cervical = visualized during pelvic exam
- Endometrial = US or hysteroscopy
- Presentation can be asymptomatic, intermenstrual bleeding, postmenopausal bleeding
- EMB sampling not necessary
- Management includes removal in symptomatic women and removal in asymptomatic women with increased risk of cancer



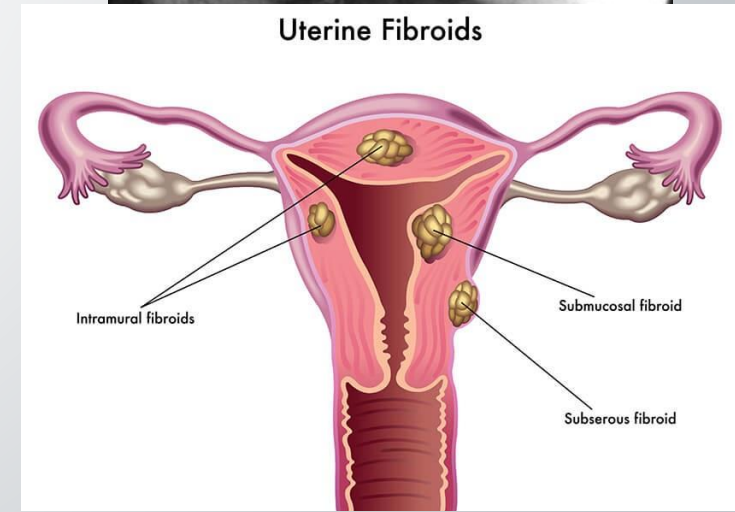
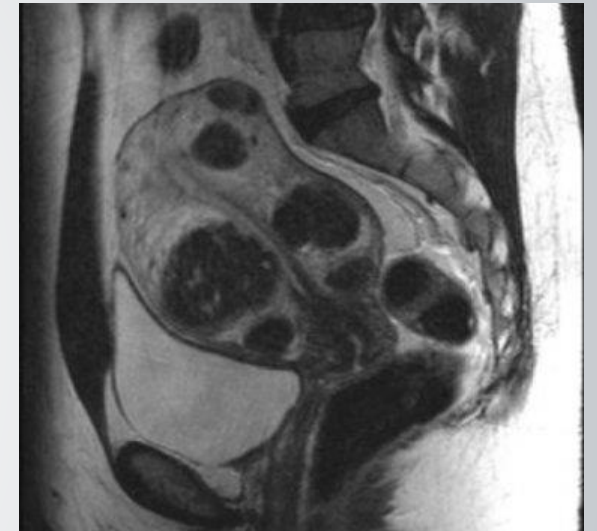ADENOMYOSIS (AUB-A)

- Definition = endometrium breaks through the myometrium (think endometriosis in the wall of the uterus)
- Presentation includes heavy menstrual bleeding, painful/cramping periods, bloating
- Women in their 40's and 50's
- Prior uterine surgery – Cesarean section, fibroid removal
- Diagnosis
 - Clinical correlation with pelvic exam with enlarged/tender uterus
 - Transvaginal US
 - MRI can be helpful
 - EMB sampling not useful
- Management includes:
 - Anti-inflammatory medications
 - Hormone medications (oral, DEPO, IUD)
 - Hysterectomy after other treatments have failed



LEIOMYOMA (AUB-L)

- AKA = Uterine Fibroids → benign muscular tumor growth (myomas)
- Most common indication for hysterectomy in the US
- Presentation includes heavy menstrual bleeding, painful/cramping periods, bloating, pelvic fullness, urination frequency, constipation, dyspareunia (rarely asymptomatic)
- Diagnosed through physical exam/pelvic exam, ultrasound – other advanced imaging not necessary (although MRI can be helpful)
- EMB sampling not necessary (difficult based on position)
- Treatment options
 - Watchful waiting and conservative methods
 - Medications: GnRH agonists, LNG-IUS, Tranexamic acid, NSAIDS
 - Procedures: MRI FUS, uterine artery embolization, myolysis, myomectomy, hysterectomy
 - Endometrial ablation can aid in bleeding, but not the fibroid

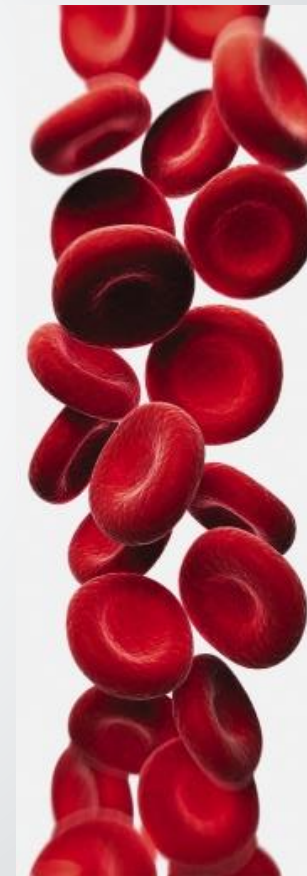

A LOOK AT YOUR... COEIN

- C – Coagulopathy
- O – Ovulatory Dysfunction
- E – Endometrial Disorder
- I – Iatrogenic
- N – Not otherwise classified

COAGULOPATHY (AUB-C)

- Most common causes = ITP, VonWillebrand's, Glanzman's, Thallasemia major, Fanconi's anemia
- Don't forget about your anticoagulated patients
 - Warfarin/Coumadin, Eliquis, Xarelto, ASA, ginseng, ginkgo, motherwort
- Labs to consider = bleeding time, INR, PTT, platelet count, VonWillebrand's screen
- 10% of adolescents have a coagulopathy
- Tranexamic acid may add benefit
- Consider referral to hematology/oncology



OVULATORY DISORDER (AUB-O)

*** Anovulation – most common cause of AUB ***

Physiologic Causes	Pathologic Causes
Immature hypothalamic-pituitary-ovarian axis (adolescents) Perimenopause Lactation Pregnancy	Hyperandrogenic anovulation (PCOS, congenital adrenal hyperplasia, androgen producing tumors) Hypothalamic dysfunction (anorexia nervosa) Hyperprolactinemia Thyroid disease Primary pituitary disease Premature ovarian failure Medications

ENDOMETRIAL DISORDER (AUB-E)

- Presents with predictable, cyclic bleeding with no other cause identified
- Best treated with progestins and/or surgery
- Considerations:
 - Endometrial inflammation or infection
 - Local inflammatory response or endometrial vasculogenesis

IATROGENIC (AUB-I)

- Think outside the box...
 - Hormonal contraceptives
 - SSRIs and TCAs
 - Antipsychotics (1st generation and Risperdone)
 - Anticonvulsants
 - Antibiotics
 - Smoking



NOT OTHERWISE CLASSIFIED (AUB-N)

Chronic endometritis

Arteriovenous Malformations

Myometrial hypertrophy

**Ready to put your
knowledge to the test???**

**Clinical Case
Presentations**

CASE PRESENTATION #1

- A 37 year old Caucasian female, G1P1001, is being evaluated for a 5 month history of heavy menstrual bleeding. Reports menstruating for the past 9 days, going through 10 maxi pads or more per day with passing of blood clots. States that she has been fatigued but no dizziness/lightheadedness.
- States that her and her husband would like to conceive another child next year. Nonsmoker.
- Past Medical History = T2DM
- Vitals = Afebrile, BP 130/70, HR 82, BMI 38.6
- Physical Exam = WNL, unremarkable
- Pelvic Exam = moderate amount of blood seen in vaginal vault, few small blood clots present

What do you want to do next?

Next steps...

- Pregnancy test = urine hCG is negative
- Hgb/Hct = 10.2 g/dL and 31.6 g/dL
- Negative EMB
- Pelvic US shows a medium-sized submucosal fibroid.

Consult OBGYN for a myomectomy

...AND...

- A. LNG-IUS (Mirena)
- B. IV Estrogen
- C. Estrogen-Progestin oral contraception
- D. Nothing – follow up in 2 weeks.



C. Estrogen-Progestin pills

COC pills – need to manage bleeding now and better choice as patient is planning on conceiving again in the near future

CASE PRESENTATION #2

- A 47 year old African American, G2P2002, female presents to your office with a 4 day history of heavy menstrual bleeding. Denies any dysmenorrhea but states that her menstrual cycles have been increasing irregular over the past couple of years, with bleeding between periods. Sexually active with husband and using barrier method.
- Last pelvic and PAP was 5 years ago.
- Past medical history = Hypertension managed on lisinopril. Nonsmoker.
- Vitals = Afebrile, BP 138/74, HR 80, BMI 32.5
- Physical Exam = WNL, unremarkable
- Pelvic Exam = WNL, no tenderness, nodularities, or abnormal uterine size. Cervix normal with small amount of blood at the os.

What do you want to do next?

Next steps...

- Pregnancy test = urine hCG is negative
- PAP smear = negative
- CBC within normal limits

Which of the following is the most appropriate next steps in management of this patient?

- A. Pelvic ultrasound
- B. Endometrial biopsy
- C. Draw serum FSH/LH levels
- D. Estrogen-Progestin oral contraceptives



B. Endometrial Biopsy

Need to rule out endometrial cancer in patients older than 45 with AUB first. If negative, may proceed to a pelvic US

CASE PRESENTATION #3

- A 17-year-old Caucasian, GoPo, female presents to your office with a 7-month history of irregular heavy menstrual bleeding. Reports having regular menstrual cycles every 30 days at age 15 and would bleed for about 5 days. No history of contraception and not currently sexually active.
- Denies any pelvic injury/trauma.
- Past medical history = No comorbidities. Nonsmoker. Had an emergency appendectomy at age 13.
- Vitals = Afebrile, BP 106/74, HR 66, BMI 22
- Physical Exam = WNL, unremarkable

What do you want to do next?

Next steps...

- Would you do a pelvic exam?
- Would you do a pregnancy test?
- What about a menstrual calendar?
- Labs were all WNL.

Menstrual Calendar

- Frequency = cycle every 20 days
- Duration = 7 days
- Volume = +100mL of blood loss (avg 2 super tampons/day)

Which of the following is the most appropriate next steps in management of this patient?

- A. Pelvic ultrasound
- B. Discuss contraception/menstrual management
- C. Referral to endocrinologist
- D. Tranexamic acid



B. Discuss contraception/menstrual management

No need for invasive testing or referral at this time. Most likely irregular bleeding secondary to previous abdominal/pelvic surgery.

CASE PRESENTATION #4

- A 25-year-old Latin, G1P0010, female presents to your office with a 4-month history of amenorrhea. Reports having regular menstrual cycles every up until about one year ago when her menstrual cycles started to become lighter and more infrequent. Had a spontaneous abortion 2 years ago. No history of recent contraception use and not currently sexually active. She is very active and a marathon runner.
- Denies any pelvic injury/trauma.
- Past medical history = No comorbidities. Social smoker only.
- Vitals = Afebrile, BP 96/50, HR 54, BMI 18
- Physical Exam = WNL, unremarkable
- Pelvic Exam = High-tone pelvic floor, mild vaginal atrophy, no active bleeding

What do you want to do next?

Next steps...

- Pregnancy test = urine hCG is negative
- PAP smear = negative
- Labs within normal limits
- Diagnosis of secondary amenorrhea.

Which of the following is the most appropriate next steps in management of this patient?

- A. Pelvic ultrasound
- B. Endometrial biopsy
- C. Head MRI
- D. Contraception options



D. Contraception options

Secondary amenorrhea common for aggressive athletes. Her BMI is low and body weight is 10% less than normal interrupting ovulation. Discuss goals and future fertility options.

TIPS AND TRICKS FOR AUB

- Consider a menstrual calendar
- Primary vs. secondary
- Break your diagnosis into ovulation disorders and bleeding disorders
- Ruled out other causes, consider LARC/contraception management
- Don't forget about outside GYN causes
- Perform a pelvic exam, especially if active bleeding.
- Pregnancy test for ALL!
- Make your own algorithm
- Send a referral when necessary.

REFERENCES

- Kaunitz A. Approach to abnormal uterine bleeding in nonpregnant reproductive-age women. *UptoDate*. November 2018. <https://www.uptodate.com/contents/approach-to-abnormal-uterine-bleeding-in-nonpregnant-reproductive-age-women>. Accessed 11 December 2018.
- Dueholm, M., & Hjorth, I. M. (2017). Structured imaging technique in the gynecologic office for the diagnosis of abnormal uterine bleeding. *Best Practice & Research Clinical Obstetrics & Gynaecology*, 40, 23-43.
- Clark, T. J., & Stevenson, H. (2017). Endometrial Polyps and Abnormal Uterine Bleeding (AUB-P): What is the relationship, how are they diagnosed and how are they treated? *Best Practice & Research Clinical Obstetrics & Gynaecology*, 40, 89-104.
- Critchley, H. O., & Whitaker, L. (2017). Abnormal uterine bleeding (the old dysfunctional uterine bleeding): How to manage? *The Endometrial Factor*, 177-189.
- Reed, S and Urban, R. Management of endometrial hyperplasia. *UptoDate*. November 2018. <https://www.uptodate.com/contents/management-of-endometrial-hyperplasia>. Accessed 9 December 2018.
- Munro, M., Critchley, H., & Fraser, I. (2016). Research and clinical management for women with abnormal uterine bleeding in the reproductive years: More than PALM-COEIN. *BJOG: An International Journal of Obstetrics & Gynaecology*, 124(2), 185-189.

THANK YOU!

QUESTIONS???

Aleece Fosnight, MSPAS, PA-C, CSC, CSE

Urology, Women's Health, Sexual Medicine

GAPA Conference 2020

aleece.fosnight@gmail.com